

# Late spontaneous rupture of the extensor pollicis longus tendon after corticosteroid injection for flexor tenosynovitis

E. CIGNA<sup>1,2</sup>, Ö. ÖZKAN<sup>2</sup>, S. MARDINI<sup>2</sup>, P.-T. CHIANG<sup>2</sup>,  
C.-H. YANG<sup>3</sup>, H.-C. CHEN<sup>2</sup>

<sup>1</sup>Department of Plastic Surgery, "Sapienza" University of Rome, Rome, Italy

<sup>2</sup>Department of Plastic Surgery, <sup>3</sup>Department of Pathology and Laboratory Medicine, E-Da Hospital/I-Shou University, Taiwan

**Abstract.** – **INTRODUCTION:** Spontaneous rupture of the extensor pollicis longus (EPL) tendon has been reported after trauma, rheumatoid arthritis and sports. Rupture may also occur as a consequence of the use of anabolic steroids for recreational purposes, or systemic steroids for the treatment of a variety of medical conditions.

**CASE REPORT:** We present a case report of a woman affected with a spontaneous EPL tendon rupture resulted 14 months after a corticosteroid injection for flexor tenosynovitis, "trigger finger," of the thumb. The edges of the tendon were debrided and sutured using figure of eight stitch and a running locked stitch. In addition multiple specimens were sent to Pathology.

**DISCUSSION:** Duplay in 1876 described spontaneous rupture as a problem of mechanical and pressure phenomena. Another cause of EPL rupture is related to the development and persistence of inflammatory processes seen in patients with medical illnesses such as rheumatoid arthritis.

There have been no reports in the literature to date of spontaneous EPL tendon rupture in the late period after steroid injection. Tendon ruptures in the hand usually occur one or two weeks after a corticosteroid injection, and the affected tendons are usually in neighbouring areas.

*Key Words:*

Extensor pollicis longus, Tendon rupture, Spontaneous rupture, Corticosteroid injection, Tenosynovitis.

## Introduction

Spontaneous rupture of the extensor pollicis longus (EPL) has been described in patients following traumatic injuries, sports and non-sports

related, and in patients with medical conditions such as rheumatoid arthritis<sup>1-7</sup>. Rupture may also occur as a consequence of the use of anabolic steroids for recreational purposes, or systemic steroids for the treatment of a variety of medical conditions<sup>8-10</sup>. Few cases of EPL rupture at the wrist level have been reported after local injection of corticosteroids<sup>9,11,12</sup>. When tendon ruptures occur in association with local steroid injections, they usually occur one or two weeks after the injection, and the affected tendons are usually in close proximity to the site of injection.

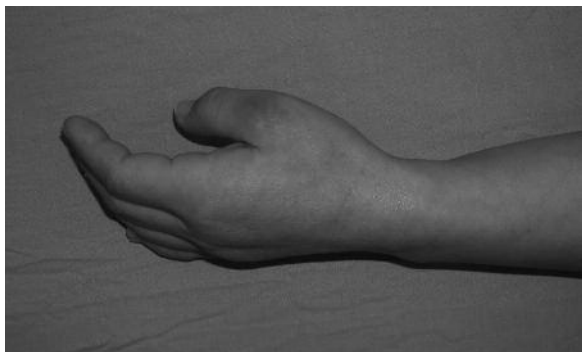In this report, the Authors describe a case of a ruptured EPL tendon, 14 months after a single session of corticosteroids injection for the treatment of right thumb flexor tenosynovitis ("trigger finger"), without a preceding traumatic event. Interestingly, the injection was performed for the treatment of trigger finger of the thumb, a problem that is addressed through the common used volar approach without injection through, or directly around, the EPL tendon. Details of the case, the potential mechanism leading to pathogenesis and rupture, as well as the treatment are described herein.

## Case Report

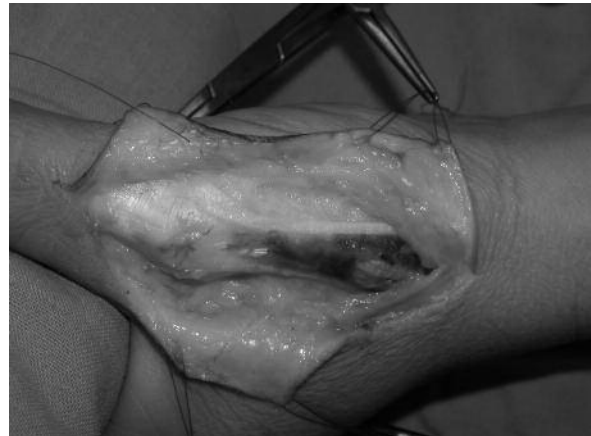A 49 years-old woman with no significant medical problems was seen in our Clinic for an inability to extend the thumb of her right, dominant hand. She reported that the day before, while putting on her kitchen gloves, she felt a sudden onset of pain, localised at the metacarpal phalangeal (MP) joint, which lasted a few seconds only. This was followed by an inability to extend the thumb. The patient denied any previous trauma or other risk factors that could have been related to the EPL rupture. Upon further questioning, the patient reported that one year

prior to this event, she had been treated for “trigger finger” of the thumb. The treatment consisted of injection of steroids which is usually a 1-1.5 ml dose of 1 ml of lidocaine with 0.5 ml of triamcinolone acetonide 40 mg/mL. Clinical examination of the hand and wrist did not display any evidence of bruising or lacerations. The metacarpophalangeal joint was in a flexed position (Figure 1). Palpation revealed tenderness localised to an area in the metacarpal bone approximately one centimeter (cm) proximal to the MP joint. The patient was unable to actively extend the thumb at the MP joint, or the distal phalanx at the interphalangeal joint. Upon passive hyperextension, the EPL tendon, which is normally visible and palpable, could not be visualized or palpated. The rest of the physical examination was within normal limits. X-ray examination of the hand did not show any bone or joint abnormality that could be related to the tendon rupture. Intraoperatively, the EPL tendon was found to be disrupted 1 cm proximal to the MP joint. There was no evidence of inflammation. Through the synovium which was intact, the proximal and distal stump of the extensor tendon were visualized (Figure 2). Grossly, there appeared to be significant attenuation and degeneration of the tendon. The edges of the tendon were debrided and sutured using figure of eight stitches of 3-0 nylon followed by a running locked 5-0 nylon stitch. Multiple specimens were sent to Pathology. A plaster cast was applied with the thumb in moderate extension.

Histological examination of the specimens showed disrupted collagen bundles and areas of necrosis in the stumps of the tendon. (Figure 3). Polarised light showed diffused pale foreign bodies consistent with steroid related debris. After splint removal, passive then active range of mo-



**Figure 1.** Preoperative view: the patient was unable to extend the thumb.

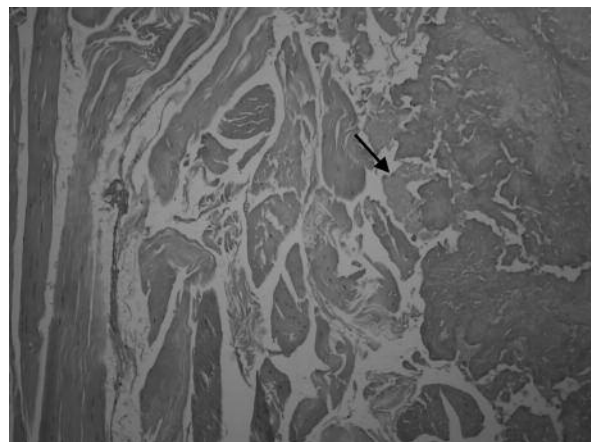


**Figure 2.** Intraoperative view: The proximal and distal ends of the EPL tendon are visualized. Note the degenerative appearance of the tendon.

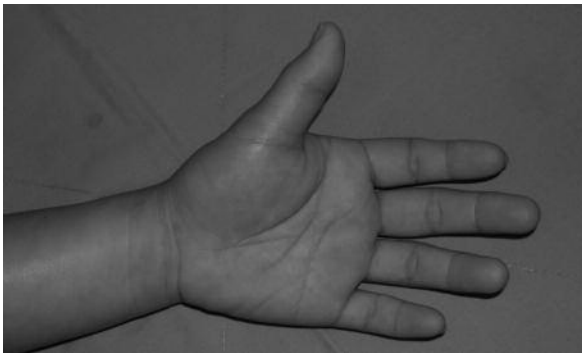
tion exercises were started and at three months the patient regained full range of motion and normal grip strength (Figure 4).

## Discussion

Spontaneous ruptures of the extensor pollicis longus tendon have been reported extensively in the literature. First described by Duplay in 1876, this problem often occurs after Colles' fracture as a result of a mechanical and a pressure phenomena<sup>13-14</sup>. Another cause of EPL rupture is related to the development and persistence of inflammatory processes seen in patients with medical illnesses such as rheumatoid arthritis. The rupture can oc-



**Figure 3.** Histologic examination of the specimens (Hematoxylin and Eosin stain 100X) showing tendon fibers with fibrinoid degeneration (arrow).



**Figure 4.** Postoperative view: after three months, the patient regained full range of motion of the thumb along with normal strength.

cur as a result of the inflammation related to the disease process, or as a result of the treatment of this disease using corticosteroids<sup>9</sup>.

Although not as common, rupture of the extensor pollicis longus has been reported in association with local steroid injections<sup>15</sup>. In one case, several injections to the wrist of a tennis player caused rupture of the EPL at the level of the injection a week after the treatment. The patient reported no history of trauma related to the rupture<sup>9</sup>. Several other Authors have described ruptures caused by local steroid injections. All injections were performed in the dorsal aspect of the wrist<sup>9,11-12</sup>.

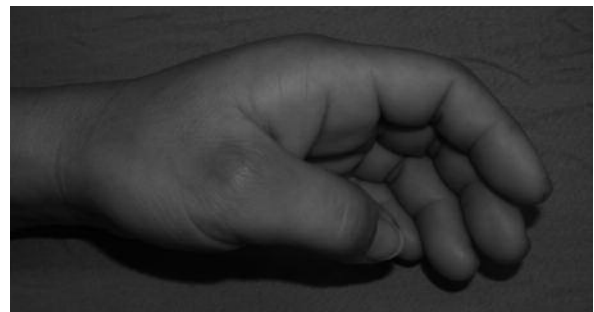Spontaneous rupture of the EPL tendon without a history of trauma, inflammatory diseases or overuse of the thumb is rare. In the case presented herein, a single steroid injection was administered 14 months before the rupture, and there was no evidence of any clinical or subclinical signs of an autoimmune disease or of a traumatic event that could induce such a rupture. All tests at our Institution for the presence of autoimmune disease were exhausted without any evidence of the presence of disease.

Interestingly, the injection was performed for flexor tenosynovitis through the usual palmar approach used for the treatment of trigger finger. The literature indicates that if corticosteroid injections are administered within the tendon tissue, they may have adverse effects on the tendon fibers causing tendon degeneration by altering collagen synthesis or strength<sup>16</sup>. There have been no reports in the literature to date of spontaneous EPL tendon rupture in the late period after steroid injection. Tendon ruptures in the hand usually occur one or two weeks after a corticosteroid injection, and the affected tendons are usually in neighbouring areas.

In our case, the injection itself had been administered to resolve the trigger finger in an area not directly related to the injection. Although injection of corticosteroids is relatively safe and widely used with some degree of success for treating tenosynovitis, it should be administered with adequate precautions<sup>17</sup>. In the case presented the corticosteroids were probably injected in several layers before reaching the appropriate intrasynovial layer. Although the patients' symptoms of "trigger finger" resolved following the injection, we speculate that the injection was administered in different layers probably causing a spread of the corticosteroid into the dorsal aspect of the hand, therefore, affecting the extensor tendon of the thumb (Figure 5). At the rupture level the actual distance between the flexor pollicis longus (the target of the injection) and the extensor pollicis longus is approximately 2 cm or less. Anatomically, the flexor tendon has a proper tendon sheath while the extensor tendon does not.

## Conclusions

In the absence of a clear etiology for rupture of the extensor pollicis longus in this patient, the proximity and temporal relationship of steroid injections into the palmar aspect of the thumb could create a potential explanation for this rare phenomenon. We are reminded that although steroid injections for treatment of flexor tenosynovitis may be a relatively benign event, improper administration could lead to serious consequences such as complete rupture that could require a surgical procedure followed by an inability to use the hand during the period of immobilization and physical rehabilitation.



**Figure 5.** A picture of a hand, showing the usual site of injection. Note the close proximity of the flexor pollicis longus tendon to the extensor pollicis longus tendon. FPL (flexor pollicis longus), EPL (extensor pollicis longus), epb (extensor pollicis brevis).

## References

- 1) MANNERFELT L, OETKER R, OSTLUND B, ELBERT. Rupture of the extensor pollicis longus tendon after Colles fracture and by rheumatoid arthritis. *J Hand Surg* 1990; 15: 49-50.
- 2) CASSELL OC, VIDAL P. An unreported cause of rupture of the extensor pollicis longus tendon. *J Hand Surg [Br]* 1996; 21: 640-641.
- 3) MOORE JR, WEILAND AJ, VALDATA L. Tendon ruptures in the rheumatoid hand: analysis of treatment and functional results in 60 patients. *J Hand Surg* 1987; 12: 9-14.
- 4) STRAUB LR, WILSON EH. Spontaneous rupture of extensor tendons in the hand associated with rheumatoid arthritis. *J Bone Joint Surg Am* 1956; 38: 1208-1217.
- 5) LLOYD TW, TYLER MP, ROBERTS AH. Spontaneous rupture of extensor pollicis longus tendon in a kick boxer. *Br J Sports Med* 1998; 32: 178-179.
- 6) GELB RI. Tendon transfer for rupture of the extensor pollicis longus. *Hand Clin* 1995; 11: 411-422.
- 7) DAWSON WJ. Sports-induced spontaneous rupture of the extensor pollicis longus tendon. *J Hand Surg* 1992; 17: 457-458.
- 8) KRAMHOFT M, SOLGAARD S. Spontaneous rupture of the extensor pollicis longus tendon after anabolic steroids. *J Hand Surg* 1986; 11: 87.
- 9) BJORKMAN A, JORGSHOLM P. Rupture of the extensor pollicis longus tendon: a study of aetiological factors. *Scand J Plast Reconstr Surg Hand Surg* 2004; 38: 32-35.
- 10) BONATZ E, KRAMER TD, MASEAR VR. Rupture of extensor pollicis longus. *Am J Orthop* 1996; 25: 118-122.
- 11) GOTTLIEB NL, RISKIN WG. Complications of local corticosteroid injections. *JAMA* 1980; 243: 1547-1548.
- 12) SMITH AJ, KOSYGAN K, NEWMAN RJ. *Br J Sports Med* 1999; 33: 423-425.
- 13) DUPLAY S. Rupture souscutanee du tendon du long extenseur du ponce. *Bull Mem Soc Chir Paris* 1876; 2: 788.
- 14) SADR B. Sequential rupture of extensor tendon after Colles fracture. *J Hand Surg* 1984; 9: 144-145.
- 15) MAHLER F, FRITSCHY D. Partial and complete ruptures of the Achilles tendon and local corticosteroid injections. *Br J Sports Med* 1992; 26: 7-14.
- 16) FREDBERG U. Local corticosteroid injection in sport: review of literature and guidelines for treatment. *Scand J Med Sci Sport* 1997; 7: 131-139.
- 17) KUMAR N, NEWMAN RJ. Complications of intra- and peri-articular steroid injections. *Br J Gen Pract* 1999; 49: 465-466.