

A study of multiple *Felis catus* Papillomavirus types (FcaPV-1, 2, 3, 4) in cat skin lesion in Italy by q-PCR

Journal:	<i>Journal of Feline Medicine and Surgery</i>
Manuscript ID	JFMS-17-0031.R2
Manuscript Type:	Original Article
Date Submitted by the Author:	n/a
Complete List of Authors:	<p>Mazzei, Maurizio; University of Pisa , Department of Veterinary Science Forzan, Mario; University of Pisa, Department of Veterinary Science Carlucci, Vito; University of Pisa, Department of Veterinary Science Anfossi, Antonio; Università degli Studi di Sassari, Dipartimento di Medicina Veterinaria Alberti, Alberto; Università degli Studi di Sassari Dipartimento di Medicina Veterinaria Albanese, Francesco; Private veterinary laboratory "LaVallonea" Binanti, Diana; Private veterinary laboratory AbLab Millanta, Francesca; University of Pisa, Department of Veterinary Science Baroncini, Lisa; University of Pisa, Department of Veterinary Science Pirone, Andrea; University of Pisa, Department of Veterinary Science Abramo, Francesca; University of Pisa, Department of Veterinary Science</p>
Keywords:	feline, papillomavirus, skin, viral plaque, in situ Bowenoid carcinoma, squamous cell carcinoma, actinic keratosis, q-PCR
Abstract:	<p>Abstract Objective: Aim of the study is to investigate by q-PCR the presence of Papillomavirus in feline viral plaques (VP), Bowenoid in situ carcinoma (BISC), squamous cell carcinoma (SCC), and actinic keratosis (AK). Methods: Twenty-nine cases with previously established diagnosis of feline VP, BISC, invasive SCC, and AK were selected from a dermatopathological database. A critical re-evaluation of diagnosis was performed by defining clear criteria toward carcinomatous vs non carcinomatous, in situ vs invasive (if carcinomatous) and viral vs actinic. Cases were evaluated for p16 immunolocalisation. The presence of the target viral genes for FcaPV-1, 2, 3 and 4 was determined by q-PCR. Data generated Cq values, which represent a normalized measure of DNA viral quantity. Samples with a positive Cq values were submitted to sequence analysis. Results: 4 VPs, 19 BISCs 4 SCCs and 1 AK were included. By Cq analysis we found that all VPs were positive for FcaPV-1 or FcaPV-2; and 8 BISCs for FcaPV-1, 2, 4. FcaPV-2 was the most prevalent among the group of VPs and BISCs. Conclusion and relevance: Using Cq method we report the first evidence of FcaPV-1, 2 and 4 in Italy, FcaPV-2 was the most frequently detected. To a lesser extent also FcaPV-1 and FcaPV-4 has been detected in our examined samples while FcaPV-3 was never associated to viral induced lesions by Cq investigation. Compared to conventional PCR the Cq method has the advantage to establish a possible role of the virus in the outcome of infection.</p>



SCHOLARONE™
Manuscripts

For Peer Review

1 **A study of multiple *Felis catus* Papillomavirus types (FcaPV-1, 2, 3, 4) in**
2 **cat skin lesion in Italy by q-PCR.**

3

4 Mazzei M.^{*}, Forzan M.^{*}, Carlucci V.^{*}, Anfossi A.G.[§], Alberti A.[§], Albanese F.[°],
5 Binanti D.[^], Millanta F.^{*}, Baroncini L.^{*}, Pirone A.^{*}, Abramo F.^{*}

6 ^{*} *Department of Veterinary Sciences, University of Pisa, Viale delle Piagge 2, 56124 Pisa,*
7 *Italy;*

8 [§] *Department of Veterinary Medicine, University of Sassari, via Vienna 2, 07100 Sassari,*
9 *Italy;*

10 [°] *Private Veterinary Laboratory "LaVallonea", via G. Verdi 39, 73031 Alessano (LE), Italy;*

11 [^] *Private Veterinary Laboratory "AbLab", via Privata Massa Neri 13, 19038 Sarzana (SP),*
12 *Italy.*

13

14 **Corresponding author:** Francesca Abramo, associate professor.

15 Department of Veterinary Sciences, University of Pisa, Viale delle Piagge 2, 56124 Pisa, Italy

16 Phone number +39 0502216988 – Mobile +39 3287119710; e-mail: francesca.abramo@unipi.it

17

18 **Key words:** feline papillomavirus, skin, viral plaque, *in situ* Bowenoid
19 carcinoma, squamous cell carcinoma, actinic keratosis, q-PCR

20 **Abstract**

21 **Objective:** Aim of the study is to investigate by q-PCR the presence of
22 Papillomavirus in feline viral plaques (VP), Bowenoid *in situ* carcinoma (BISC),
23 squamous cell carcinoma (SCC), and actinic keratosis (AK).

24 **Methods:** Twenty-nine cases with previously established diagnosis of feline VP,
25 BISC, invasive SCC, and AK were selected from a dermatopathological
26 database. A critical re-evaluation of diagnosis was performed by defining clear
27 criteria toward carcinomatous vs non carcinomatous, *in situ* vs invasive (if
28 carcinomatous) and viral vs actinic. Cases were evaluated for p16
29 immunolocalisation. The presence of the target viral genes for FcaPV-1, 2, 3
30 and 4 was determined by q-PCR. Data generated $\Delta\Delta Cq$ values, which
31 represent a normalized measure of DNA viral quantity. Samples with a positive
32 $\Delta\Delta Cq$ values were submitted to sequence analysis.

33 **Results:** 4 VPs, 19 BISCs 4 SCCs and 1 AK were included. By $\Delta\Delta Cq$ analysis
34 we found that all VPs were positive for FcaPV-1 or FcaPV-2; and 8 BISCs for
35 FcaPV-1, 2, 4. FcaPV-2 was the most prevalent among the group of VPs and
36 BISCs.

37 **Conclusion and relevance:** Using $\Delta\Delta Cq$ method we report the first evidence of
38 FcaPV-1, 2 and 4 in Italy, FcaPV-2 was the most frequently detected. To a
39 lesser extent also FcaPV-1 and FcaPV-4 has been detected in our examined
40 samples while FcaPV-3 was never associated to viral induced lesions by $\Delta\Delta Cq$
41 investigation. Compared to conventional PCR the $\Delta\Delta Cq$ method has the
42 advantage to establish a possible role of the virus in the outcome of infection.

43

44 Introduction

45 Detection of Feline papillomaviruses (FcaPVs) from feline cutaneous
46 lesions has been reported worldwide^{1,2} and these viruses are considered liable
47 of causing several feline skin conditions.¹⁻⁵ These include a wide spectrum of
48 proliferative skin lesions ranging from non-neoplastic viral plaques (VP) to pre-
49 neoplastic Bowenoid *in situ* carcinoma (BISC), and invasive squamous cell
50 carcinoma (SSC).⁶ A progression from non neoplastic viral induced lesions to
51 overt neoplasia has also been documented to occur.⁷ Four FcaPV types
52 (FcaPV-1 to FcaPV-4) have been so far described in cats, having different
53 anatomical distribution and presentation.^{1,8-11} The most frequent FcaPV
54 (FcaPV-2, belonging to *Dyothetapapillomavirus* genus) was isolated from a
55 cutaneous pigmented plaque,¹² and later related to cutaneous SCC.¹³⁻¹⁵
56 FcaPV-2 seems to play a role in a high proportion of nasal planum squamous
57 cell carcinomas and, animals with tumours associated to papillomaviral
58 aetiology with p16 upregulation, show increased survival compared with those
59 attributable to UV radiation.¹⁶ The relevance of FcaPV-2 in the pathogenesis of
60 both premalignant and malignant lesions has been recently investigated by
61 concurrently assessing number of DNA viral copies and viral gene expression.⁵⁻
62 ⁷ However, the effective role of FcaPV-2 in the development of malignant
63 lesions is still a debated question, especially in view of recent results indicating

64 a high FcaPV-2 prevalence in healthy domestic cats.^{7,17} The role of other feline
65 PV types, namely FcaPV-1, 3, and 4, remains obscure. FcaPV-1, belongs to the
66 *Lambdapapillomavirus* genus and has been rescued from a hyperkeratotic
67 cutaneous lesion in a Persian cat by Tachezy et al.⁹ In the same year another
68 FcaPV was also identified in a shorthair domestic cat with papillomatosis.¹¹
69 More recently the virus was detected in multiple small sessile raised lesions on
70 the ventral surface of the tongue in two 13-year-old domestic cats.¹⁸ FcaPV-3 is
71 a *Taupapillomavirus*, isolated for the first time from a cutaneous in situ
72 carcinoma.³ Recently FcaPV-3 has been detected from a BISC with a novel
73 histological feature and a benign clinical behaviour.¹⁹ The same
74 histopathological changes were observed in a feline basal cell carcinoma, from
75 which DNA sequences of a novel PV closely related to FcaPV-3 were detected
76 by the authors.⁴ FcaPV-4 belongs to genus *Taupapillomavirus*, and has been
77 detected in oral cavity following a severe gengivitis.¹⁰ Pathogenicity of FcaPV-1
78 and FcaPV-4 is still unclear and these viruses are rarely detected in oral
79 inflammatory as well as neoplastic lesions. Therefore, an active role of FcaPV-1
80 and FcaPV-4 in carcinogenesis is still debated.

81 Based on literature, it emerges that most cases of FcaPVs infection have been
82 documented in domestic felids from New Zealand, North and South America
83 and, to a lesser extent from Europe. This might just reflect the active research

84 done in these countries without any epidemiological meaning. In Europe PVs
85 infections have been reported in Switzerland in nine cases,^{12,20} in one case in
86 Germany²¹ and in one case in Italy.²² Here we assess by a combination of
87 histology, immunohistochemistry and q-PCR the concurrent presence of
88 FcaPV-1, 2, 3 and 4 viral DNA and p16 immunostaining in 29 feline lesions
89 collected in Italy including non neoplastic and preneoplastic, viral and non viral
90 induced skin lesions namely: VP, BISC, invasive SSC and actinic keratosis
91 (AK). Two methods were applied to analyse the viral load data: absolute
92 quantification (AQ) and relative quantification (RQ). The AQ was applied to
93 determine the viral copy number per μg of DNA; however, by this method wide
94 range of values can be obtained without a cut-off value that would allow to
95 discriminate FcaPVs presence as innocent bystander or as responsible of viral
96 lesion. To address this problem we approached the RQ by $\Delta\Delta\text{Cq}$ calculation.²³
97 This method measures viral genome presence by relating the obtained values
98 of each of the 4 FcaPVs in each lesion classified as VP or BISC to those of
99 SCC and AK.

100 **Materials and methods**

101 *Biopsies*

102 Feline skin biopsies have been identified from dermatopathological databases

103 and 29 cases with a diagnosis of VP, BISC, invasive SCC and AK were
104 selected. The retrieved formalin fixed cases were routinely processed for
105 histopathology and 4 µm thick paraffin embedded tissues sections were stained
106 with haematoxylin and eosin (HE). Before inclusion in the study, the selected
107 samples were subjected to critical re-evaluation of diagnosis by defining clear
108 distinctive criteria, such as carcinomatous vs non carcinomatous, in situ vs
109 invasive (if carcinomatous), and viral vs actinic. The established criteria were
110 defined as described in the scientific literature and are summarized in table
111 1.^{14,20,24} Data from signalment and lesion distribution, when available, were
112 included.

113 *P16 immunohistochemistry*

114 Cases were evaluated for the detection of p16 by immunohistochemistry
115 employing an ABC system (Vector Laboratories, Burlingame, USA). Antigen
116 unmasking was carried out at 120°C for 3 min in a pressure cooker with a TRIS-
117 EDTA buffer (1,2 g/L Tris, 0,36 g/L EDTA, pH 9.0). Sections were pre-treated
118 for 10 min with 1% H₂O₂ in 0.1 M phosphate buffered saline (PBS), pH 7.4 to
119 quench endogenous peroxidase activity, and blocked for 30 min at room
120 temperature (rt) in PBS with a 2% normal horse serum (PK-7200, Vector
121 Laboratories, Burlingame, USA) and 0.05% TritonX-100. Sections were then
122 incubated overnight at 4°C with a 1:100 diluted monoclonal primary antibody

123 p16-INK4a (mouse monoclonal IgG, BiorByt, San Francisco, USA). After
124 washing in PBS, an incubation with a secondary universal biotinylated anti-
125 mouse/rabbit antibody (PK-7200, Vector Laboratories, Burlingame, USA) was
126 performed for 1h at rt. Staining was visualized with a diaminobenzidine (SK-
127 4105, Vector Laboratories, Burlingame, USA) solution under a light microscope
128 (Eclipse 80i, Nikon Tokyo, Japan).

129 *Sampling material for q-PCR*

130 Three 10 µm thick sections from the selected samples were cut with a
131 microtome, place onto slides and left unfixed. These slides were observed
132 under an optic microscope. Tissue that was not relevant for the study was
133 scraped off and the remaining tissue directly collected in a DNase free 1,5 ml
134 tube. To prevent carryover of contaminating DNA the microtome overlay was
135 covered with a new piece of adhesive tape and a new blade was used for each
136 sample.

137 *DNA extraction*

138 DNA extraction was performed using DNeasy Blood and Tissue kit (Qiagen,
139 Hilden, Germany) following manufacturer's instruction and applying a
140 preliminary removal of paraffin by extraction with xylene. DNAs were eluted in
141 30 µl, and each sample concentration was quantified using the Qubit

142 spectrophotometer (ThermoFisher Scientific, Waltham, USA), DNA samples
143 were stored at -20°C until analysis.

144 *q-PCR*

145 The extracted DNAs were amplified using four specific set of primers amplifying
146 a portion of the four types of FcaPVs L1 gene so far identified in the feline
147 species (Table 2). To normalize the amount of DNA used for each sample so to
148 achieve a correct quantification of viral copy number, a q-PCR under the same
149 condition as for FcaPV but with a specific set of primers was run in parallel for
150 the reference gene albumin (ALB).²⁵ The number of copy of the target viral
151 gene, measured as Cq value, generates a ΔCq value when compared to the
152 corresponding Cq value of the reference gene. Moreover, a $\Delta\Delta Cq$ value was
153 calculated comparing the ΔCq value of the sample of interest to the mean ΔCq
154 value obtained from the SCC and AK group, considered as the negative control
155 group. The $\Delta\Delta Cq$ value represents a normalized measure of DNA viral quantity
156 and was calculated using REST software.²⁶ In this work, a RQ using the $2^{-\Delta\Delta Cq}$
157 method²³ was adapted to estimate in each sample the fold change of FcaPV-1,
158 2, 3 and 4 target viral gene copies relative to the albumin reference gene.
159 Melting curve analysis was performed in conjunction with each four specific
160 FcaPV amplification protocol to determine if non specific products were

161 amplified during reaction. The specificity of the melting curve was compared to
162 melting curves values obtained from a plasmid (pFcaPV) containing amplicon of
163 the four FcaPVs spanning the real-time products. The plasmid was generated
164 by inserting the four FcaPVs gene segments into pMA-T vector using GeneArt
165 technology (Thermo Fisher Scientific, Waltham, USA). Serial dilutions of
166 pFcaPV plasmid ranging from 10^6 to 10^2 copies/5 μ l were used to calculate the
167 efficiency of q-PCR for each FcaPV set of primers and compared to the
168 efficiency calculated on five points of a 2-fold serial dilution of a quantified DNA
169 template for ALB gene. The efficiency of each q-PCR assay was similar and
170 ranging from 91% to 98% (average 94,6%). The lesions identified by
171 histological classification as SCC-AK were presumed to serve as the negative
172 control group and each sample belonging to this group was also individually
173 tested by $\Delta\Delta Cq$ analysis for each FcaPV type. Samples that had eventually
174 scored a positive $\Delta\Delta Cq$ value were excluded. In addition, the viral copy
175 number/ μ l of input DNA for each FcaPV type in each sample tested was
176 calculated (AQ). The assays were performed in Rotorgene thermocycler
177 (Corbett Research, Sydney, Australia) using SSCO SYBR Green master mix
178 (Biorad, Hercules, USA) and 5 μ l of extracted DNA. All samples were tested in
179 duplicate and the results were calculated using the mean Cq values. Samples
180 positive for only one replica were considered as negative. All samples with a

181 positive $\Delta\Delta Cq$ values were submitted to sequence analysis (BMR genomics,
182 Padova, Italy).

183 **Results**

184 Histologically all VPs were recognized for areas of focal epidermal
185 dysplasia with koilocytes and keratinocytes with cytoplasm enlarged by blue-
186 greyish material. Regarding BISC diagnosis, the presence of koilocytes or
187 koilocyte-like cells pointed to the viral origin in 17/20 cases while in the
188 remaining 3 cases diagnosis was formulated by other morphological details
189 listed in Table 1. SCC and AK showed the morphological alterations listed in
190 Table 1. Among the 20 BISCs cases 5 VPs were also detected in the
191 adjacent skin by histology and in other 5, sites of penetration of keratinocytes
192 through the basement membrane into the dermis were observed indicative of
193 progression toward SCC.

194 Clinical reports for each of the 29 cases fulfilling the established
195 histological criteria were recorded. Breed, age, gender and anatomical
196 distribution are summarised in Table 3. Twenty-five subjects were shorthair
197 domestic cats, two persian and two main coons. Mean age at presentation
198 varied between 6 and 20 years (median 11,6), 14 out of 29 were female and
199 15 were male. A total of 4 VPs, 20 BISCs, 4 SCCs and 1 AK were detected.

200 Lesions were observed in densely haired skin regions in 9 cats (dorsum,
201 flank, and shoulder), in areas non-exposed to sunlight in 1 cat (groin) and in
202 hypotrichotic and solar exposed skin in 18 cats (ears, nose, eyelids, temporal
203 region). All cases of SCC were observed in sun-exposed areas. Clinically
204 VPs were few millimeters wide, alone or grouped, slightly raised, pigmented
205 and non-pruritic lesions; BISCs were clinically larger than VPs, usually more
206 than 1 cm of diameter, multifocally coalescing, raised and often verrucous,
207 crusted and hyperpigmented. In SCC, erosive and ulcerative crusted lesions
208 were clinically detected. In the only case in which AK was diagnosed,
209 erythema, scales and crust were seen (Figure 1a, b, c).

210 P16 was immunolocalized in all VPs epidermis and in the epidermis and
211 follicular wall of the BISCs. No signal or only faint staining was detected in
212 the SCC and AK lesion. Immunoreactivity was either nuclear and
213 cytoplasmic; in VPs and BISCs the signal was strong while in the SCCs
214 immunoreactivity was faint and therefore considered as no significant
215 (Figure 1d).

216 By q-PCR we were able to detect the albumin reference gene in 28 out of 29
217 DNA samples. Only one sample classified as BISC was not suitable to
218 molecular analysis and therefore it was excluded from further analysis.

219 By AQ, the presence of FcaPVs has been detected in low copies in almost all
220 cases (Table 4). By RQ ($\Delta\Delta Cq$ method) a reduced number of samples was
221 linked to viral lesions. In details, FcaPVs positive $\Delta\Delta Cq$ values were detected
222 in all VPs (4/4) and in 8/19 BISCs (Table 3). VPs were positive to FcaPV-2 in
223 three samples and to FcaPV-1 in one sample. BISCs were positive to FcaPV-
224 2 in three samples, FcaPV-4 and FcaPV-1 in one sample each. Interestingly,
225 as never reported before, in BISCs lesion we found three cases of double
226 infection. In two of those, FcaPV-1 and 2 were detected simultaneously and
227 in one case FcaPV-2 was present along with FcaPV-4 (Table 3).

228 In all cases with a positive $\Delta\Delta Cq$ value, the viral load was always greater
229 than 10^2 copies / μg DNA (FcaVP-1: min 167 – max 310 Standard Error (SE):
230 33,0; FcaPV-2: min 100 – max 1150 SE: 163,9; FcaPV-4 min 391 – max
231 3700 SE: 1654,5) (Table 4). Sequence analysis confirmed the FcaPV types
232 as indicated by q-PCR $\Delta\Delta Cq$ analysis.

233 **Discussion**

234 In this retrospective study, we detected the concurrent presence of different
235 types of PVs, namely of FcaPV-1, 2 and 4 in feline VPs and BISCs by $\Delta\Delta Cq$
236 method using specific primers. To the best of our knowledge only the
237 concurrent presence of FcaPV-2 and 3 have been reported from one BISC

238 and one VP.^{3,22} However differently from previous reports, here we report the
239 presence of FcaPV-1 and FcaPV-4, alone or in association to FcaPV-2.

240 A limitation when performing PCR-based studies on PVs infection is
241 that the viral DNA is often detected and cannot be directly linked to an
242 effective role of virus in pathogenesis and therefore it is not possible to fully
243 establish whether the presence of a viral genome is uneventful (subclinical
244 lesion). In particular, FcaPV-2 has been recently detected in a number of skin
245 swabs from healthy cats, making difficult to discern whether PVs are causing
246 cancer or are merely an “innocent bystander”.⁷ The hypothesis that the
247 presence of high viral loads likely represents an infectious state of PV is
248 supported by Thomson et al.⁷ who recently showed that the finding of high
249 copy numbers of FcaPV-2 DNA within a lesion suggests that the detected
250 virus may be responsible for it. In fact, while high viral copy numbers were
251 associated with E6/E7 gene expression, no gene expression was detected in
252 association of low copy numbers, an indication of an incidental finding.

253 For the above-mentioned reasons, for this study we used a q-PCR
254 protocol applying a $\Delta\Delta Cq$ method to investigate if and which FcaPVs have
255 induced the lesion in cats. In this sense the obtained results are partially in
256 line with the scientific literature which indicates so far that FcaPV-2 is the

257 major PV type implicated in skin preneoplastic and neoplastic lesions in
258 cats.⁷ Since the genome organization and the role of viral proteins within the
259 replication cycle are considered similar even between different genera
260 belonging to the *Papillomaviridae* family we assumed that a similar link is
261 maintained for feline PVs other than FcaPV-2. Importantly we reported
262 positive $\Delta\Delta Cq$ values for FcaPV-1 and 4; two FcaPV types rarely reported.^{9–}
263 ^{11,18}

264 A comparison between our data with those obtained from other studies
265 is difficult for two reasons: i) type of PCR primers used (specific vs
266 consensus); ii) type of PCR used (conventional vs quantitative). A general
267 prevalence ranging from 24 to 100% of FcaPV-2 both BISCs and VPs has
268 been reported.^{7,8,27,28} In our study, by using specific primers in a q-PCR
269 analysis applying RQ method, we obtained a prevalence for FcaPV-2 in
270 BISCs of 31,6% (6/19) and for all FcaPV types of 42,10% (8/19).

271 Failure to demonstrate PV DNA in every BISC have been previously explained
272 through a carcinogenesis model in which papillomaviruses cause transformation
273 but are only for a short period present within the lesion.²⁹ Surprisingly, cases in
274 which koilocytes were detected did not show any $\Delta\Delta Cq$ positive value; this
275 result is likely due to: i) the detection of koilocytes in very focal lesions that

276 could have been no more present when additional serial paraffin sections were
277 prepared for DNA extraction and PCR analysis; ii) the presence of a PCR
278 undetectable PV variant.

279 Low viral copies for all PV types have been detected in almost all cases,
280 however the $\Delta\Delta Cq$ analysis was necessary to associate the FcaPVs as
281 biological agent potentially causing the lesions. $\Delta\Delta Cq$ positive values for the
282 different PV types were detected in all VPs and in 42% of BISCs.
283 Noteworthy, mean $\Delta\Delta Cq$ of positive samples differed among PV types being
284 62.5, 189.1 and 3083.5 for FcaPV-1, FcaPV-2 and FcaPV-4 respectively.
285 Studies considering a larger panel of cases might be necessary to establish a
286 further $\Delta\Delta Cq$ cut off value.

287 Here we document the presence of FcaPV-2 with high prevalence in both
288 VPs and BISCs while we rescued FcaPV-1 and FcaPV-4 less frequently;
289 these last two PVs are rarely described as playing an active role in skin and
290 oral mucosa lesions in cats.^{9,10,18,30} None of the lesions was associated to
291 FcaPV-3 when adopting $\Delta\Delta Cq$ method, confirming the rare occurrence of this
292 FcaPV type also in Italy.

293 Either cytoplasmic or nuclear p16 signals were detected in all cases where
294 cytopathic effects were found (VP, BISC) while p16 immunolocalisation was

295 present with faint and mainly cytoplasmic signal in cases of SCCs and no p16-
296 immunoreactivity was found in the case of AK. Despite the difficulties of
297 interpretation when the signal was faint, these results are in line with what
298 already documented previously. About half of the SCC studied by Thomson et
299 al.⁷ were negative to p16 immunostaining. A strong association between
300 FcaPV-2 E6/E7 gene expression and p16 immunostaining have been recently
301 found in feline SCC with 18 of 20 (90%) E6/E7-positive SCCs being also
302 positive for p16 compared to 13 of 40 (33%) E6/E7-negative SCCs.⁷ E6/7 gene
303 expression investigation has not been carried out in our study but our results
304 might reflect this correlation.

305 **Conclusion**

306 $\Delta\Delta Cq$ analysis has proved to be necessary to associate the FcaPVs as
307 biological agent potentially causing the lesions. Based on this method the
308 presence of FcaPV-2 is confirmed to be the most representative FcaPV in
309 feline skin lesions referable to diagnosis of VP and BISC in Italy. To a lesser
310 extent also FcaPV-1 and FcaPV-4 has been detected in our examined
311 samples.

312

313 **Acknowledgement:** The authors thank all the colleagues who referred the
314 cases.

315 **Conflict of interest:** The authors declared no potential conflicts of interest with
316 respect to the research, authorship, and/or publication of this article

317 **Source of funding:** This study was financially supported by Fondi di Ateneo
318 University of Pisa.

319 **Bibliografy**

- 320 1. Sundberg JP, Van Ranst M, Montali R, et al. Feline papillomas and
321 papillomaviruses. *Vet Pathol* 2000; 37: 1–10.
- 322 2. Gil da Costa RM, Peleteiro MC, Pires MA, et al. An Update on Canine,
323 Feline and Bovine Papillomaviruses. *Transboundary and Emerging*
324 *Diseases*, 11 September 2016. Epub ahead of print 11 September 2016.
325 DOI: 10.1111/tbed.12555.
- 326 3. Munday JS, Dunowska M, Hills SF, et al. Genomic characterization of
327 *Felis catus* papillomavirus-3: a novel papillomavirus detected in a feline
328 Bowenoid in situ carcinoma. *Vet Microbiol* 2013; 165: 319–25.
- 329 4. Munday JS, French A, Thomson N. Detection of DNA sequences from a
330 novel papillomavirus in a feline basal cell carcinoma. *Vet Dermatol* 2017;
331 28: 236-e60.
- 332 5. Munday JS, Gwyther S, Thomson NA, et al. Bilateral pre-auricular
333 papillary squamous cell carcinomas associated with papillomavirus
334 infection in a domestic cat. *Vet Dermatol* 2017; 28: 232-e58.
- 335 6. Scott DW, Miller WH, Griffin CE, et al. *Muller & Kirk's Small Animal*
336 *Dermatology*. Epub ahead of print 2001. DOI: 10.1016/B978-0-7216-

- 337 7618-0.50002-X.
- 338 7. Thomson NA, Munday JS, Dittmer KE. Frequent detection of
339 transcriptionally active *Felis catus* papillomavirus 2 in feline cutaneous
340 squamous cell carcinomas. *J Gen Virol* 2016; 97: 1189–97.
- 341 8. Munday JS, Kiupel M, French AF, et al. Detection of papillomaviral
342 sequences in feline Bowenoid in situ carcinoma using consensus primers.
343 *Vet Dermatol* 2007; 18: 241–5.
- 344 9. Tachezy R, Duson G, Rector A, et al. Cloning and genomic
345 characterization of *Felis domesticus* papillomavirus type 1. *Virology* 2002;
346 301: 313–21.
- 347 10. Dunowska M, Munday JS, Laurie RE, et al. Genomic characterisation of
348 *Felis catus* papillomavirus 4, a novel papillomavirus detected in the oral
349 cavity of a domestic cat. *Virus Genes* 2014; 48: 111–119.
- 350 11. Terai M, Burk RD. *Felis domesticus* papillomavirus, isolated from a skin
351 lesion, is related to canine oral papillomavirus and contains a 1.3 kb non-
352 coding region between the E2 and L2 open reading frames. *J Gen Virol*
353 2002; 83: 2303–7.
- 354 12. Lange CE, Tobler K, Markau T, et al. Sequence and classification of
355 FdPV2, a papillomavirus isolated from feline Bowenoid in situ carcinomas.
356 *Vet Microbiol* 2009; 137: 60–65.
- 357 13. Ravens PA, Vogelnest LJ, Tong LJ, et al. Papillomavirus-associated
358 multicentric squamous cell carcinoma in situ in a cat: An unusually
359 extensive and progressive case with subsequent metastasis. *Vet*
360 *Dermatol* 2013; 24: 642-e162.
- 361 14. Munday JS. Papillomaviruses in felids. *Vet J* 2014; 199: 340–347.
- 362 15. Altamura G, Corteggio A, Pacini L, et al. Transforming properties of *Felis*
363 *catus* papillomavirus type 2 E6 and E7 putative oncogenes in vitro and
364 their transcriptional activity in feline squamous cell carcinoma in vivo.
365 *Virology* 2016; 496: 1–8.

- 366 16. Munday JS, Gibson I, French AF. Papillomaviral DNA and increased
367 p16CDKN2A protein are frequently present within feline cutaneous
368 squamous cell carcinomas in ultraviolet-protected skin. *Vet Dermatol*
369 2011; 22: 360–366.
- 370 17. Geisseler M, Lange CE, Favrot C, et al. Geno- and seroprevalence of
371 *Felis domesticus* Papillomavirus type 2 (FdPV2) in dermatologically
372 healthy cats. *BMC Vet Res* 2016; 12: 147.
- 373 18. Munday JS, Fairley RA, Mills H, et al. Oral Papillomas Associated With
374 *Felis catus* Papillomavirus Type 1 in 2 Domestic Cats. *Vet Pathol* 2015;
375 52: 1187–1190.
- 376 19. Munday JS, Fairley R, Atkinson K. The detection of *Felis catus*
377 papillomavirus 3 DNA in a feline bowenoid in situ carcinoma with novel
378 histologic features and benign clinical behavior. *J Vet Diagnostic Investig*
379 2016; 28: 612–615.
- 380 20. Wilhelm S, Degorce-Rubiales F, Godson D, et al. Clinical, histological and
381 immunohistochemical study of feline viral plaques and bowenoid in situ
382 carcinomas. *Vet Dermatol* 2006; 17: 424–431.
- 383 21. Egberink HF, Berrocal A, Bax HA, et al. Papillomavirus associated skin
384 lesions in a cat seropositive for feline immunodeficiency virus. *Vet*
385 *Microbiol* 1992; 31: 117–25.
- 386 22. Alberti A, Tore G, Scagliarini A, et al. Regressing Multiple Viral Plaques
387 and Skin Fragility Syndrome in a Cat Coinfected with FcaPV2 and
388 FcaPV3. *Case Reports Vet Med* 2015; 2015: 1–5.
- 389 23. Schmittgen TD, Livak KJ. Analyzing real-time PCR data by the
390 comparative C T method. 2008; 3: 1101–1108.
- 391 24. Levison DA, Parratt D. *Skin Diseases of the Dog and Cat*. Oxford, UK:
392 Blackwell Science Ltd. Epub ahead of print 20 July 2005. DOI:
393 10.1002/9780470752487.
- 394 25. Helfer-Hungerbuehler AK, Widmer S, Hofmann-Lehmann R. GAPDH
395 Pseudogenes and the Quantification of Feline Genomic DNA Equivalents.

- 396 Mol Biol Int 2013; 2013: 587680.
- 397 26. Pfaffl MW, Horgan GW, Dempfle L. Relative expression software tool
398 (REST) for group-wise comparison and statistical analysis of relative
399 expression results in real-time PCR. Nucleic Acids Res 2002; 30: e36.
- 400 27. Nespeca G, Grest P, Rosenkrantz WS, et al. Detection of novel
401 papillomaviruslike sequences in paraffin-embedded specimens of
402 invasive and in situ squamous cell carcinomas from cats. Am J Vet Res
403 2006; 67: 2036–2041.
- 404 28. Munday JS, Peters-Kennedy J. Consistent detection of *Felis domesticus*
405 papillomavirus 2 DNA sequences within feline viral plaques. J Vet Diagn
406 Invest 2010; 22: 946–9.
- 407 29. Smith KT, Campq MS. ‘Hit and run’ transformation of mouse C127 cells
408 by bovine papillomavirus type 4: the viral DNA is required for the initiation
409 but not for maintenance of the transformed phenotype. Virology 1988;
410 164: 39–47.
- 411 30. Munday JS, French AF, Gibson IR, et al. The presence of p16 CDKN2A
412 protein immunostaining within feline nasal planum squamous cell
413 carcinomas is associated with an increased survival time and the
414 presence of papillomaviral DNA. Vet Pathol 2013; 50: 269–73.

415

416

417 LEGEND

418 Figure 1. Multiple symmetrical raised, hyperpigmented and crusted plaques
419 on the face of a cat with Bowenoid in situ carcinoma (a). Histopathology from
420 a viral plaque in a cat. Focal epidermal hyperplasia, absence of follicular wall
421 involvement, evident viral cytopathic effects (koilocytes) (bar=50µm) (b);

422 Histopathology from a Bowenoid in situ carcinoma in a cat. Epidermal and
423 follicular dysplasia with upward in situ keratinocyte proliferation and a few
424 koilocytes (bar=50 μ m) (c); p16 immunohistochemistry, groups of
425 keratinocytes show nuclear and cytoplasmic positivity (ABC system, bar=100
426 μ m) (d).

427

For Peer Review

1 **Papillomavirus induced skin lesions in cats from Italy.**

2 **A study of multiple *Felis catus* Papillomavirus types (FcaPV-1, 2, 3, 4) in**
3 **cat skin lesion in Italy by q-PCR.**

4

5 Mazzei M.^{*}, Forzan M.^{*}, Carlucci V.^{*}, Anfossi A.G.[§], Alberti A.[§], Albanese F.[°],
6 Binanti D.[^], Millanta F.^{*}, Baroncini L.^{*}, Pirone A.^{*}, Abramo F.^{*}

7 ^{*} *Department of Veterinary Sciences, University of Pisa, viale delle Piagge 2, 56124 Pisa,*
8 *Italy;*

9 [§] *Department of Veterinary Medicine, University of Sassari, via Vienna 2, 07100 Sassari,*
10 *Italy;*

11 [°] *Private Veterinary Laboratory "LaVallonea", via G. Verdi 39, 73031 Alessano (LE), Italy;*

12 [^] *Private Veterinary Laboratory "AbLab", via Privata Massa Neri 13, 19038 Sarzana (SP),*
13 *Italy.*

14

15 **Corresponding author:** Francesca Abramo, associate professor.

16 Department of Veterinary Sciences, University of Pisa, Viale delle Piagge 2, 56124 Pisa, Italy

17 Phone number +39 0502216988 – Mobile +39 3287119710; e-mail: francesca.abramo@unipi.it

18

19 **Key words:** feline papillomavirus, skin, viral plaque, *in situ* Bowenoid
20 carcinoma, squamous cell carcinoma, actinic keratosis, q-PCR

21 **Abstract**

22 **Objective:** Aim of the study is to investigate by q-PCR the presence of **PV**
23 **Papillomavirus** in feline viral plaques (VP), Bowenoid *in situ* carcinoma (BISC),
24 squamous cell carcinoma (SCC), and actinic keratosis (AK).

25 **Methods:** Twenty-nine cases with previously established diagnosis of feline VP,
26 BISC, invasive SCC, and AK were selected from a dermatopathological
27 database. A critical re-evaluation of diagnosis was performed by defining clear
28 criteria toward carcinomatous vs non carcinomatous, *in situ* vs invasive (if
29 carcinomatous) and viral vs actinic. Cases were evaluated for p16
30 immunolocalisation. The presence of the target viral genes for FcaPV-1, 2, 3
31 and 4 was determined by q-PCR. Data generated $\Delta\Delta Cq$ values, which
32 represent a normalized measure of DNA viral quantity. Samples with a positive
33 $\Delta\Delta Cq$ values were submitted to sequence analysis.

34 **Results:** 4 VPs, 19 BISCs 4 SCCs and 1 AK were included. **By $\Delta\Delta Cq$ analysis**
35 **we found that all VPs were positive for FcaPV-1 or FcaPV-2; and 8 BISCs for**

36 FcaPV-1, 2, 4. The $\Delta\Delta Cq$ detected 3 out of 4 types of FcaPVs. $\Delta\Delta Cq$ detected
37 FcaPV-1 in 1 VP and 3 BISCs, FcaPV-2 in 3 VPs and 6 BISCs, FcaPV-4 in 2
38 BISCs. FcaPV-2 was the most prevalent among the group of VPs and BISCs.

39 **Conclusion and relevance:** Using $\Delta\Delta Cq$ method we report the first evidence of
40 FcaPV-1, 2 and 4 in Italy, FcaPV-2 was the most frequently detected. To a
41 lesser extent also FcaPV-1 and FcaPV-4 has been detected in our examined
42 samples while FcaPV-3 was never associated to viral induced lesions by $\Delta\Delta Cq$
43 investigation. Compared to conventional PCR the $\Delta\Delta Cq$ method has the
44 advantage to allow establish a possible role of the virus in the outcome of
45 infection.

46

47 Introduction

48 Detection of Feline papillomaviruses (FcaPVs) from feline cutaneous
49 lesions has been reported worldwide^{1,2} and these viruses are considered liable
50 of causing several feline skin conditions.¹⁻⁵ These include a wide spectrum of
51 proliferative skin lesions ranging from non-neoplastic viral plaques (VP) to pre-
52 neoplastic Bowenoid *in situ* carcinoma (BISC), and ~~to sarcoid and~~ invasive
53 squamous cell carcinoma (SSC).⁶ A progression from non neoplastic viral
54 induced lesions to overt neoplasia has also been documented to occur.⁷ Four
55 FcaPV types (FcaPV-1 to FcaPV-4) have been so far described in cats, having
56 different anatomical distribution and presentation.^{1,8-11} The most frequent
57 FcaPV (FcaPV-2, belonging to *Dyothetapapillomavirus* genus) was isolated
58 from a cutaneous pigmented plaque,¹² and later related to cutaneous SCC.¹³⁻¹⁵
59 FcaPV-2 seems to play a role in a high proportion of nasal planum squamous
60 cell carcinomas and, animals with tumours associated to papillomaviral
61 aetiology with p16 upregulation, show increased survival compared with those
62 attributable to UV radiation.¹⁶ The relevance of FcaPV-2 in the pathogenesis of
63 both premalignant and malignant lesions has been recently investigated by
64 concurrently assessing number of DNA viral copies and viral gene expression.⁵⁻
65 ⁷ However, the effective role of FcaPV-2 in the development of malignant
66 lesions is still a debated question, especially in view of recent results indicating

67 a high FcaPV-2 prevalence in healthy domestic cats.^{7,17} The role of other feline
68 PV types, namely FcaPV-1, 3, and 4, remains obscure. FcaPV-1, belongs to the
69 *Lambdapapillomavirus* genus and has been rescued from a hyperkeratotic
70 cutaneous lesion in a Persian cat by Tachezy et al.⁹ In the same year another
71 FcaPV was also identified in a shorthair domestic cat with papillomatosis.¹¹
72 More recently the virus was detected in multiple small sessile raised lesions on
73 the ventral surface of the tongue in two 13-year-old domestic cats.¹⁸ FcaPV-3 is
74 a *Taupapillomavirus*, isolated for the first time from a cutaneous in situ
75 carcinoma.³ Recently FcaPV-3 has been detected from a BISC with a novel
76 histological feature and a benign clinical behaviour.¹⁹ The same
77 histopathological **cell** changes were observed in a feline basal cell carcinoma,
78 from which DNA sequences of a novel PV closely related to FcaPV-3 were
79 detected by the authors.⁴ FcaPV-4 belongs to genus *Taupapillomavirus*, and
80 has been detected in oral cavity following a severe gingivitis.¹⁰ Pathogenicity of
81 FcaPV-1 and FcaPV-4 is still unclear and these viruses are rarely detected in
82 oral inflammatory as well as neoplastic lesions. Therefore, an active role of
83 FcaPV-1 and FcaPV-4 in carcinogenesis is still debated.

84 Based on literature, it emerges that most cases of FcaPVs infection have been
85 documented in domestic felids from New Zealand, North and South America
86 and, to a lesser extent from Europe. This might just reflect the active research

87 done in these countries without any epidemiological meaning. In Europe PVs
88 infections have been reported in Switzerland in **only** nine cases,^{12,20} in one case
89 in Germany ²¹ and in **another one** case in Italy.²² **Here we assess by a**
90 **combination of histology, immunohistochemistry and q-PCR the concurrent**
91 **presence of FcaPV-1, 2, 3 and 4 viral DNA and p16 immunostaining in 29 feline**
92 **lesions collected in Italy including non neoplastic and preneoplastic, viral and**
93 **non viral induced skin lesions namely: VP, BISC, invasive SSC and actinic**
94 **keratosis (AK). Two methods were applied to analyse the viral load data:**
95 **absolute quantification (AQ) and relative quantification (RQ). The AQ was**
96 **applied to determine the viral copy number per μg of DNA; however, by this**
97 **method wide range of values can be obtained without a cut-off value that would**
98 **allow to discriminate FcaPVs presence as innocent bystander or as responsible**
99 **of viral lesion. To address this problem we approached the RQ by $\Delta\Delta\text{Cq}$**
100 **calculation.** ²³ **This method measures viral genome presence by relating the**
101 **obtained values of each of the 4 FcaPVs in each lesion classified as VP or**
102 **BISC to those of SCC and AK.**

103 **Materials and methods**

104 *Biopsies*

105 Feline skin biopsies have been identified from dermatopathological databases

106 and 29 cases with a diagnosis of VP, BISC, invasive SCC and AK were
107 selected. The retrieved formalin fixed cases were routinely processed for
108 histopathology and 4 µm thick paraffin embedded tissues sections were stained
109 with haematoxylin and eosin (HE). Before inclusion in the study, the selected
110 samples were subjected to critical re-evaluation of diagnosis by defining clear
111 distinctive criteria, such as carcinomatous vs non carcinomatous, in situ vs
112 invasive (if carcinomatous), and viral vs actinic. The established criteria were
113 defined as described in the scientific literature and are summarized in table
114 1.^{14,20,24} Data from signalment and lesion distribution, when available, were
115 included.

116 *P16 immunohistochemistry*

117 Cases were evaluated for the detection of p16 by immunohistochemistry
118 employing an ABC system (Vector Laboratories, Burlingame, USA). Antigen
119 unmasking was carried out at 120°C for 3 min in a pressure cooker with a TRIS-
120 EDTA buffer (1,2 g/L Tris; 0,36 g/L EDTA; pH 9.0). Sections were pre-treated
121 for 10 min with 1% H₂O₂ in 0.1 M phosphate buffered saline (PBS), pH 7.4 10
122 min to quench endogenous peroxidase activity, and blocked for 30 min at room
123 temperature (rt) in PBS with a 2% normal horse serum (PK-7200, Vector
124 Laboratories, Burlingame, USA) and 0.05% TritonX-100. Sections were then
125 incubated overnight at 4°C with a 1:100 diluted monoclonal primary antibody

126 p16-INK4a (mouse monoclonal IgG, BiorByt, San Francisco, USA). After
127 washing in PBS, an incubation with a secondary universal biotinylated anti-
128 mouse/rabbit antibody (PK-7200, Vector Laboratories, Burlingame, USA) was
129 performed for 1h at rt. Staining was visualized with a diaminobenzidine (SK-
130 4105, Vector Laboratories, Burlingame, USA) solution under a light microscope
131 (Eclipse 80i, Nikon Tokyo, Japan).

132 *Sampling material for q-PCR*

133 Three 10 µm thick sections from the selected samples were cut with a
134 microtome, place onto slides and left unfixed. These slides were observed
135 under an optic microscope. Tissue that was not relevant for the study was
136 scraped off and the remaining tissue directly collected in a DNase free 1,5 ml
137 tube. To prevent carryover of contaminating DNA the microtome overlay was
138 covered with a new piece of adhesive tape and a new blade was used for each
139 sample. and the microtome overlay covered with a new piece of adhesive tape.

140 *DNA extraction*

141 DNA extraction was performed using DNeasy Blood and Tissue kit (Qiagen,
142 Hilden, Germany) following manufacturer's instruction and applying a
143 preliminary removal of paraffin by extraction with xylene. DNAs were eluted in
144 30 µl, and each sample concentration was quantified using the Qubit Nanodrop

145 spectrophotometer (ThermoFisher Scientific, Waltham, USA), DNA samples
146 were stored at -20°C until analysis.

147 *q-PCR*

148 The extracted DNAs were amplified using four specific set of primers amplifying
149 a portion of the four types of FcaPVs L1 gene so far identified in the feline
150 species (Table 2). To normalize the amount of DNA used for each sample so to
151 achieve a correct quantification of viral copy number, a q-PCR under the same
152 condition as for FcaPV but with a specific set of primers was run in parallel for
153 the reference gene albumin (ALB).²⁵ The number of copy of the target viral
154 gene, measured as Cq value, generates a ΔCq value when compared to the
155 corresponding Cq value of the reference gene. Moreover, a $\Delta\Delta Cq$ value was
156 calculated comparing the ΔCq value of the sample of interest to the mean ΔCq
157 value obtained from the SCC and AK group, considered as the negative control
158 group. The $\Delta\Delta Cq$ value represents a normalized measure of DNA viral quantity
159 and was calculated using REST software.²⁶ In this work, a RQ using the $2^{-\Delta\Delta Cq}$
160 method²³ was adapted to estimate in each sample the fold change of FcaPV-1,
161 2, 3 and 4 target viral gene copies relative to the albumin reference gene.
162 Melting curve analysis was performed in conjunction with each four specific
163 FcaPV amplification protocol to determine if non specific products were

164 amplified during reaction. The specificity of the melting curve was compared to
165 melting curves values obtained from a plasmid (pFcaPV) containing amplicon of
166 the four FcaPVs spanning the real-time products. The plasmid was generated
167 by inserting the four FcaPVs gene segments into pMA-T vector using GeneArt
168 technology (Thermo Fisher Scientific, Waltham, USA). Serial dilutions of
169 pFcaPV plasmid ranging from 10^6 to 10^2 copies/5 μ l were used to calculate the
170 efficiency of q-PCR for each FcaPV set of primers and compared to the
171 efficiency calculated on five points of a 2-fold serial dilution of a quantified DNA
172 template for ALB gene. The efficiency of each q-PCR assay was similar and
173 ranging from 91% to 98% (average 94,6%). The lesions identified by
174 histological classification as SCC-AK were presumed to serve as the negative
175 control group and each sample belonging to this group was also individually
176 tested by $\Delta\Delta Cq$ analysis for each FcaPV type. Samples that had eventually
177 scored a positive $\Delta\Delta Cq$ value were excluded. In addition, the viral copy
178 number/ μ l of input DNA for each FcaPV type in each sample tested was
179 calculated (AQ). The assays were performed in Rotorgene thermocycler
180 (Corbett Research, Sydney, Australia) using SSCO sybr green master mix
181 (Biorad, Hercules, USA) and 5 μ l of extracted DNA. All samples were tested in
182 duplicate and the results were calculated using the mean Cq values. Samples
183 positive for only one replica were considered as negative. All samples with a

184 positive $\Delta\Delta Cq$ values were submitted to sequence analysis (BMR genomics,
185 Padova, Italy).

186 **Results**

187 Histologically all VPs were recognized for areas of focal epidermal
188 dysplasia with koilocytes and keratinocytes with cytoplasm enlarged by blue-
189 greyish material. Regarding BISC diagnosis, the presence of koilocytes or
190 koilocyte-like cells pointed to the viral origin in 17/20 cases while in the
191 remaining 3 cases **diagnosis was formulated by** other morphological details
192 listed in Table 1. **were used to formulate the diagnosis.** SCC and AK showed
193 the morphological alterations listed in Table 1. Among the 20 BISCs cases 5
194 VPs were also detected in the adjacent skin by histology and in other 5, sites
195 of penetration of keratinocytes through the basement membrane into the
196 dermis were observed indicative of progression toward SCC.

197 Clinical reports for each of the 29 cases fulfilling the established
198 histological criteria were recorded. Breed, age, gender and anatomical
199 distribution are summarised in Table 3. Twenty-five subjects were shorthair
200 domestic cats, two persian and two main coons. Mean age at presentation
201 varied between 6 and 20 years (median 11,6), 14 out of 29 were female and
202 15 were male. A total of 4 VPs, 20 BISCs, 4 SCCs and 1 AK were detected.

203 Lesions were observed in densely haired skin regions in 9 cats (dorsum,
204 flank, and shoulder), in areas non-exposed to sunlight in 1 cat (groin) and in
205 hypotrichotic and solar exposed skin in 18 cats (ears, nose, eyelids, temporal
206 region). All cases of SCC were observed in sun-exposed areas. Clinically
207 VPs were few millimeters wide, **unique alone** or grouped, slightly raised,
208 pigmented and non-pruritic lesions; BISCs were clinically larger than VPs,
209 usually more than 1 cm of diameter, multifocally coalescing, raised and often
210 verrucous, crusted and hyperpigmented. In SCC, erosive and ulcerative
211 crusted lesions were clinically detected. In the only case in which AK was
212 diagnosed, erythema, scales and crust were seen (Figure 1a, b, c).

213 P16 was immunolocalized in all VPs epidermis and in the epidermis and
214 follicular wall of the BISCs. No signal or only faint staining was detected in
215 the SCC and AK lesion. Immunoreactivity was either nuclear and
216 cytoplasmic; in VPs and BISCs the signal was strong while in the SCCs
217 immunoreactivity was faint and therefore considered as no significant
218 (Figure 1d).

219 By q-PCR we were able to detect the albumin reference gene in 28 out of 29
220 DNA samples. Only one sample classified as BISC was not suitable to
221 molecular analysis and therefore it was excluded from further analysis.

222 By AQ, the presence of FcaPVs has been detected in low copies in almost all
223 cases (Table 4). By RQ ($\Delta\Delta Cq$ method) a reduced number of samples was
224 linked to viral lesions. In details, FcaPVs positive $\Delta\Delta Cq$ values were detected
225 in all VPs (4/4) and in 8/19 BISCs (Table 3). VPs were positive to FcaPV-2 in
226 three samples and to FcaPV-1 in one sample. BISCs were positive to FcaPV-
227 2 in three samples, FcaPV-4 and FcaPV-1 in one sample each. Interestingly,
228 as never reported before, in BISCs lesion we found three cases of double
229 infection. In two of those, FcaPV-1 and 2 were detected simultaneously and
230 in one case FcaPV-2 was present along with FcaPV-4 (table 3).

231 ~~The presence of FcaPVs has been detected in low copies in almost all cases~~
232 ~~(Table 4). By $\Delta\Delta Cq$ analysis a reduced number of cases was identified:~~
233 ~~FcaPVs positive $\Delta\Delta Cq$ value were detected in all VPs (4/4) and in 8/19~~
234 ~~BISCs (table 3). The PV type most frequently detected was FcaPV-2 that~~
235 ~~was the unique PV in 3 out of 4 VPs and in 3 BISCs; in 2 BISCs FcaPV-2~~
236 ~~was associated to FcaPV-1, and in 1 case FcaPV-2 was associated to~~
237 ~~FcaPV-4. FcaPV-1 was the other detected unique PV type in 1 VP and 1~~
238 ~~BISC, while FcaPV-4 was the unique PV type in only 1 BISC (Table 3).~~

239 In all cases with a positive $\Delta\Delta Cq$ value, the viral load was always greater
240 than 10^2 copies / μg DNA (FcaVP-1: min 167 – max 310 Standard Error (SE):

241 33,0; FcaPV-2: min 100 – max 1150 SE: 163,9; FcaPV-4 min 391 – max
242 3700 SE: 1654,5) (Table 4). Sequence analysis confirmed the FcaPV types
243 as indicated by q-PCR $\Delta\Delta Cq$ analysis. ~~Number of $\Delta\Delta Cq$ FcaPV1-4 positive~~
244 ~~samples for each type of lesion are summarized and showed in~~
245 ~~supplementary material.~~

246 Discussion

247 In this retrospective study, we detected the concurrent presence, we
248 ~~investigated the presence of~~ different types of PVs, namely of FcaPV-1, 2,
249 and 4 in feline VPs and BISCs by $\Delta\Delta Cq$ method using specific primers. To
250 the best of our knowledge only the concurrent presence of FcaPV-2 and 3
251 have been reported from one BISC and one VP.^{3,22}

252 ~~. The data obtained on concurrent presence of more than one PV type~~
253 ~~is not unexpected since multiple PVs infection has been previously detected~~
254 ~~in single skin samples from cats; FcaPV-2 and FcaPV-3 have been~~
255 ~~concurrently detected in a feline BISC by Munday et al and from a viral~~
256 ~~plaque by Alberti et al.~~ However differently from previous reports, here we
257 report the presence of FcaPV-1 and FcaPV-4, alone or in association to
258 FcaPV-2.

259 A limitation when performing PCR-based studies on PVs infection is
260 that the viral DNA is often detected and cannot be directly linked to an
261 effective role of virus in pathogenesis and therefore it is not possible to fully
262 establish whether the presence of a viral genome is uneventful (subclinical
263 lesion). In particular, FcaPV-2 has been recently detected in a number of skin
264 swabs from healthy cats, making difficult to discern whether PVs are causing
265 cancer or are merely an “innocent bystander”.⁷ The hypothesis that the
266 presence of high viral loads likely represents an infectious state of PV is
267 supported by Thomson et al.⁷ who recently showed that the finding of high
268 copy numbers of FcaPV-2 DNA within a lesion suggests that the detected
269 virus may be responsible for it. In fact, while high viral copy numbers were
270 associated with E6/E7 gene expression, no gene expression was detected in
271 association of low copy numbers, an indication of an incidental finding.

272 For the above-mentioned reasons, for this study we used a q-PCR
273 protocol applying a $\Delta\Delta Cq$ method to investigate if and which FcaPVs have
274 induced the lesion in cats. In this sense the obtained results are partially in
275 line with the scientific literature which indicates so far that FcaPV-2 is the
276 major PV type implicated in skin preneoplastic and neoplastic lesions in
277 cats.⁷ Since the genome organization and the role of viral proteins within the
278 replication cycle are considered similar even between different genera

279 belonging to the *Papillomaviridae* family we assumed that a similar link is
280 maintained for feline PVs other than FcaPV-2. Importantly we reported
281 positive $\Delta\Delta Cq$ values for FcaPV-1 and 4; two FcaPV types rarely reported.^{9–}
282 ^{11,18} It is noteworthy the observation that also FcaPV-1 and FcaPV-4 showed
283 positive $\Delta\Delta Cq$ values however no data are available on these two types for
284 comparison.

285 A comparison between our data with those obtained from other studies
286 is difficult for two reasons: i) type of PCR primers used (specific vs
287 consensus); ii) type of PCR used (conventional vs quantitative). A general
288 prevalence ranging from 24 to 100% of FcaPV-2 both BISCs and VPs has
289 been reported.^{7,8,27,28} The rate of PV detection by $\Delta\Delta Cq$ analysis was in
290 agreement with previous studies which reported a prevalence ranging from
291 24 to 61% . Moreover, using $\Delta\Delta Cq$ might have lowered the prevalence. In
292 our study, by using specific primers in a q-PCR analysis applying RQ
293 method, we obtained a prevalence for FcaPV-2 in BISCs of 31,6% (6/19) and
294 for all FcaPV types of 42,10% (8/19).

295 Failure to demonstrate PV DNA in every BISC have been previously explained
296 through a carcinogenesis model in which papillomaviruses cause transformation
297 but are only for a short period present within the lesion.²⁹ Surprisingly, cases in

298 which koilocytes were detected did not show any $\Delta\Delta Cq$ positive value; this
299 result is likely due to: i) the detection of koilocytes in very focal lesions that
300 could have been no more present when additional serial paraffin sections were
301 prepared for DNA extraction and PCR analysis; ii) the presence of a PCR
302 undetectable PV variant.

303 Low viral copies for all PV types have been detected in almost all cases,
304 however the $\Delta\Delta Cq$ analysis was necessary to associate the FcaPVs as
305 biological agent potentially causing the lesions. $\Delta\Delta Cq$ positive values for the
306 different PV types were detected in all VPs and in 42% of BISCs. Low viral
307 copies number was also detected from the SCC-AK group resulting in a not
308 detectable $\Delta\Delta Cq$. Noteworthy, mean $\Delta\Delta Cq$ of positive samples differed
309 among PV types being 62.5, 189.1 and 3083.5 for FcaPV-1, FcaPV-2 and
310 FcaPV-4 respectively. Studies considering a larger panel of cases might be
311 necessary to establish a further $\Delta\Delta Cq$ cut off value.

312 Here we document the presence of FcaPV-2 with high prevalence in both
313 VPs and BISCs while we rescued FcaPV-1 and FcaPV-4 less frequently;
314 these last two PVs are rarely described as playing an active role in skin and
315 oral mucosa lesions in cats.^{9,10,18,30} None of the lesions was associated to

316 FcaPV-3 when adopting $\Delta\Delta\text{Cq}$ method, confirming the rare occurrence of this
317 FcaPV type also in Italy.

318 Either cytoplasmic or nuclear p16 signals were detected in all cases where
319 cytopathic effects were found (VP, BISC) while p16 immunolocalisation was
320 present with faint and mainly cytoplasmic signal in cases of SCCs and no p16-
321 immunoreactivity was found in the case of AK. Despite the difficulties of
322 interpretation when the signal was faint, these results are in line with what
323 already documented previously. About half of the SCC studied by Thomson et
324 al.⁷ were negative to p16 immunostaining. A strong association between
325 FcaPV-2 E6/E7 gene expression and p16 immunostaining have been recently
326 found in feline SCC with 18 of 20 (90%) E6/E7-positive SCCs being also
327 positive for p16 compared to 13 of 40 (33%) E6/E7-negative SCCs.⁷ E6/E7 gene
328 expression investigation has not been carried out in our study but our results
329 might reflect this correlation.

330 **Conclusion**

331 $\Delta\Delta\text{Cq}$ analysis has proved to be necessary to associate the FcaPVs as
332 biological agent potentially causing the lesions. Based on this method the
333 presence of FcaPV-2 is confirmed to be the most representative FcaPV in
334 feline skin lesions referable to diagnosis of VP and BISC in Italy. To a lesser

335 extent also FcaPV-1 and FcaPV-4 has been detected in our examined
336 samples. while FcaPV3 was never detected.

337

338 **Acknowledgement:** The authors thank all the colleagues who referred the
339 cases.

340 **Conflict of interest:** The authors declared no potential conflicts of interest with
341 respect to the research, authorship, and/or publication of this article

342 **Source of funding:** This study was financially supported by Fondi di Ateneo
343 University of Pisa.

344 **Bibliografy**

- 345 1. Sundberg JP, Van Ranst M, Montali R, et al. Feline papillomas and
346 papillomaviruses. *Vet Pathol* 2000; 37: 1–10.
- 347 2. Gil da Costa RM, Peleteiro MC, Pires MA, et al. An Update on Canine,
348 Feline and Bovine Papillomaviruses. *Transboundary and Emerging*
349 *Diseases*, 11 September 2016. Epub ahead of print 11 September 2016.
350 DOI: 10.1111/tbed.12555.
- 351 3. Munday JS, Dunowska M, Hills SF, et al. Genomic characterization of
352 *Felis catus* papillomavirus-3: a novel papillomavirus detected in a feline
353 Bowenoid in situ carcinoma. *Vet Microbiol* 2013; 165: 319–25.
- 354 4. Munday JS, French A, Thomson N. Detection of DNA sequences from a
355 novel papillomavirus in a feline basal cell carcinoma. *Vet Dermatol* 2017;
356 28: 236-e60.

- 357 5. Munday JS, Gwyther S, Thomson NA, et al. Bilateral pre-auricular
358 papillary squamous cell carcinomas associated with papillomavirus
359 infection in a domestic cat. *Vet Dermatol* 2017; 28: 232-e58.
- 360 6. Scott DW, Miller WH, Griffin CE, et al. Muller & Kirk's Small Animal
361 Dermatology. Epub ahead of print 2001. DOI: 10.1016/B978-0-7216-
362 7618-0.50002-X.
- 363 7. Thomson NA, Munday JS, Dittmer KE. Frequent detection of
364 transcriptionally active *Felis catus* papillomavirus 2 in feline cutaneous
365 squamous cell carcinomas. *J Gen Virol* 2016; 97: 1189–97.
- 366 8. Munday JS, Kiupel M, French AF, et al. Detection of papillomaviral
367 sequences in feline Bowenoid in situ carcinoma using consensus primers.
368 *Vet Dermatol* 2007; 18: 241–5.
- 369 9. Tachezy R, Duson G, Rector A, et al. Cloning and genomic
370 characterization of *Felis domesticus* papillomavirus type 1. *Virology* 2002;
371 301: 313–21.
- 372 10. Dunowska M, Munday JS, Laurie RE, et al. Genomic characterisation of
373 *Felis catus* papillomavirus 4, a novel papillomavirus detected in the oral
374 cavity of a domestic cat. *Virus Genes* 2014; 48: 111–119.
- 375 11. Terai M, Burk RD. *Felis domesticus* papillomavirus, isolated from a skin
376 lesion, is related to canine oral papillomavirus and contains a 1.3 kb non-
377 coding region between the E2 and L2 open reading frames. *J Gen Virol*
378 2002; 83: 2303–7.
- 379 12. Lange CE, Tobler K, Markau T, et al. Sequence and classification of
380 FdPV2, a papillomavirus isolated from feline Bowenoid in situ carcinomas.
381 *Vet Microbiol* 2009; 137: 60–65.
- 382 13. Ravens PA, Vogelnest LJ, Tong LJ, et al. Papillomavirus-associated
383 multicentric squamous cell carcinoma in situ in a cat: An unusually
384 extensive and progressive case with subsequent metastasis. *Vet*
385 *Dermatol* 2013; 24: 642-e162.
- 386 14. Munday JS. Papillomaviruses in felids. *Vet J* 2014; 199: 340–347.

- 387 15. Altamura G, Corteggio A, Pacini L, et al. Transforming properties of *Felis*
388 *catus* papillomavirus type 2 E6 and E7 putative oncogenes in vitro and
389 their transcriptional activity in feline squamous cell carcinoma in vivo.
390 *Virology* 2016; 496: 1–8.
- 391 16. Munday JS, Gibson I, French AF. Papillomaviral DNA and increased
392 p16CDKN2A protein are frequently present within feline cutaneous
393 squamous cell carcinomas in ultraviolet-protected skin. *Vet Dermatol*
394 2011; 22: 360–366.
- 395 17. Geisseler M, Lange CE, Favrot C, et al. Geno- and seroprevalence of
396 *Felis domesticus* Papillomavirus type 2 (FdPV2) in dermatologically
397 healthy cats. *BMC Vet Res* 2016; 12: 147.
- 398 18. Munday JS, Fairley RA, Mills H, et al. Oral Papillomas Associated With
399 *Felis catus* Papillomavirus Type 1 in 2 Domestic Cats. *Vet Pathol* 2015;
400 52: 1187–1190.
- 401 19. Munday JS, Fairley R, Atkinson K. The detection of *Felis catus*
402 papillomavirus 3 DNA in a feline bowenoid in situ carcinoma with novel
403 histologic features and benign clinical behavior. *J Vet Diagnostic Investig*
404 2016; 28: 612–615.
- 405 20. Wilhelm S, Degorce-Rubiales F, Godson D, et al. Clinical, histological and
406 immunohistochemical study of feline viral plaques and bowenoid in situ
407 carcinomas. *Vet Dermatol* 2006; 17: 424–431.
- 408 21. Egberink HF, Berrocal A, Bax HA, et al. Papillomavirus associated skin
409 lesions in a cat seropositive for feline immunodeficiency virus. *Vet*
410 *Microbiol* 1992; 31: 117–25.
- 411 22. Alberti A, Tore G, Scagliarini A, et al. Regressing Multiple Viral Plaques
412 and Skin Fragility Syndrome in a Cat Coinfected with FcaPV2 and
413 FcaPV3. *Case Reports Vet Med* 2015; 2015: 1–5.
- 414 23. Schmittgen TD, Livak KJ. Analyzing real-time PCR data by the
415 comparative C T method. 2008; 3: 1101–1108.
- 416 24. Levison DA, Parratt D. *Skin Diseases of the Dog and Cat*. Oxford, UK:

- 417 Blackwell Science Ltd. Epub ahead of print 20 July 2005. DOI:
418 10.1002/9780470752487.
- 419 25. Helfer-Hungerbuehler AK, Widmer S, Hofmann-Lehmann R. GAPDH
420 Pseudogenes and the Quantification of Feline Genomic DNA Equivalents.
421 Mol Biol Int 2013; 2013: 587680.
- 422 26. Pfaffl MW, Horgan GW, Dempfle L. Relative expression software tool
423 (REST) for group-wise comparison and statistical analysis of relative
424 expression results in real-time PCR. Nucleic Acids Res 2002; 30: e36.
- 425 27. Nespeca G, Grest P, Rosenkrantz WS, et al. Detection of novel
426 papillomaviruslike sequences in paraffin-embedded specimens of
427 invasive and in situ squamous cell carcinomas from cats. Am J Vet Res
428 2006; 67: 2036–2041.
- 429 28. Munday JS, Peters-Kennedy J. Consistent detection of *Felis domesticus*
430 papillomavirus 2 DNA sequences within feline viral plaques. J Vet Diagn
431 Invest 2010; 22: 946–9.
- 432 29. Smith KT, Campq MS. ‘Hit and run’ transformation of mouse C127 cells
433 by bovine papillomavirus type 4: the viral DNA is required for the initiation
434 but not for maintenance of the transformed phenotype. Virology 1988;
435 164: 39–47.
- 436 30. Munday JS, French AF, Gibson IR, et al. The presence of p16 CDKN2A
437 protein immunostaining within feline nasal planum squamous cell
438 carcinomas is associated with an increased survival time and the
439 presence of papillomaviral DNA. Vet Pathol 2013; 50: 269–73.

440

441

442 LEGEND

443 Figure 1. Multiple symmetrical raised, hyperpigmented and crusted plaques
444 on the face of a cat with Bowenoid in situ carcinoma (a). Histopathology from

445 a viral plaque in a cat. Focal epidermal hyperplasia, absence of follicular wall
446 involvement, evident viral cytopathic effects (koilocytes) (bar=50 μ m) (b);
447 Histopathology from a Bowenoid in situ carcinoma in a cat. Epidermal and
448 follicular dysplasia with upward in situ keratinocyte proliferation and a few
449 koilocytes (bar=50 μ m) (c); p16 immunohistochemistry, groups of
450 keratinocytes show nuclear and cytoplasmic positivity (ABC system, bar=100
451 μ m) (d).

452

Table 1. Histological criteria for the diagnosis of VP VP, BISC, SCC and AK.

Type of lesion	Histopathological criteria
VP	Focal epidermal hyperplasia, koilocytes, clear cells, giant keratoyalin granules, cytoplasm enlarged by blue-greyish fibrillar material, hyperpigmentation;
BISC	Epidermal and follicular dysplasia with upward in situ keratinocyte proliferation, loss of nuclear polarity, windblown nuclei, koilocytes, mitosis;
SCC	Epidermal dysplasia and atypia with downward keratinocyte proliferation, keratinocyte invasion to the dermis through the basal lamina, mitosis;
AK	Epidermal dysplasia and atypia with upward in situ keratinocyte proliferation, squamotisation, apoptosis

Legend: VP viral plaque; BISC Bowenoid *in situ* carcinoma; SCC squamous cell carcinoma; AK actinic keratosis

Table 2. Primers nucleotide sequences

Oligonucleotide name	Nucleotide sequence (5'-3')	5' Nucleotide position	Reference sequence accession number
FcaPV1-F	AGGATGGTGACATGGTGGAT	7143	AF480454
FcaPV1-R	TTTGCACTGTGTGTCTGCAA	7246	
FcaPV2-F	TACACGCGGTACCAATTTCA	7191	EU796884
FcaPV2-R	AGAGTGACCACGCACACTTG	7331	
FcaPV3-F	AAGATTGGTATGGCGTTTGC	5960	JX972168
FcaPV3-R	TTTGCCTTTCATCTGCTGTG	6105	
FcaPV4-F	ATGCAAATGGCCAGACTTTC	6356	KF147892
FcaPV4-R	AAAAATGGCGGCAGTACAAC	6453	
Fel Alb F	GATGGCTGATTGCTGTGAGA	3706	NC_018726.2 GPC_000001738
Fel Alb-R	CCCAGGAACCTCTGTTTCATT	3855	

1

Table 3.

Signalment, lesion distribution, p16 immunolocalisation and FcaPV type assessed by $\Delta\Delta Cq$ analysis in cats with of VP, BISC, SCC and AK diagnosis

Case N°	Diagnosis	Breed	Years	Gender	Lesion distribution	p16	FcaPV type	$2^{-\Delta\Delta Cq}$
1	VP	DSH	10	M	Flank	+	2	119
2	VP	persian	15	F	Groin	+	2	53
3	VP	DSH	9	M	Nose	+	1	72
4	VP	main coon	10	F	Nose	+	2	271
5	BISC	DSH	10	F	Flank	+	-	
6	BISC	main coon	6	M	Shoulder	+	4	5836
7	BISC	DSH	13	M	Nose	+	-	
8	BISC	DSH	13	F	Nose	+	1	49
9	BISC	DSH	9	F	Temporal	+	-	
10	BISC	DSH	20	F	Dorsal	+	ND	
11	BISC	DSH	15	M	Temporal	+	2-4	224-331
12	BISC	DSH	15	M	Nose	+	-	
13	BISC	DSH	16	F	Shoulder	+	-	
14	BISC	DSH	12	M	Ear	+	-	
15	BISC	DSH	12	M	Dorsum	+	2	172
16	BISC	DSH	8	F	Temporal	+	1-2	58-167
17	BISC	DSH	10	F	Temporal	+	-	
18	BISC	persian	15	M	Eyelid	+	2	211
19	BISC	DSH	10	F	Ear	+	-	
20	BISC	DSH	7	F	Flank	+	-	
21	BISC	DSH	10	M	Nose	+	2	159
22	BISC	DSH	15	M	Shoulder	+	-	
23	BISC	DSH	12	M	Nose	+	1-2	71-326
24	BISC	DSH	10	M	Flank	+	-	
25	SCC	DSH	9	F	Ear	+-	-	
26	SCC	DSH	8	M	Nose	+-	-	
27	SCC	DSH	15	F	Ear	+-	-	
28	SCC	DSH	10	M	Eyelid	+-	-	
29	AK	DSH	11	F	Ear	+-	-	

2

3 Legend: VP viral plaque, BISC Bowenoid *in situ* carcinoma, SCC squamous cell carcinoma, AK actinic
 4 keratosis, DSH domestic shorthair, ND non determined.

5 $2^{-\Delta\Delta Cq}$ indicates the fold expression change of FcaPV normalised to Albumin.

6

Table 4. Absolute viral load quantification expressed as viral copy number/ μ g of input DNA

Cases	Type of lesion	FcaPV-1	FcaPV-2	FcaPV-3	FcaPV-4
1	VP	10	<u>153</u>	10	20
2	VP		<u>100</u>		6
3	VP	<u>167</u>	33	23	28
4	VP		<u>1130</u>		
5	BISC	30	48		
6	BISC	18	55	26	<u>3700</u>
7	BISC	13	2		4
8	BISC	<u>201</u>			
9	BISC	42	12		
10	BISC		15		
11	BISC	87	<u>1150</u>	59	<u>391</u>
12	BISC		10		
13	BISC	33	55	28	120
14	BISC				
15	BISC	14	<u>436</u>		
16	BISC	<u>176</u>	<u>210</u>	13	
17	BISC		18		
18	BISC		<u>1120</u>	79	45
19	BISC	3			
20	BISC	33	10		
21	BISC	6	<u>193</u>		
22	BISC				
23	BISC	<u>310</u>	<u>1140</u>	18	26
24	BISC				
25	SSC		6	2	
26	SSC	12	10		17
27	SSC	20	15	7	23
28	SSC	10	5	14	14
29	AK	12	18		
<i>Mean viral load</i>		63	247.7	2.4	366.2
<i>Mean viral load of $\Delta\Delta Cq$ positive samples</i>		213.5	625.8		2045.5
<i>Standard error of $\Delta\Delta Cq$ positive samples</i>		33	163.9		1654.5

Bold and underlined numbers indicate $\Delta\Delta Cq$ positive samples.

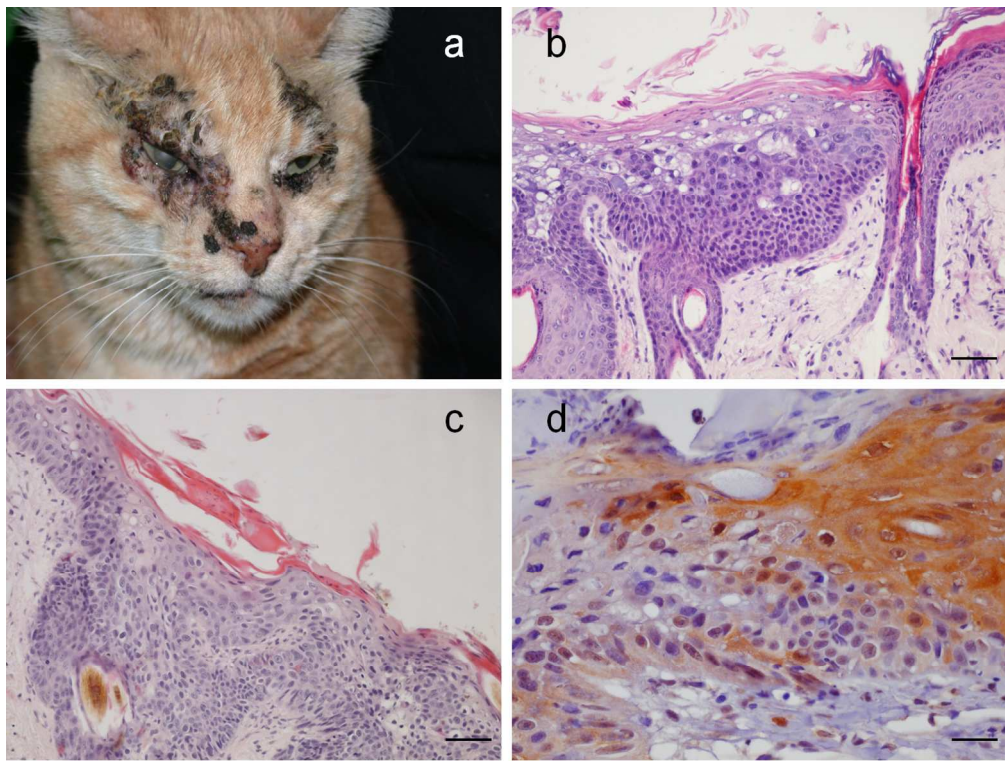


Figure 1

136x103mm (300 x 300 DPI)

review