

Case Report

Membranous Nephropathy Associated with Eosinophilic Gastroenteritis: First Report

Giovanna Pasquariello¹, Daniela Campani², Pinuccia Faviana², Luca Pollina², Matilde Masini³, Pellegrino Masiello³, Giovanni Manca Rizza⁴ and Antonio Pasquariello^{1*}

¹Departmental Section of Immune-Mediated Nephropathies, Azienda Ospedaliero-Universitaria Pisa, Italy

²Department of Pathology, University of Pisa, Italy

³Department of Translational Research and New Technologies in Medicine and Surgery, University of Pisa, Italy

⁴Internal Medicine Unit 2, Pontedera, Italy

***Corresponding author**

Antonio Pasquariello, Departmental Section of Immune-Mediated Nephropathies, AOUP, Via Paradisa 2, 56124 Pisa, Italy; Tel:+39-050-997274; Fax:+39-050-997285; Email: a.pasquariello@ao-pisa.toscana.it

Submitted: 30 October 2014

Accepted: 04 November 2014

Published: 05 November 2014

Copyright

© 2014 Pasquariello et al.

OPEN ACCESS**Keywords**

- Eosinophilic enteritis
- Nephrotic syndrome
- Secondary membranous nephropathy
- Steroidal treatment

Abstract

Membranous nephropathy represents the most common cause of nephrotic syndrome in adult patients. In 85% of cases the disease is classified as idiopathic membranous nephropathy, and in the remainder 15 % as secondary membranous nephropathy (systemic lupus erythematosus, infections, drugs, tumors, inorganics salts). Treatment of secondary membranous nephropathy is guided by therapy of the original disease, or by elimination of the responsible cause. Eosinophilic gastroenteritis is a rare uncommon disease of unknown origin affecting the gastrointestinal apparatus and is characterized by diffuse eosinophilic infiltration of the gastro-enteric wall. Any segment of gastrointestinal tract can be interested, but the stomach results to be the most commonly affected organ, followed by the small intestine and the colon. The diagnosis is based on the presence of gastrointestinal symptoms, documented eosinophilic gut infiltration and the exclusion of intestinal parasites or extraintestinal disease. To date there are no randomized prospective therapeutic trials. The mainstay of treatment is represented by use of corticosteroids (with 90% of remission rate in some reports). We describe for the first time the case of a 43-year-old man affected by eosinophilic gastroenteritis who developed a nephrotic syndrome due to membranous nephropathy after he voluntarily stopped the steroidal oral therapy. Reintroduction of corticosteroid treatment led to the complete remission of the nephrotic syndrome within 6 months treatment.

ABBREVIATIONS

MN: Membranous nephropathy; **IMN:** Idiopathic membranous nephropathy; **EG:** Eosinophilic gastroenteritis.

INTRODUCTION

Membranous (MN) is the most common glomerular disease associated with nephrotic syndrome in adult subjects [1]. In 85% of cases the disease is classified as primary or idiopathic (IMN), and in the remainder 15 % as secondary MN. Recently the idiopathic form of this glomerulopathy resulted to be an autoimmune illness due to the presence of autoantibodies of the IgG4 subclass, against some podocyte antigens [2]. The secondary causes of MN are represented by bacterial and viral infections, drugs, autoimmune diseases, malignancies, diabetes mellitus etc [3]. Treatment of secondary membranous nephropathy is guided

by the therapy of the original disease, or by the elimination of the responsible cause. Eosinophilic gastroenteritis (EG) is an extremely rare and heterogeneous disorder of unknown origin affecting the gastrointestinal apparatus and is characterized by diffuse eosinophilic infiltration of the gastro-enteric wall. This uncommon inflammatory disease was first described by Kaijser in 1937 [4]. At present there are no randomized prospective therapeutic trials. Corticosteroids are the most frequently used therapy for EG [5].

CASE PRESENTATION

In April 2004 a 34-year-old man was admitted to an Emergency Surgical Unit for the clinical suspicion of acute abdomen. Computed tomography scan showed diffuse thickening of the small bowel and of the pyloric antrum associated with mesenteric lymphadenitis and ascites. An emergency laparotomy

was performed revealing signs of acute diffuse sero-hemorrhagic peritonitis and serohaemorrhagic ascites. Laboratory tests revealed eosinophilia (30%). Multiple gastric biopsies revealed eosinophilic gastritis with negative helicobacter pylori test. In December 2004 the patient was admitted to a Gastroenterology Unit because of abdominal pain and diarrhea. Colonoscopic examination associated with mucosal biopsies of the colon and the ileum demonstrated a picture of eosinophilic enteritis with an abundant dense eosinophilic infiltration of the mucosa layer and the presence of lymphocytes (Figure 1). Laboratory tests revealed eosinophilia (22%). In March 2009 the patient underwent a new endoscopic control with repeated small gut biopsies confirming the diagnosis of EG. Successively the disease became corticosteroid-dependent. In May 2013 at age of 43 the patient was referred to the Nephrology Unit for nephrotic syndrome. In January 2014, he noticed progressive oedema in the lower limbs with mild asthenia. Physical examination confirmed the presence of oedema localized in the ankles. Laboratory investigation demonstrated a normal serum creatinine level of 0.8 mg/dl; creatinine clearance was 119 ml/min, total serum proteins 4.7 g/dl, serum albumin level of 2.9 g/dl. Urine analysis showed proteinuria without haematuria or leukocyturia. Complement levels (C3, C4), white blood cell count, red blood count, hematocrit and platelet count were normal. Anti-nuclear antibodies, cryoglobulins, HCV Ab, HBsAg and tumor markers resulted negative. Immunofixation revealed no monoclonal gammopathy. Urine immunoelectrophoresis showed non-selective proteinuria. Lymphoproliferative disorders were excluded. Renal ultrasound examination demonstrated bilateral normal size, with no abnormalities of the renal parenchyma. The patient underwent a real-time ultrasound-guided left kidney biopsy. Light microscopy showed 25 normal sized glomeruli with very slight diffuse thickening of the capillary walls and slight segmental increase of the mesangial matrix. No significant tubular interstitial or vascular lesions were present except for tubular hyaline droplets. Immunofluorescence study showed the presence of diffuse, finely granular deposits of IgG along the peripheral capillary loops (Figure. 2). Electron microscopy confirmed the presence of numerous electron-dense deposits on the subepithelial side of the basement membrane. A diagnosis of stage I membranous nephropathy was made.

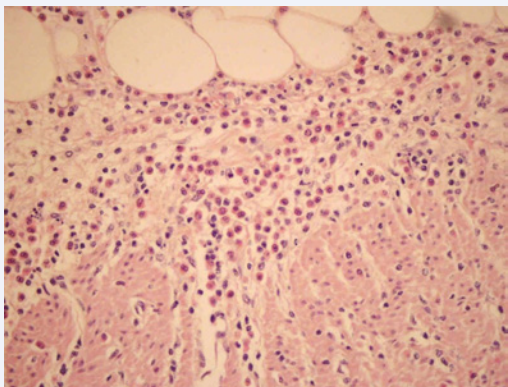


Figure 1 Photomicrograph of a small bowel biopsy specimen evidencing abundant eosinophilic infiltration of the mucosa layer and the presence of lymphocytes. (H&E, X 400).

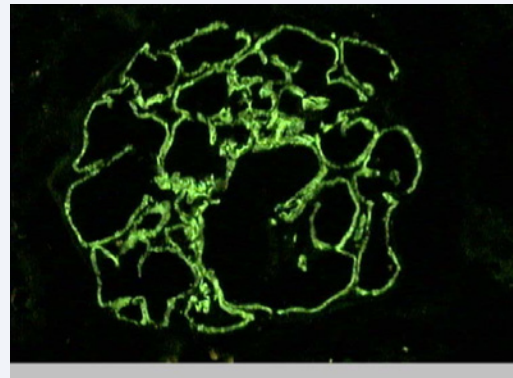


Figure 2 Immunofluorescence microscopy showing a glomerulus with diffuse finely granular peripheral capillary loop deposits of IgG. (X400).

TREATMENT

The patient was treated with 1g intravenous methylprednisolone for three alternate days, followed by oral prednisone administration 0.5 mg/kg per day for 4 months tapered to 12.5 mg per day for two additional months and successively reduced to 10 mg per day and continued until now.

RESULTS

During follow-up proteinuria decreased progressively until reaching normal values with contemporary normalization of albuminemia and proteinemia. After six months steroidal treatment, the nephrotic syndrome disappeared completely with absence of peripheral oedema. Urine examination gave normal results and 24-hour protein excretion under 200 mg/dl. One year after low oral dosage of steroidal therapy the patient's clinical gastrointestinal and nephrological conditions are satisfactory with stable body weight, and persistent disappearance of proteinuria.

DISCUSSION

MN represents the most common glomerular disease associated with nephrotic syndrome in adult patients. In 85% of cases the disease is classified as primary or idiopathic MN (unknown origin or cause), and in the remainder 15 % as secondary MN. In the last 50 years numerous nephrologists and researchers have discussed about a possible autoimmune etiopathogenic cause of the idiopathic MN. Recently the idiopathic form of the disease resulted to be an autoimmune glomerulonephritis due to the presence of autoantibodies of the IgG4 subclass, against some podocyte antigens represented by the M-type phospholipase A2-receptor, manganese superoxide dismutase and aldose reductase, expressed in the podocytes of glomeruli in 70% of cases of patients affected by this disease. The secondary causes of membranous nephropathy include infections such as hepatitis B and C, tuberculosis, syphilis, malaria, leprosy; autoimmune and not autoimmune diseases (SLE, rheumatoid arthritis, Sjogren syndrome, Hashimoto's disease, diabetes mellitus, sickle cell disease), drugs such as gold salts, penicillamine, captopril, nonsteroidal anti-inflammatory agents; malignancies (cancer of the colon, breast, lung etc).

Treatment of secondary membranous nephropathy is guided by the therapy of the original disease, or by the elimination of the responsible cause. In EG any segment of gastrointestinal tract can be interested including the esophagus, but the stomach results to be the most commonly affected organ, followed by the small intestine and the colon. This uncommon disease can involve isolated biliary tract and other organs such as pancreas, liver and tissue outside the gastrointestinal tract [6,7]. The diagnosis is based on the presence of gastrointestinal symptoms, documented eosinophilic gut infiltration and the exclusion of intestinal parasites or extraintestinal disease. Corticosteroids represent the elective treatment of EG with a remission rate of 90% in some reports. The nephrotic syndrome in our patient appeared some months after he voluntarily stopped the steroidal therapy. The reintroduction of corticosteroids led to complete remission of the nephrotic syndrome within 6 months treatment. Therapy of IMN using corticosteroids alone has been used for many years with no evident good results. A meta-analysis of the published randomized trials demonstrated that therapeutical regimens based on steroids alone do not improve the remission rate if compared with symptomatic therapy [8]. Furthermore, many nephrologists believe that there is no evidence supporting the use of steroids as sole therapy in IMN [9,10]. In our case after a cycle treatment of six months, corticosteroids have been continued until now with prednisolone 10 mg/day with persistent absence of proteinuria and no gastrointestinal symptomatology relapse, thus confirming the relationship between EG and MN. To our knowledge, this the first report in literature describing a case of MN secondary to EG.

ACKNOWLEDGEMENT

The authors acknowledge Dr. Laura Cignoni for correcting the manuscript.

REFERENCES

1. Fervenza FC, Sethi S, Specks U. Idiopathic membranous nephropathy: diagnosis and treatment. *Clin J Am Soc Nephrol.* 2008; 3: 905-919.
2. Beck LH Jr, Bonegio RG, Lambeau G, Beck DM, Powell DW, Cummins TD, et al. M-type phospholipase A2 receptor as target antigen in idiopathic membranous nephropathy. *N Engl J Med.* 2009; 361: 11-21.
3. Hofstra JM, Wetzels FM: Management of patients with membranous nephropathy. *Nephrol Dial Transplant.* 2011; 0: 1-4
4. Kaijser R. Zur Kenntnis der allergischen Affektionen des Verdauungskanal vom Standpunkt des Chirurgen aus. *Arch Klin Chir.* 1937; 188: 36-64
5. Mori A, Enweluwo C, Grier D, Badireddy M. Eosinophilic gastroenteritis: review of a rare and treatable disease of the gastrointestinal tract. *Case Rep Gastroenterol.* 2013; 7: 293-298.
6. Polyak S, Smith TA, Mertz H. Eosinophilic gastroenteritis causing pancreatitis and pancreaticobiliary ductal dilation. *Dig Dis Sci.* 2002; 47: 1091-1095.
7. Christopher V, Thompson MH, Hughes S. Eosinophilic gastroenteritis mimicking pancreatic cancer. *Postgrad Med J.* 2002; 78: 498-499.
8. Hogan SL, Muller KE, Jennette JC, Falk RJ. A review of therapeutic studies of idiopathic membranous glomerulopathy. *Am J Kidney Dis.* 1995; 25: 862-875.
9. Cattran DC, Delmore T, Roscoe J, Cole E, Cardella C, Charron R, et al. A randomized controlled trial of prednisone in patients with idiopathic membranous nephropathy. *N Engl J Med.* 1989; 320: 210-215.
10. Muirhead N. Management of idiopathic membranous nephropathy: evidence-based recommendations. *Kidney Int Suppl.* 1999; 70: S47-55.

Cite this article

Pasquariello G, Campani D, Faviana P, Pollina L, Masini M, et al. (2014) Membranous Nephropathy Associated with Eosinophilic Gastroenteritis: First Report. *J Clin Nephrol Res* 1(2): 1009.