

## RESEARCH

# A six-gene panel to label follicular adenoma, low- and high-risk follicular thyroid carcinoma

Anello Marcello Poma<sup>1</sup>, Riccardo Giannini<sup>1</sup>, Paolo Piaggi<sup>2</sup>, Clara Ugolini<sup>3</sup>, Gabriele Materazzi<sup>1</sup>, Paolo Miccoli<sup>1</sup>, Paolo Vitti<sup>4</sup> and Fulvio Basolo<sup>1</sup>

<sup>1</sup>Department of Surgical, Medical, Molecular Pathology and Critical Area, University of Pisa, Pisa, Italy

<sup>2</sup>National Institute of Diabetes and Digestive and Kidney Diseases, National Institutes of Health, Phoenix, Arizona, USA

<sup>3</sup>Department of Laboratory Medicine, Section of Pathology, Azienda Ospedaliero-Universitaria Pisana, Pisa, Italy

<sup>4</sup>Department of Clinical and Experimental Medicine, University of Pisa, Pisa, Italy

Correspondence should be addressed to F Basolo: [fulvio.basolo@med.unipi.it](mailto:fulvio.basolo@med.unipi.it)

## Abstract

The distinction between follicular thyroid carcinomas (FTCs) and follicular-patterned benign lesions is almost impossible on fine-needle aspiration cytology. Furthermore, minimally invasive FTCs (MI-FTCs) with less than 4 vascular invasion foci generally have an excellent prognosis, but there are exceptions and, so far, no molecular marker appears able to identify them reliably. We aimed to distinguish benign lesions from low- and high-risk FTCs by a small-scale combination of genes. The expression analysis of 75 selected genes was performed on 18 follicular adenomas (FAs), 14 MI-FTCs and 6 widely invasive FTC (WI-FTCs). The mutational status of the *RAS* genes, *TERT* promoter and *PAX8-PPARG* rearrangements was also investigated. Seven samples were mutated, namely 3 MI-FTCs and 4 WI-FTCs. Twenty-five genes were differentially expressed (FDR <0.05) between FAs and WI-FTCs. Six of these (*ECM1*, *RXRG*, *SDPR*, *SLC26A4*, *TIFF3*, *TIMP1*) were also differentially expressed among MI-FTCs and FAs or WI-FTCs and were considered to build a classification model, which was tested to classify samples according to their histological class. Hence, 31 out of 38 were correctly classified, and accuracy remained high after cross-validation (27/38). The 2 MI-FTCs incorrectly classified as WI-FTCs harbored both *RAS* and *TERT* promoter mutations. The capability of these six genes to stratify benign, low- and high-risk lesions appears to be promising in supporting the diagnosis of indeterminate thyroid nodules.

## Key Words

- ▶ gene expression
- ▶ follicular thyroid carcinoma
- ▶ FTC
- ▶ minimally invasive
- ▶ biomarker

Endocrine Connections  
(2018) 7, 124–132

## Introduction

The incidence of follicular thyroid carcinoma (FTC) has decreased over the last years (1), but still accounts for 10–15% of all thyroid cancers (2). The distinction between follicular adenoma (FA) and FTC, conventionally classified as minimally invasive (MI-FTC) and widely invasive (WI-FTC) (3), cannot be determined by fine-needle aspiration cytology (FNAC), since the demonstration of malignancy in these types of lesions is based on the presence of capsular and/or vascular invasion, which can be assessed only after diagnostic surgery and histological observation (4). However, in these cases, postoperative diagnoses reveal a

high rate of unnecessary or inadequate surgeries (5). Several authors have suggested to further distinguish angioinvasive MI-FTCs (or moderately invasive FTCs) from MI-FTCs with tumor capsular invasion only (4, 6). However, it has been demonstrated that the extensive circumferential evaluation of the capsule not only allows to reach a higher effectiveness in the distinction between benign and malignant follicular neoplasms, but also yields a more adequate assessment of invasive vascular foci that are often underestimated by random histological section sampling. These results have highlighted that the presence of capsular invasion could

<http://www.endocrineconnections.org>  
<https://doi.org/10.1530/EC-17-0261>

© 2018 The authors  
Published by Bioscientifica Ltd



This work is licensed under a [Creative Commons Attribution-NonCommercial 4.0 International License](https://creativecommons.org/licenses/by-nc/4.0/).

be an indicator of vascular invasion (7). Although follicular lesions with vascular invasion were associated with a higher risk than those with solely capsular invasion (8, 9), only extensive vascular invasion (i.e. 4 or more vascular invasion foci) strongly correlated with a worse outcome (10, 11). Latest guidelines of the American Thyroid Association (ATA) then suggest a cutoff of 4 intracapsular vascular invasion foci to distinguish low- from high-risk MI-FTC (12). Even the degree of tumor capsule invasion for the diagnosis of MI-FTC is controversial; in fact, some authors have questioned whether a partial invasion may be sufficient for FTC diagnosis (13). However, some studies have justified FTC diagnosis in the presence of capsular invasion (even partial) without vascular involvement, since these tumors, although rarely, can develop recurrences and metastatic disease (14, 15). Despite the unresolved issues in MI-FTC diagnosis, it has been well demonstrated that MI-FTCs generally have a better outcome than WI-FTCs, with a low rate of recurrence, metastatic disease and disease-related mortality (2, 16, 17). For these reasons, the latest guidelines of the ATA suggested that lobectomy may be a sufficient treatment for low-risk FTC (i.e. MI-FTC with less than 4 vascular invasion foci) (12). However, molecular markers such as *TERT* promoter mutations were found to be an independent poor prognosis factor in differentiated thyroid cancer (DTC) (18, 19), especially in coexistence with *BRAF* or *RAS* mutations (20). Then, ATA guidelines have suggested that these molecular markers, alone or in combination, may be helpful to provide a more accurate risk-stratification of DTC, and in addition to the other clinico-pathological risk factors, may redefine the surgical approach to these lesions (12). In the last years, large-scale screening studies have disclosed many other potential biomarkers for the preoperative diagnostics of FTC, including both somatic mutations (21) and expression profiling (22, 23, 24), but none of them have been found to be conclusive. In the present study, we sought to find molecular biomarkers, which could help distinguish MI-FTCs from both FAs and WI-FTCs. Furthermore, the combination of gene expression analysis and genotyping could be useful for the stratification of MI-FTCs with similar clinico-pathological features.

## Materials and methods

### Study group

The study included 40 patients with diagnoses of FA, MI-FTC or WI-FTC, who underwent total/near-total thyroidectomy at the Department of Surgical, Medical, Molecular Pathology and Critical Area of the University of

Pisa, Italy, between 2013 and 2015. Hematoxylin and eosin-stained sections of neoplasms obtained from the archives of the section of Pathology of the University Hospital of Pisa were re-evaluated independently by two pathologists (C U, F B). A diagnostic concordance rate of 98% was achieved between the two investigators. Discordant cases were eliminated. Tumors were diagnosed and classified according to the WHO 2004 histopathological criteria (3). For all FAs and MI-FTCs, the neoplastic capsules were examined *in toto*. Moreover, the vascular invasiveness and the infiltration of thyroid parenchyma and extra-thyroid tissues were evaluated. Hürthle cells neoplasms or neoplasms with oncocyctic aspects were excluded from the study. To avoid contamination with other cell types, cases with any grade of thyroiditis were excluded, and only neoplasms with almost 50% of neoplastic cellularity were considered for the examination. This retrospective work was performed on archival material, and it was conducted anonymously; therefore, ethical committee approval was not required. The study conforms to the Principles of the Helsinki Declaration of 1975. Both informed and surgical consent were achieved one day before the operation.

### Nucleic acids extraction and purification

The most representative FFPE tissue block was considered for each specimen. Two micrometer sections were taken from each block, stained with hematoxylin and eosin and histologically examined to confirm the presence of tumor tissue. The tumor area was marked and the tumor cell percentage was indicated by the pathologist. For each sample, 4 unstained 10 µm sections and 5 µm sections were used for DNA and RNA extraction, respectively. Unstained sections were deparaffinized with xylene and rehydrated in decreasing-grade ethanol solution. Manual micro-dissection was performed to maximize the amount of tumor cells. DNA was extracted and purified by using the QIAamp DNA Mini Kit (Qiagen), according to the manufacturer's protocol. DNA was eluted in 50 µL of elution buffer. RNA was isolated using the RNeasy FFPE Kit (Qiagen) in conformance to the manufacturer's instructions. RNA was eluted in 20 µL of RNase-free water. RNA and DNA quantification and quality were assessed by means of a spectrophotometer (Xpose Trinean, Gentbrugge, Belgium).

### Detection of point mutations and rearrangements

The mutational status of *NRAS* (exons 2 and 3), *HRAS* (exons 2 and 3), *KRAS* (exons 2 and 3) and of the *TERT* promoter was tested by direct sequencing (3130 Genetic

Analyzer, Applied Biosystems), according to the standard procedures (25). In addition, the presence of *PAX8-PPARG* rearrangements (exons 7 and 9) was evaluated by a two-step RT-PCR. Firstly, 600 ng of total RNA were used to synthesize cDNA by the RevertAid First Strand cDNA Synthesis Kit (Thermo Scientific) in a reaction volume of 20  $\mu$ L. Secondly, 75 ng of cDNA were amplified in a 20- $\mu$ L volume by Premix Ex Taq (Takara Bio), 4 ng of each primer (25) and 8 ng of probe (25), following the manufacturer's suggestions. Amplification was performed in 40 cycles (denaturation at 95°C for 5 s and annealing and elongation at 56.5°C for 30s) according to the manufacturer's protocol. Each sample was amplified in duplicate, cDNA adequacy was tested by amplifying *GAPDH* housekeeping gene in double copy for each sample, and each assay included a double copy of the positive controls. Only the samples in which both *GAPDH* copies were amplified were considered suitable for rearrangement-positivity evaluation. The amplification of both *GAPDH* and *PAX8-PPARG* was positively considered when the cycle threshold was less than 35 cycles. The cases resulting positive for rearrangements were confirmed by direct sequencing (3130 Genetic Analyzer, Applied Biosystems).

### NanoString analysis

The nCounter custom code set used in this study was designed and synthesized by NanoString Technologies (Seattle, Washington, USA). This code set consisted of reporter and capture probe pairs specific for the 75 genes and 5 housekeeping genes, which was already used by our group (26). In this assay, 150 ng of total RNA were hybridized with reporter and capture probes for 16 h at 65°C in a SensoQuest thermal cycler (SensoQuest, Gottingen, Germany). Sample clean-up and the counts of digital reports were performed as recommended by the manufacturer's instructions. Five MI-FTCs were analyzed in triplicate to evaluate their potential intra-tumor RNA heterogeneity, by employing the RNA extracted from 3 different areas of the lesion. The first included the RNA from the entire tumor, the second from the non-invasive area and the third from the invasive foci.

### Statistical analysis and bioinformatics tools

The differential expression analysis among FAs, MI-FTCs and WI-FTCs was performed using the procedures of the Limma R package (27). The design matrix contrasted all three group pairings by the voom transformation of counts (28). The Bayes function was used to compute the empirical

Bayes moderated differential expression statistics. Genes with a false discovery rate (FDR) below 0.05 were considered to be differentially expressed between groups. Multiple discriminant analysis and leave-one-out cross-validation were then used to quantify the accuracy of classification of differentially expressed genes. In brief, two linear and orthogonal discriminant functions were calculated, based on the  $\log_2$  expression values of differentially expressed genes to maximize the distances between the averages (centroids) of the three groups. Specifically, the two discriminant functions were used to calculate a classification score for each sample, and centroids were calculated for each discriminant function as the average score of the samples belonging to the specific group. Each sample was then assigned to the group with the shortest distance to the closest group centroid. The accuracy of classification was calculated as the proportion of samples correctly classified within the actual group. Finally, leave-one-out cross-validation was done by computing the two discriminant functions in 37 samples (training set), and the remaining sample was used to test the accuracy of classification of the discriminant functions. Cross-validation was then run 38 times, each time with a different training set, and overall accuracy was calculated as the proportion of samples correctly classified within the actual group over all the 38 runs. Unsupervised hierarchical clustering was performed on normalized data with the nSolver 2.5 Analysis Software (NanoString Technologies). Clustering was applied independently to both samples (columns) and genes (rows) by Pearson's correlation ( $r$ ). The prediction of the effects of the newly reported amino acid substitution was performed using the PredictSNP tool (29).

## Results

### Clinico-pathological features

A total of 38 samples were eligible for inclusion in the study: 18 FAs, 14 MI-FTCs and 6 WI-FTCs. Every case had a complete follicular growth pattern and a total absence of oncocyctic aspects and thyroiditis. Each selected tumor area had more than 60% of neoplastic cells. Seven of the 14 MI-FTCs showed capsular invasion only, while the others had both capsular and vascular invasion foci (less than 4). Furthermore, 7 MI-FTCs had only a partial invasion of the capsule. Four of the 6 WI-FTCs had extraglandular spread, whereas 2 were intrathyroidal tumors. Mean age at diagnosis was  $48.1 \pm 13.7$  years, and mean tumor size was  $29.1 \pm 13.1$  mm. Thirty cytological diagnoses, classified according to the Bethesda system (30), were available: 21 were category III, 8 were category IV and 1 was category V.

**Table 1** Genotyping results of 18 follicular adenomas, 14 minimally invasive follicular thyroid carcinomas and 6 widely invasive follicular thyroid carcinomas.

	NRAS			KRAS	TERT promoter	PAX8-PPARG	TOTAL no. of mutated samples
	Q61R, n	Q61K, n	M72L, n	Q61R, n	C228T, n	ex.7, n	
FAs	0	0	0	0	0	0	0
MI-FTCs	0	1	1	1	2	1	3
WI-FTCs	4	0	0	0	0	0	4
Total	4	1	1	1	2	1	7

Fas, follicular adenomas; MI-FTCs, minimally invasive follicular thyroid carcinomas; WI-FTCs, widely invasive follicular thyroid carcinomas.

**Genotyping results**

All samples but 3 were suitable for genotyping analysis. None of the FAs harbored mutations, whereas 3 MI-FTCs were mutated (one had a *PAX8-PPARG* rearrangement and 2 were mutated both in *TERT* promoter and *RAS* genes, *NRAS* in one case and *KRAS* in the other); finally, 4 WI-FTCs harbored *NRAS* mutations (Table 1). The newly reported *NRAS* M72L mutation was found in heterozygosis and should not be deleterious according to the PredictSNP result.

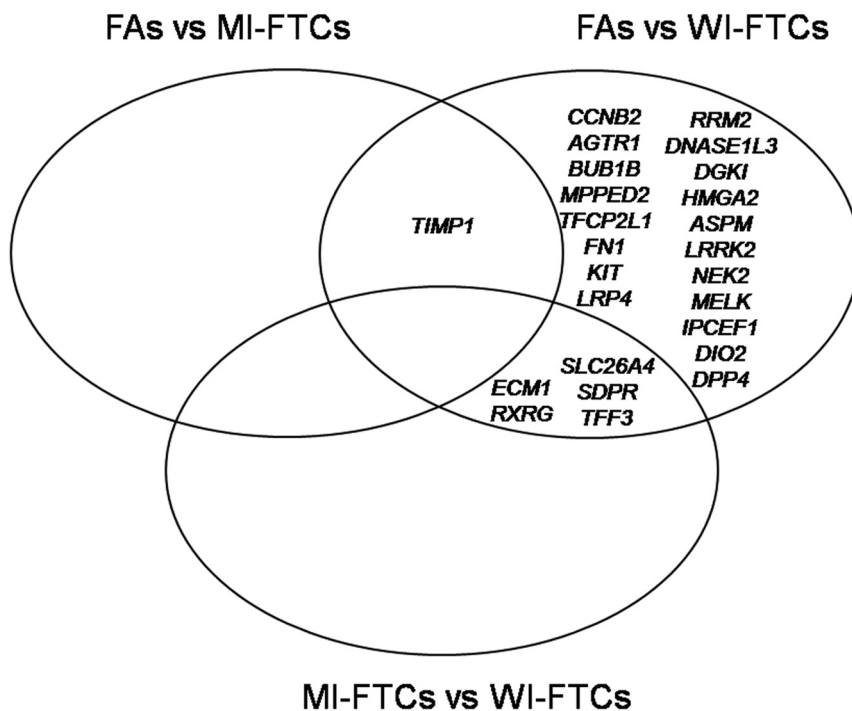
**Gene expression analysis of the 75-gene panel**

All samples passed the quality control and were included in the differential gene expression analysis. Raw expression data were normalized using both housekeeping genes and positive controls (31). Samples analyzed in triplicate showed an average Pearson’s correlation of 0.90 (data not shown). Normalized expression levels were used to identify

differentially expressed genes (DEG) among FAs, MI-FTCs and WI-FTCs based on a FDR <0.05. Twenty-five genes were deregulated between FAs and WI-FTCs; specifically, 14 and 11 were upregulated and downregulated in WI-FTCs compared to FAs, respectively; five were also differentially expressed between MI-FTCs and WI-FTCs; in particular, *ECM1* and *RXRG* were upregulated and *SLC26A4*, *SDPR* and *TFF3* were downregulated in WI-FTCs. Finally, *TIMP1* was upregulated in MI-FTCs and WI-FTCs compared to FAs (Fig. 1 and Supplementary Table 1, see section on supplementary data given at the end of this article).

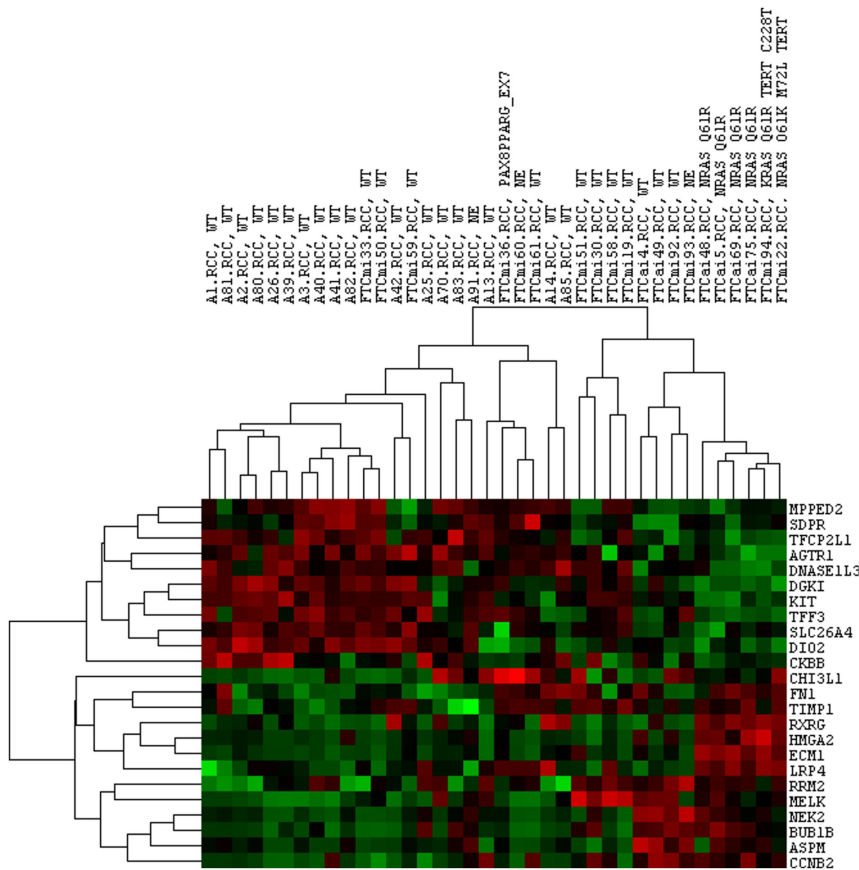
**Unsupervised hierarchical clustering**

Unsupervised hierarchical clustering was performed on DEG normalized data using Pearson’s correlation (*r*). Two main clusters were obtained (Fig. 2): cluster 1 (*r*=0.20) included 24 samples (18 FAs and 6 MI-FTCs), and cluster 2 (*r*=0.17) consisted of 14 samples (8 MI-FTCs and



**Figure 1** Differentially expressed genes. Fas, follicular adenomas; MI-FTCs, minimally invasive follicular thyroid carcinomas; WI-FTCs, widely invasive follicular thyroid carcinomas.





**Figure 2**  
Unsupervised hierarchical clustering. Differentially expressed genes (rows) and samples (columns) were independently clustered by Pearson's correlation ( $r$ ). Red and green equal to high and low expression levels, respectively.

6 WI-FTCs). No correlations were found between MI-FTCs in cluster 1 and MI-FTCs in cluster 2 considering age, size, gender, presence of vascular invasion and degree of capsular invasion (partial or entire thickness). All mutated samples but one (1 MI-FTC harboring a PAX8-PPARG rearrangement) were encompassed in cluster 2.

### 6-gene-based classification

The six DEGs (*ECM1*, *RXRG*, *TIMP1*, *SLC26A4*, *SDPR* and *TFF3*) between MI-FTCs and the other two types of lesions were taken into account to determine the centroids of each histological class (FAs, MI-FTCs and WI-FTCs), and each sample was classified according to the nearest class centroid. By following these criteria, 31/38 samples were appropriately classified (Table 2). A jackknife resampling was then used to cross-validate the results obtained, and 27/38 samples were correctly classified.

### Discussion

In the present study, we performed a molecular characterization of 18 FAs, 14 MI-FTCs and 6 WI-FTCs,

in order to find molecular biomarkers allowing to discriminate among these three types of lesions, which generally deserve a different surgical and therapeutic approach. Firstly, the potential intra-tumor mRNA heterogeneity of MI-FTCs was tested by analyzing five samples in triplicate: the expression profiles obtained from the RNA gathered from the entire tumor, from the invasive foci and from the non-invasive area were very similar ( $r=0.90$ ). The normalized gene expression levels were then used to determine DEGs among FAs, MI-FTCs and WI-FTCs. Twenty-five out of the 75 genes of the panel were differentially expressed (FDR <0.05) between FAs and WI-FTCs (Fig. 1), highlighting a great difference between these lesions, even from a molecular point of view. Five of these genes (*ECM1*, *RXRG*, *SLC26A4*, *SDPR* and *TFF3*) were also differentially expressed between MI-FTCs and WI-FTCs; in particular *ECM1* and *RXRG* were upregulated in WI-FTCs, and *SLC26A4*, *SDPR* and *TFF3* were downregulated. *TIMP1*, upregulated in MI-FTCs vs FAs, was the only differentially expressed gene in this comparison. These results were confirmed by an unsupervised clustering approach, which mirrored the DEG analysis: FAs and WI-FTCs were separated into two different groups, whereas MI-FTCs were split into the two

**Table 2** Six-gene-based classification of samples based on histology compared to age, size, capsule invasion degree, vascular invasion foci, cytological diagnosis (Bethesda system) and genotype.

Sample ID	Histology	Age (years)	Size (mm)	Capsule invasion degree	Vascular invasion foci	Bethesda category	Genotype	Prediction	Probability (%)
FA1	FA	41	35	None	None	III	WT	FA	76
FA13	FA	58	28	None	None	III	WT	FA	65
FA14	FA	19	18	None	None	IV	WT	FA	65
FA2	FA	55	25	None	None	III	WT	FA	82
FA25	FA	35	34	None	None	III	WT	FA	75
FA26	FA	34	18	None	None	IV	WT	MI-FTC	51
FA3	FA	31	44	None	None	IV	WT	FA	78
FA39	FA	50	20	None	None	III	WT	FA	54
FA40	FA	47	50	None	None	III	WT	FA	91
FA41	FA	51	15	None	None	III	WT	FA	63
FA42	FA	53	10	None	None	NA	WT	FA	90
FA70	FA	40	26	None	None	III	WT	FA	79
FA80	FA	41	30	None	None	III	WT	FA	90
FA81	FA	45	36	None	None	III	WT	MI-FTC	88
FA82	FA	49	25	None	None	NA	WT	FA	58
FA83	FA	50	42	None	None	III	WT	FA	81
FA85	FA	40	28	None	None	III	WT	FA	80
FA91	FA	35	52	None	None	NA	WT	FA	100
MI-FTC19	MI-FTC	45	15	Entire	<4	III	WT	MI-FTC	80
MI-FTC22	MI-FTC	64	26	Entire	<4	III	NRAS Q61K NRAS M72L TERT C228T	WI-FTC	75
MI-FTC30	MI-FTC	34	22	Partial	None	IV	WT	MI-FTC	91
MI-FTC33	MI-FTC	59	22	Partial	<4	III	WT	MI-FTC	58
MI-FTC36	MI-FTC	63	34	Partial	<4	NA	PAX8-PPARG ex. 7	MI-FTC	62
MI-FTC50	MI-FTC	45	50	Entire	None	III	WT	MI-FTC	67
MI-FTC51	MI-FTC	69	28	Partial	None	III	WT	MI-FTC	92
MI-FTC58	MI-FTC	55	22	Partial	None	IV	WT	MI-FTC	73
MI-FTC59	MI-FTC	28	18	Entire	<4	IV	WT	MI-FTC	83
MI-FTC60	MI-FTC	42	10	Partial	<4	NA	WT	FA	56
MI-FTC61	MI-FTC	39	18	Entire	None	NA	WT	MI-FTC	84
MI-FTC92	MI-FTC	41	22	Entire	None	III	WT	MI-FTC	74
MI-FTC93	MI-FTC	38	35	Entire	None	NA	WT	FA	63
MI-FTC94	MI-FTC	72	22	Partial	<4	III	KRAS Q61R TERT C228T	WI-FTC	93
WI-FTC4	WI-FTC	63	38	Entire	>4	III	WT	WI-FTC	70
WI-FTC48	WI-FTC	29	15	Entire	<4	III	NRAS Q61R	WI-FTC	100
WI-FTC49	WI-FTC	63	60	Entire	>4	IV	WT	FA	72
WI-FTC5	WI-FTC	53	NA	Entire	>4	NA	NRAS Q61R	WI-FTC	100
WI-FTC69	WI-FTC	77	NA	Entire	>4	V	NRAS Q61R	WI-FTC	100
WI-FTC75	WI-FTC	73	57	Entire	>4	IV	NRAS Q61R	WI-FTC	95

Probability refers to the reliability of classification according to the distance from histological class centroids.

FA, follicular adenoma; MI-FTC, minimally invasive follicular thyroid carcinoma; NA, not available; WI-FTC, widely invasive follicular thyroid carcinoma.

main groups (Fig. 2). However, MI-FTCs that segregated in the two different clusters did not show differences considering age, size, degree of capsule invasion and even presence or absence of vascular invasion. The six genes differentially expressed between MI-FTCs and FAs or WI-FTCs (*ECM1*, *RXRG*, *SLC26A4*, *SDPR*, *TFF3* and *TIMP1*) were then taken into account as a mini-panel, by testing the accuracy of their combination in predicting the histological class of the samples. Following

this approach, 31 samples out of 38 were properly classified (Table 2), and more importantly, the prediction accuracy remained high after cross-validation (27/38). Furthermore, 2 MI-FTCs erroneously classified as WI-FTCs harbored both *RAS* and *TERT* mutations, the coexistence of which is strongly associated with recurrence and mortality (20); consequently, these 2 MI-FTCs should not be considered low-risk lesions, as suggested by the recent ATA guidelines (12). Then, the six-gene classification

seemed able to identify high-risk MI-FTCs that did not show histopathological characteristics useful to stratify these lesions (e.g. diffuse vascular invasion, large size). Although the majority of inaccuracies were FA–MI-FTC misclassification, there was one exception: the WI-FTC classified as FA. This error underlines that the model needs to be further tested in order to evaluate how it could be useful in the clinical practice. Nevertheless, the faithfulness of the panel-based risk-stratification is supported by previous studies (32, 33, 34, 35, 36, 37) describing the biological role of these six genes in cancer progression and associating them with poor prognosis in many cancer models. TIMP1 protein is primarily an inhibitor of secreted and anchored metalloproteinases (38); however, its upregulation has been reported in several cancers, including melanoma, glioblastoma and breast cancer, in which it was also associated with poor prognosis (39, 40, 41). This apparent controversy could be explained by the protease-independent functions (32) and by the weak metalloproteinase-inhibitory capacity compared to other TIMPs (32). So far, TIMP1 expression has not been associated with adverse outcomes in thyroid cancer, but an increased expression with respect to normal tissue or benign lesions has already been described (23, 42). In our series, TIMP1 was also overexpressed in both MI-FTCs and WI-FTCs compared to FAs.

ECM1 is a soluble protein (43) overexpressed in many malignant epithelial tumors including thyroid cancer (33, 44). We found ECM1 to be highly expressed only in WI-FTCs and in the two MI-FTCs harboring both TERT and RAS mutations, highlighting its association with high-risk lesions. In fact, it was demonstrated that ECM1 is actively involved in promoting the Warburg effect (45) and angiogenesis (46) and, accordingly, that it is also associated with poor prognosis (33). RXRG encodes for a member of the retinoid X receptor family (47). This isoform was expressed similarly to ECM1, with few exceptions, confirming a previously reported high expression in thyroid cancer compared to normal thyroid cells (34). Interestingly, treatment with retinoids showed thyroid tumor growth suppression *in vitro*, especially in those expressing  $\gamma$  isoform (34). TFF3 is a secretory protein of the trefoil family (48). Although it is overexpressed and also correlates with poor prognosis in many cancer models (49, 50), we reported a downregulation of TFF3. However, this is in agreement with many studies that clearly demonstrated a lower expression of TFF3 in thyroid cancer with respect to normal tissue and benign lesions (22, 42, 51). Moreover, the forced expression of TFF3 in transfected anaplastic thyroid cancer cells restored

an epithelial-like cell morphology and the expression of differentiation markers of follicular thyroid cells (35). SDPR is a phospholipid-binding protein that is over-expressed in serum-starved cells (52). SDPR downregulation was previously described in thyroid cancer (24) as well as in our series; the same trend was also reported in breast, kidney and prostate cancer (53). Furthermore, functional studies in breast cancer highlighted an important role of SDPR in apoptosis promotion (36) and in the suppression of the epithelial–mesenchymal transition (54). Lastly, SLC26A4 encodes for pendrin, a chloride–iodide transporter associated with the Pendred syndrome (55). SLC26A4 mRNA and pendrin levels are both considerably lower in thyroid cancer than those in the follicular cells of normal tissue or in benign thyroid tumors (24, 56). Pendrin, normally expressed at the apical pole of thyrocytes, is located in the intracellular compartments of the DTC majority (56). Despite the lack of evidence of association between SLC26A4 expression and poor prognosis in thyroid cancer, we reported a downregulation of this gene only in widely invasive carcinomas. However, low levels of SLC26A4 mRNA were associated with papillary thyroid cancer that failed to uptake  $^{131}\text{I}$  (37). In conclusion, even if we are fully aware that follicular-patterned tumors also encompass the follicular variant of papillary thyroid carcinoma, in this preliminary study, we focused on FA and FTC. Herein, we present a small panel of genes able to stratify benign, low- and high-risk lesions. Although the validation in a larger cohort of cases and through long-term follow-up is needed, our data provide some points that deserve further investigations: (a) since lesions carrying TERT promoter mutations have gene expression profiles very similar to those of WI-FTCs, these alterations could be useful markers for stratifying MI-FTCs prognosis; (b) gene expression and this six-gene model have the potential to support the diagnosis of indeterminate nodules. In fact, the gene expression levels of selected genes seemed promising not only in differentiating benign from malignant lesions, which can rarely be distinguished by FNAC, but also in differentiating between low- and high-risk malignant lesions, providing further information that could be useful in the surgical and therapeutic approach.

#### Supplementary data

This is linked to the online version of the paper at <https://doi.org/10.1530/EC-17-0261>.

#### Declaration of interest

The authors declare that there is no conflict of interest that could be perceived as prejudicing the impartiality of the research reported.



### Funding

This work was supported by AIRC (IG\_10316\_2010), PRA (PRA\_2016\_19) and PRIN (2015HPMLFY).

### References

- LiVolsi VA & Asa SL. The demise of follicular carcinoma of the thyroid gland. *Thyroid* 1994 **4** 233–236. (<https://doi.org/10.1089/thy.1994.4.233>)
- Goffredo P, Cheung K, Roman SA & Sosa JA. Can minimally invasive follicular thyroid cancer be approached as a benign lesion? A population-level analysis of survival among 1200 patients. *Annals of Surgical Oncology* 2013 **20** 767–772. (<https://doi.org/10.1245/s10434-012-2697-4>)
- DeLellis RA, Lloyd RV, Heitz PU & Eng C. *WHO Classification of Tumours. Pathology and Genetics of Tumours of Endocrine Organs*. Lyon, France: IARC, 2004.
- LiVolsi VA & Baloch ZW. Follicular-patterned tumors of the thyroid: the battle of benign vs. malignant vs. so-called uncertain. *Endocrine Pathology* 2011 **22** 184–189. (<https://doi.org/10.1007/s12022-011-9183-6>)
- Siegel R, Ma J, Zou Z & Jemal A. Cancer statistics, 2014. *CA: A Cancer Journal for Clinicians* 2014 **64** 9–29. (<https://doi.org/10.3322/caac.21208>)
- D'Avanzo A, Treseler P, Ituarte PHG, Wong M, Streja L, Greenspan FS, Siperstein AE, Duh QY & Clark OH. Follicular thyroid carcinoma: histology and prognosis. *Cancer* 2004 **100** 1123–1129. (<https://doi.org/10.1002/cncr.20081>)
- Yamashina M. Follicular neoplasms of the thyroid. Total circumferential evaluation of the fibrous capsule. *American Journal of Surgical Pathology* 1992 **16** 392–400. (<https://doi.org/10.1097/00000478-199204000-00008>)
- van Heerden JA, Hay ID, Goellner JR, Salomao D, Ebersold JR, Bergstralh EJ & Grant CS. Follicular thyroid carcinoma with capsular invasion alone: a nonthreatening malignancy. *Surgery* 1992 **112** 1130–1138.
- Kim HJ, Sung J-Y, Oh YL, Kim JH, Son Y-I, Min Y-K, Kim SW & Chung JH. Association of vascular invasion with increased mortality in patients with minimally invasive follicular thyroid carcinoma but not widely invasive follicular thyroid carcinoma. *Head and Neck* 2014 **36** 1695–1700. (<https://doi.org/10.1002/hed.23511>)
- Ito Y, Hirokawa M, Miyauchi A, Masuoka H, Yabuta T, Fukushima M, Kihara M, Higashiyama T, Kobayashi K & Miya A. Prognostic impact of Ki-67 labeling index in minimally invasive follicular thyroid carcinoma. *Endocrine Journal* 2016 **63** 913–917. (<https://doi.org/10.1507/endocrj.EJ16-0277>)
- Lee Y-M, Song DE, Kim TY, Sung T-Y, Yoon JH, Chung K-W & Hong SJ. Risk factors for distant metastasis in patients with minimally invasive follicular thyroid carcinoma. *PLoS ONE* 2016 **11** e0155489. (<https://doi.org/10.1371/journal.pone.0155489>)
- Haugen BR, Alexander EK, Bible KC, Doherty GM, Mandel SJ, Nikiforov YE, Pacini F, Randolph GW, Sawka AM, Schlumberger M, et al. 2015 American Thyroid Association Management Guidelines for adult patients with thyroid nodules and differentiated thyroid cancer: the American Thyroid Association Guidelines task force on thyroid nodules and differentiated thyroid cancer. *Thyroid* 2016 **26** 1–133. (<https://doi.org/10.1089/thy.2015.0020>)
- Heffess CS & Thompson LD. Minimally invasive follicular thyroid carcinoma. *Endocrine Pathology* 2001 **12** 417–422. (<https://doi.org/10.1385/EP:12:4:417>)
- Thompson LD, Wieneke JA, Paal E, Frommelt RA, Adair CF & Heffess CS. A clinicopathologic study of minimally invasive follicular carcinoma of the thyroid gland with a review of the English literature. *Cancer* 2001 **91** 505–524. ([https://doi.org/10.1002/1097-0142\(20010201\)91:3<505::AID-CNCR1029>3.0.CO;2-6](https://doi.org/10.1002/1097-0142(20010201)91:3<505::AID-CNCR1029>3.0.CO;2-6))
- Ban EJ, Andrabi A, Grodski S, Yeung M, McLean C & Serpell J. Follicular thyroid cancer: minimally invasive tumours can give rise to metastases. *ANZ Journal of Surgery* 2012 **82** 136–139. (<https://doi.org/10.1111/j.1445-2197.2011.05979.x>)
- Asari R, Koperek O, Scheuba C, Riss P, Kaserer K, Hoffmann M & Niederle B. Follicular thyroid carcinoma in an iodine-replete endemic goiter region: a prospectively collected, retrospectively analyzed clinical trial. *Annals of Surgery* 2009 **249** 1023–1031. (<https://doi.org/10.1097/SLA.0b013e3181a77b7b>)
- Huang C-C, Hsueh C, Liu F-H, Chao T-C & Lin J-D. Diagnostic and therapeutic strategies for minimally and widely invasive follicular thyroid carcinomas. *Surgical Oncology* 2011 **20** 1–6. (<https://doi.org/10.1016/j.suronc.2009.06.006>)
- Liu X, Bishop J, Shan Y, Pai S, Liu D, Murugan AK, Sun H, El-Naggar AK & Xing M. Highly prevalent TERT promoter mutations in aggressive thyroid cancers. *Endocrine-Related Cancer* 2013 **20** 603–610. (<https://doi.org/10.1530/ERC-13-0210>)
- Melo M, da Rocha AG, Vinagre J, Batista R, Peixoto J, Tavares C, Celestino R, Almeida A, Salgado C, Eloy C, et al. TERT promoter mutations are a major indicator of poor outcome in differentiated thyroid carcinomas. *Journal of Clinical Endocrinology and Metabolism* 2014 **99** E754–E765. (<https://doi.org/10.1210/jc.2013-3734>)
- Song YS, Lim JA, Choi H, Won J-K, Moon JH, Cho SW, Lee KE, Park YJ, Yi KH, Park DJ, et al. Prognostic effects of TERT promoter mutations are enhanced by coexistence with BRAF or RAS mutations and strengthen the risk prediction by the ATA or TNM staging system in differentiated thyroid cancer patients. *Cancer* 2016 **122** 1370–1379. (<https://doi.org/10.1002/cncr.29934>)
- Yoo S-K, Lee S, Kim S-J, Jee H-G, Kim B-A, Cho H, Song YS, Cho SW, Won JK, Shin JY, et al. Comprehensive analysis of the transcriptional and mutational landscape of follicular and papillary thyroid cancers. *PLoS Genetics* 2016 **12** e1006239. (<https://doi.org/10.1371/journal.pgen.1006239>)
- Barden CB, Shister KW, Zhu B, Guiter G, Greenblatt DY, Zeiger MA & Fahey TJ 3rd. Classification of follicular thyroid tumors by molecular signature: results of gene profiling. *Clinical Cancer Research* 2003 **9** 1792–1800.
- Finley DJ, Zhu B, Barden CB & Fahey TJ. Discrimination of benign and malignant thyroid nodules by molecular profiling. *Annals of Surgery* 2004 **240** 425–437. (<https://doi.org/10.1097/01.sla.0000137128.64978.bc>)
- Borup R, Rossing M, Henao R, Yamamoto Y, Krogdahl A, Godballe C, Winther O, Kiss K, Christensen L, Høgdall E, et al. Molecular signatures of thyroid follicular neoplasia. *Endocrine-Related Cancer* 2010 **17** 691–708. (<https://doi.org/10.1677/ERC-09-0288>)
- Nikiforov YE, Steward DL, Robinson-Smith TM, Haugen BR, Klopper JP, Zhu Z, Fagin JA, Falciglia M, Weber K & Nikiforova MN. Molecular testing for mutations in improving the fine-needle aspiration diagnosis of thyroid nodules. *Journal of Clinical Endocrinology and Metabolism* 2009 **94** 2092–2098. (<https://doi.org/10.1210/jc.2009-0247>)
- Giannini R, Ugolini C, Poma AM, Urpi M, Niccoli C, Elisei R, Chiarugi M, Vitti P, Miccoli P & Basolo F. Identification of two distinct molecular subtypes by digital RNA counting of 'non-invasive follicular tumour with papillary-like nuclear features (NIFTP)'. *Thyroid* 2017 **10** 1267–1276. (<https://doi.org/10.1089/thy.2016.0605>)
- Ritchie ME, Phipson B, Wu D, Hu Y, Law CW, Shi W & Smyth GK. limma powers differential expression analyses for RNA-seq and microarray studies. *Nucleic Acids Research* 2015 **43** e47. (<https://doi.org/10.1093/nar/gkv007>)
- Law CW, Chen Y, Shi W & Smyth GK. voom: precision weights unlock linear model analysis tools for RNA-seq read counts. *Genome Biology* 2014 **15** R29. (<https://doi.org/10.1186/gb-2014-15-2-r29>)
- Bendl J, Stourac J, Salanda O, Pavelka A, Wieben ED, Zendlulka J, Brezovsky J & Damborsky J. PredictSNP: robust and accurate consensus classifier for prediction of disease-related mutations. *PLoS Computational Biology* 2014 **10** e1003440. (<https://doi.org/10.1371/journal.pcbi.1003440>)





- 30 Cibas ES & Ali SZ. NCI thyroid FNA state of the science conference. The Bethesda system for reporting thyroid cytopathology. *American Journal of Clinical Pathology* 2009 **132** 658–665. (<https://doi.org/10.1309/AJCPPHLMW13JV4LA>)
- 31 Giannini R, Torregrossa L, Gottardi S, Fregoli L, Borrelli N, Savino M, Macerola E, Vitti P, Miccoli P & Basolo F. Digital gene expression profiling of a series of cytologically indeterminate thyroid nodules. *Cancer Cytopathology* 2015 **123** 461–470. (<https://doi.org/10.1002/cncy.21564>)
- 32 Jackson HW, Defamie V, Waterhouse P & Khokha R. TIMPs: versatile extracellular regulators in cancer. *Nature Reviews Cancer* 2017 **17** 38–53. (<https://doi.org/10.1038/nrc.2016.115>)
- 33 Wang L, Yu J, Ni J, Xu X-M, Wang J, Ning H, Pei XF, Chen J, Yang S, Underhill CB, et al. Extracellular matrix protein 1 (ECM1) is over-expressed in malignant epithelial tumors. *Cancer Letters* 2003 **200** 57–67. ([https://doi.org/10.1016/S0304-3835\(03\)00350-1](https://doi.org/10.1016/S0304-3835(03)00350-1))
- 34 Haugen BR, Larson LL, Pugazhenth U, Hays WR, Klopper JP, Kramer CA & Sharma V. Retinoic acid and retinoid X receptors are differentially expressed in thyroid cancer and thyroid carcinoma cell lines and predict response to treatment with retinoids. *Journal of Clinical Endocrinology and Metabolism* 2004 **89** 272–280. (<https://doi.org/10.1210/jc.2003-030770>)
- 35 Abols A, Ducena K, Andrejeva D, Sadovska L, Zandberga E, Vilmanis J, Narbutis Z, Tars J, Eglitis J, Pirags V, et al. Trefoil factor 3 is required for differentiation of thyroid follicular cells and acts as a context-dependent tumor suppressor. *Neoplasia* 2015 **62** 914–924. ([https://doi.org/10.4149/neo\\_2015\\_111](https://doi.org/10.4149/neo_2015_111))
- 36 Ozturk S, Papageorgis P, Wong CK, Lambert AW, Abdolmaleky HM, Thiagalingam A, Cohen HT & Thiagalingam S. SDPR functions as a metastasis suppressor in breast cancer by promoting apoptosis. *PNAS* 2016 **113** 638–643. (<https://doi.org/10.1073/pnas.1514663113>)
- 37 Mian C, Barollo S, Pennelli G, Pavan N, Rugge M, Pelizzo MR, Mazzarotto R, Casara D, Nacamulli D, Mantero F, et al. Molecular characteristics in papillary thyroid cancers (PTCs) with no 131I uptake. *Clinical Endocrinology* 2008 **68** 108–116. (<https://doi.org/10.1111/j.1365-2265.2007.03008.x>)
- 38 Amour A, Knight CG, Webster A, Slocombe PM, Stephens PE, Knäuper V, Docherty AJ & Murphy G. The in vitro activity of ADAM-10 is inhibited by TIMP-1 and TIMP-3. *FEBS Letters* 2000 **473** 275–279. ([https://doi.org/10.1016/S0014-5793\(00\)01528-3](https://doi.org/10.1016/S0014-5793(00)01528-3))
- 39 Zurac S, Neagu M, Constantin C, Cioplea M, Nedelcu R, Bastian A, Popp C, Nichita L, Andrei R, Tebeica T, et al. Variations in the expression of TIMP1, TIMP2 and TIMP3 in cutaneous melanoma with regression and their possible function as prognostic predictors. *Oncology Letters* 2016 **11** 3354–3360. (<https://doi.org/10.3892/ol.2016.4391>)
- 40 Dechaphunkul A, Phuakoloun M, Kanjanapradit K, Graham K, Ghosh S, Santos C & Mackey JR. Prognostic significance of tissue inhibitor of metalloproteinase-1 in breast cancer. *International Journal of Breast Cancer* 2012 **2012** 290854. (<https://doi.org/10.1155/2012/290854>)
- 41 Aaberg-Jessen C, Christensen K, Offenberg H, Bartels A, Dreehsen T, Hansen S, Schröder HD, Brünner N & Kristensen BW. Low expression of tissue inhibitor of metalloproteinases-1 (TIMP-1) in glioblastoma predicts longer patient survival. *Journal of Neuro-Oncology* 2009 **95** 117–128. (<https://doi.org/10.1007/s11060-009-9910-8>)
- 42 Griffith OL, Melck A, Jones SJM & Wiseman SM. Meta-analysis and meta-review of thyroid cancer gene expression profiling studies identifies important diagnostic biomarkers. *Journal of Clinical Oncology* 2006 **24** 5043–5051. (<https://doi.org/10.1200/JCO.2006.06.7330>)
- 43 Mathieu E, Meheus L, Raymackers J & Merregaert J. Characterization of the osteogenic stromal cell line MN7: identification of secreted MN7 proteins using two-dimensional polyacrylamide gel electrophoresis, western blotting, and microsequencing. *Journal of Bone and Mineral Research* 1994 **9** 903–913. (<https://doi.org/10.1002/jbmr.5650090616>)
- 44 Schulten H-J, Al-Mansouri Z, Baghallab I, Bagatian N, Subhi O, Karim S, Al-Aradati H, Al-Mutawa A, Johary A, Meccawy AA, et al. Comparison of microarray expression profiles between follicular variant of papillary thyroid carcinomas and follicular adenomas of the thyroid. *BMC Genomics* 2015 **16** (Supplement 1) S7. (<https://doi.org/10.1186/1471-2164-16-S1-S7>)
- 45 Lee K-M, Nam K, Oh S, Lim J, Lee T & Shin I. ECM1 promotes the Warburg effect through EGF-mediated activation of PKM2. *Cellular Signalling* 2015 **27** 228–235. (<https://doi.org/10.1016/j.cellsig.2014.11.004>)
- 46 Han Z, Ni J, Smits P, Underhill CB, Xie B, Chen Y, Liu N, Tylzanowski P, Parmelee D, Feng P, et al. Extracellular matrix protein 1 (ECM1) has angiogenic properties and is expressed by breast tumor cells. *FASEB Journal* 2001 **15** 988–994.
- 47 Almasan A, Mangelsdorf DJ, Ong ES, Wahl GM & Evans RM. Chromosomal localization of the human retinoid X receptors. *Genomics* 1994 **20** 397–403. (<https://doi.org/10.1006/geno.1994.1193>)
- 48 Schmitt H, Wundrack I, Beck S, Gött P, Welter C, Shizuya H, Simon MI & Blin N. A third P-domain peptide gene (TFF3), human intestinal trefoil factor, maps to 21q22.3. *Cytogenetic and Genome Research* 1996 **72** 299–302. (<https://doi.org/10.1159/000134208>)
- 49 Meng J-R, Tang H-Z, Zhou K-Z, Shen W-H & Guo H-Y. TFF3 and survivin expressions associate with a lower survival rate in gastric cancer. *Clinical and Experimental Medicine* 2013 **13** 297–303. (<https://doi.org/10.1007/s10238-012-0210-9>)
- 50 Yuan Z, Chen D, Chen X, Yang H & Wei Y. Overexpression of trefoil factor 3 (TFF3) contributes to the malignant progression in cervical cancer cells. *Cancer Cell International* 2017 **17** 7. (<https://doi.org/10.1186/s12935-016-0379-1>)
- 51 Huang Y, Prasad M, Lemon WJ, Hampel H, Wright FA, Kornacker K, LiVolsi V, Frankel W, Kloos RT, Eng C, et al. Gene expression in papillary thyroid carcinoma reveals highly consistent profiles. *PNAS* 2001 **98** 15044–15049. (<https://doi.org/10.1073/pnas.251547398>)
- 52 Gustinich S & Schneider C. Serum deprivation response gene is induced by serum starvation but not by contact inhibition. *Cell Growth and Differentiation* 1993 **4** 753–760.
- 53 Li X, Jia Z, Shen Y, Ichikawa H, Jarvik J, Nagele RG & Goldberg GS. Coordinate suppression of Sdpr and Fhl1 expression in tumors of the breast, kidney, and prostate. *Cancer Science* 2008 **99** 1326–1333. (<https://doi.org/10.1111/j.1349-7006.2008.00816.x>)
- 54 Tian Y, Yu Y, Hou L-K, Chi J-R, Mao J-F, Xia L, Wang X, Wang P & Cao XC. Serum deprivation response inhibits breast cancer progression by blocking transforming growth factor- $\beta$  signaling. *Cancer Science* 2016 **107** 274–280. (<https://doi.org/10.1111/cas.12879>)
- 55 Scott DA, Wang R, Kreman TM, Sheffield VC & Karniski LP. The Pendred syndrome gene encodes a chloride-iodide transport protein. *Nature Genetics* 1999 **21** 440–443. (<https://doi.org/10.1038/7783>)
- 56 Skubis-Zegadło J, Nikodemka A, Przytuła E, Mikula M, Bardadin K, Ostrowski J, Wenzel BE & Czarnocka B. Expression of pendrin in benign and malignant human thyroid tissues. *British Journal of Cancer* 2005 **93** 144–151. (<https://doi.org/10.1038/sj.bjc.6602628>)

Received in final form 6 November 2017

Accepted 27 November 2017

