

OTOLOGY SECTION

Current trends on subtotal petrosectomy with cochlear implantation in recalcitrant chronic middle ear disorders

Attualità in tema di petrosectomia subtotale con impianto cocleare nelle patologie croniche dell'orecchio medio recalcitranti

Pietro Canzi^{1,2}, Stefano Berrettini³, Andrea Albera⁴, Maurizio Barbara⁵, Luca Bruschini³, Andrea Canale⁴, Elena Carlotto², Edoardo Covelli⁶, Domenico Cuda⁶, Francesco Dispenza⁷, Maurizio Falcioni⁸, Francesca Forli³, Sebastiano Franchella⁹, Lorenzo Gaini¹⁰, Salvatore Gallina⁷, Andrea Laboral⁶, Ruggero Lapenna¹¹, Francesco Lazzerini³, Stefano Malpede², Marco Mandalà¹², Domenico Minervini², Enrico Pasanisi⁸, Giampietro Ricci¹¹, Francesca Viberti¹², Diego Zanetti^{13,14}, Elisabetta Zanoletti⁹, Marco Benazzo^{1,2}

¹ Department of Clinical, Surgical, Diagnostic and Pediatric Sciences, University of Pavia, Pavia, Italy; ² Department of Otorhinolaryngology, University of Pavia, Fondazione IRCCS Policlinico San Matteo, Pavia, Italy; ³ Otolaryngology, Audiology and Phoniatrics Unit, University of Pisa, Pisa, Italy; ⁴ Division of Otorhinolaryngology, Department of Surgical Sciences, University of Turin, Turin, Italy; ⁵ Department of Neuroscience, Mental Health and Sensory Organs, Faculty of Medicine and Psychology, Sapienza University, Rome, Italy; ⁶ Department of Otolaryngology, Guglielmo da Saliceto Hospital, Piacenza, Italy; ⁷ Department of Biomedicine, Neuroscience and Advanced Diagnostics, Azienda Ospedaliera Universitaria Policlinico "Paolo Giaccone", University of Palermo, Palermo, Italy; ⁸ Otorhinolaryngology and Otoneurosurgery Department, University Hospital of Parma, Italy; ⁹ Department of Neuroscience DNS, Otolaryngology Section, Padova University, Padova, Italy; ¹⁰ Department of Otolaryngology and Head and Neck Surgery, Fondazione IRCCS Ca' Granda Ospedale Maggiore Policlinico, Milan, Italy; ¹¹ Department of Surgical and Biomedical Sciences, Section of Otorhinolaryngology, University of Perugia, Perugia, Italy; ¹² Department of Otolaryngology and Skull Base Surgery, Azienda Ospedaliera Universitaria Senese, Siena, Italy; ¹³ Audiology Unit, Department of Specialistic Surgical Sciences Fondazione IRCCS Ca' Granda, Ospedale Maggiore Policlinico Milan, Italy; ¹⁴ Department of Clinical Sciences and Community Health University of Milan, Milan, Italy

SUMMARY

Objective. To establish the safety and effectiveness of subtotal petrosectomy with cochlear implantation in patients affected by chronic middle ear disorders to refractory to previous surgical treatments.

Methods. A multicentre, retrospective study was conducted on patients affected by recalcitrant chronic middle ear disorders who underwent cochlear implantation in combination with subtotal petrosectomy. Patients' details were collected from databases of 11 Italian tertiary referral centres. Additionally, a review of the most updated literature was carried out.

Results. 55 patients were included with a mean follow-up time of 44 months. Cholesteatoma was the most common middle ear recurrent pathology and 50.9% of patients had an open cavity. 80% of patients underwent a single stage surgery. One case of explantation for device failure was reported among the 7 patients with post-operative complications.

Conclusions. Subtotal petrosectomy with cochlear implantation is a benchmark for management of patients with recalcitrant chronic middle ear disorders. A single stage procedure is the most recommended strategy. Optimal follow-up is still debated. Further studies are required to investigate the role of this surgery in paediatric patients.

KEY WORDS: subtotal petrosectomy, cochlear implant, cochlear implantation, chronic otitis media, chronic middle ear disorders, recalcitrant, refractory, recurrent

RIASSUNTO

Obiettivo. Stabilire la sicurezza ed efficacia dell'intervento di petrosectomia subtotale con posizionamento di impianto cocleare nei pazienti affetti da patologia cronica dell'orecchio medio refrattaria a precedenti trattamenti chirurgici.

Metodi. È stato svolto uno studio retrospettivo multicentrico riguardante quei pazienti affetti da patologie croniche dell'orecchio medio recalcitranti, sottoposti a petrosectomia

Received: January 9, 2023

Accepted: January 17, 2023

Correspondence

Stefano Malpede

University of Pavia, Department of Otorhinolaryngology, IRCCS Policlinico San Matteo Foundation, viale C. Golgi 19, 27100 Pavia, Italy
 Fax +39 0382 503668
 E-mail: stefano.malpede01@universitadipavia.it

How to cite this article: Canzi P, Berrettini S, Albera A, et al. Current trends on subtotal petrosectomy with cochlear implantation in recalcitrant chronic middle ear disorders. Acta Otorhinolaryngol Ital 2023;43(SUPPL.1):S67-S75. <https://doi.org/10.14639/0392-100X-suppl.1-43-2023-09>

© Società Italiana di Otorinolaringoiatria e Chirurgia Cervico-Facciale



OPEN ACCESS

This is an open access article distributed in accordance with the CC-BY-NC-ND (Creative Commons Attribution-NonCommercial-NoDerivatives 4.0 International) license. The article can be used by giving appropriate credit and mentioning the license, but only for non-commercial purposes and only in the original version. For further information: <https://creativecommons.org/licenses/by-nc-nd/4.0/deed.en>

subtotale con posizionamento di impianto cocleare. Le informazioni sono state raccolte dai database di 11 centri di riferimento di III livello in Italia. A complemento, è stata svolta una revisione della più recente letteratura.

Risultati. Nello studio sono stati inclusi 55 pazienti con un follow-up medio di 44 mesi. Il colesteatoma ha rappresentato la più comune patologia ricorrente dell'orecchio medio e il 50,9% dei pazienti aveva una cavità aperta. L'80% dei pazienti è stato sottoposto ad una chirurgia a singolo stadio. Sette pazienti hanno mostrato complicanze post-operatorie, di cui un caso di espianto.

Conclusioni. L'intervento di petrosectomia subtotale con posizionamento di impianto cocleare rappresenta una tecnica chirurgica di riferimento per la gestione dei pazienti affetti da otite media cronica recalcitrante. L'intervento chirurgico a singolo stadio è la strategia più frequentemente raccomandata. Il follow-up ottimale è ancora ad oggi oggetto di dibattito. Sono richiesti ulteriori studi per stabilire il ruolo di questo intervento nei pazienti pediatrici.

PAROLE CHIAVE: *petrosectomia subtotale, impianto cocleare, otite media cronica, patologie croniche dell'orecchio medio, recalcitrante, refrattario, ricorrente*

Introduction

In the era of “minimally-invasive surgery”, the increasing popularity of subtotal petrosectomy (SP) in patients addressed to cochlear implantation may appear anachronistic and outdated. Since its first description about 40 years ago^{1,2}, SP has been historically proposed for challenging cases as an “end-stage procedure”. SP provides a safe field thanks to the closure of the external auditory canal (EAC) and eustachian tube, after meticulous removal of temporal bone air cells and mastoid cavity obliteration¹. Why is the recent literature increasingly focusing on this surgical technique? The answer relies on the opportunity to eradicate middle ear disorders recalcitrant to previous therapeutic attempts and to simultaneously restore the impaired hearing. Nowadays, patients previously considered unfit for cochlear implantation and patients addressed to high-risk surgical procedures may receive a well-established approach, namely SP, with a lower percentage of adverse events³. The aim of the present work was to analyse the role of SP with cochlear implantation in chronic middle ear disorders recalcitrant to previous treatments in a multicentre retrospective case series. Results were compared with literature findings of the last 12 years.

Materials and methods

A national multicentre, retrospective study was conducted on patients affected by chronic middle ear disorders who underwent SP and cochlear implantation after performing one or more previous middle ear surgeries. SP was defined according to description of Fisch et al. in 1988¹. Patient data were collected from the Cochlear implant (COI) databases of 11 tertiary referral centres between January 2005 and November 2022. Personal data, pathological, audiological, surgical history and indications were collected. Further details about surgery, complications and follow-up examinations were included. Complications were classified according to the consensus proposed by Hansen et al.⁴ All patients underwent otological examination and pure-tone pre-operative audiological assessment was available in all cases. Pure tone average

(PTA, average of 0.5-1-2-4 kHz), minimum, maximum values and standard deviation (SD) were calculated. Functional gain PTA (calculated as the difference between the post-operative PTA and the pre-operative PTA) was also assessed. Pre-operative study included high-resolution computed tomography (HRCT) and gadolinium-enhanced magnetic resonance imaging (MRI). Post-operative audiological data were collected at 1, 3, 6 and 12 months after surgery. Post-operative HRCT was performed if needed.

Review of literature

A narrative review of the literature was conducted using PubMed. Our aim was to identify publications in which patients, affected by chronic middle ear disorders and a previous history of middle ear surgery, were submitted to COI in combination with SP because of disease recurrence. “Subtotal petrosectomy”, “middle ear obliteration” and “cochlear implant” were used as key words. Only English articles were included, while case reports, case series, non-English articles and studies published before 2010 were excluded. Papers published by Free et al.⁵, Polo et al.⁶, and Vashishth et al.⁷, met our inclusion criteria, and were not included due to a possible overlap of patients with the latest study published by Grinblat et al.³. Data were retrieved from information available from the text and tables presented in each article. All included patients submitted to COI and SP had history of a previous middle ear surgical procedure. Cases in which the middle ear was explicitly referred as dry or non-discharging were excluded. Patients for whom information about the pathological course was not available were included. Thus, we intended to exclude patients in which the indication for COI and SP was purely audiological and was not supported by a history of recalcitrant chronic middle ear disorder.

Results

A total of 55 ears in 55 patients were included. Twenty-five were males (45.5%) and 30 were females (54.5%); the mean age at surgery was 61.6 years (range, 10-82 years).

Only one paediatric patient was included in the study. Mean follow-up time was 44 months (range, 1-132 months).

Pathological and surgical history

All patients included in our series were affected by a chronic middle ear disease, had been submitted to a previous middle ear surgery, and experienced disease recurrence. Under the terms “chronic middle ear disorders” we included: chronic simple otitis media (COM), chronic suppurative otitis media (CSOM) and chronic otitis media with cholesteatoma (CCOM). In our series, CCOM was the most common middle ear recurrent pathology accounting for 28 cases (50.9%), whereas 10 patients were affected by COM (18.2%) and 17 suffered from CSOM (30.9%). Twenty-seven patients (49.1%) had a history of a previous canal wall up tympanoplasty (TPL CWU); in 28 cases an open cavity was present, including 25 (45.4%) canal wall down tympanoplasties (TPL CWD) and 3 (5.4%) radical cavities. Information about contralateral ear surgical status was also available. In 20 patients (36.4%) there was a history of previous middle ear surgery

(TPL CWU, TPL CWD or radical cavity), 2 cases (3.6%) had a contralateral COI, and the remaining 33 patients (60%) did not undergo any surgical intervention on the contralateral ear (Tab. I). The presence of a concomitant nasal pathology was investigated; five of the 55 patients (9.1%) suffered from chronic rhinosinusitis with or without nasal polyposis.

Pre-operative and post-operative audiological assessment

All patients included were affected by severe to profound sensorineural hearing loss. Pre-operative mean PTA at pure-tone audiometry was 114 dB HL (range, 85-120 dB HL; SD \pm 9.3). Fifteen patients (27.3%) were conventional hearing aid users whereas 40 patients (72.7%) did not use or did not benefit from the use of a hearing aid.

Contralateral ear audiological status assessment highlighted a mean PTA for air conducted sounds of 82.3 dB HL (range 35-120 dB HL; SD \pm 25.13). Mean PTA for bone conducted sounds was not calculated for the presence of a large variety of hearing disorders. Post-operative results showed a mean PTA at 6 months after COI surgery

Table I. Demographics, clinical indications and surgical history.

Author, year	Cases	Ears	Age at surgery (average)	Sex	Chronic middle ear disorders			Previous surgery			Contralateral ear surgical history
					COM	CSOM	CCOM	TPL CWU	TPL CWD	Radical cavity	
Baranano et al. 2013 ⁸	7	7	59.9 yrs*	N/A	N/A	N/A	N/A	N/A	2	N/A	N/A
Vincenti et al. 2014 ⁹	9	9	48.3 yrs	F – 5, M – 4	N/A	N/A	N/A	N/A	N/A	N/A	Stable mastoid cavity – 5 ears
Bernardeschi et al. 2015 ¹⁰	4	4	65 yrs	N/A	N/A	1	2	N/A	1	N/A	SP + CI – 1 ear
Casserly et al. 2016 ¹¹	2	2	N/A	N/A	N/A	N/A	N/A	N/A	2	N/A	N/A
Szymanski et al. 2016 ¹²	9	9	70.7 yrs*	F – 7, M – 2	N/A	N/A	N/A	2	7	0	N/A
Altuna et al. 2017 ¹³	3	3	61.3 yrs*	M – 3	N/A	N/A	1	0	3	0	N/A
D'Angelo et al. 2020 ¹⁴	7	7	57 yrs*	F – 4, M – 3	N/A	N/A	N/A	3	3	1	N/A
Kurkure et al. 2020 ¹⁵	7	7	N/A	N/A	N/A	N/A	N/A	0	7	0	N/A
Yoon et al. 2020 ¹⁶	3	3	62 yrs*	F – 2, M – 1	0	3	0	0	3	0	N/A
Lee et al. 2020 ¹⁷	2	2	62.5 yrs	F – 1, M – 1	0	2	0	0	2	0	N/A
Grinblat et al. 2020 ³	39	39	56.8 yrs*	F – N/A, M – 3	N/A	N/A	4	11	9	19	N/A
Zhang et al. 2021 ¹⁸	11	11	53.3 yrs*	N/A	7	N/A	4	1	10	0	N/A
Present study	55	55	61.6 yrs	F – 30, M – 25	10	17	28	27	25	3	<ul style="list-style-type: none"> • TPL CWU, TPL CWD, radical cavity – 20 ears • Contralateral COI – 2 ears • No surgery – 33 ears

CCOM: Chronic Otitis Media with Cholesteatoma; COI: Cochlear Implant; COM: Chronic simple Otitis Media; CSOM: Chronic Suppurative Otitis Media; F: female; M: male; N/A: Not Available; SP: Subtotal Petrosectomy; TPL CWD: Canal Wall Down Tympanoplasty; TPL CWU: Canal Wall Up Tympanoplasty; *: average value of the whole population of the study, not specific for the listed cases.

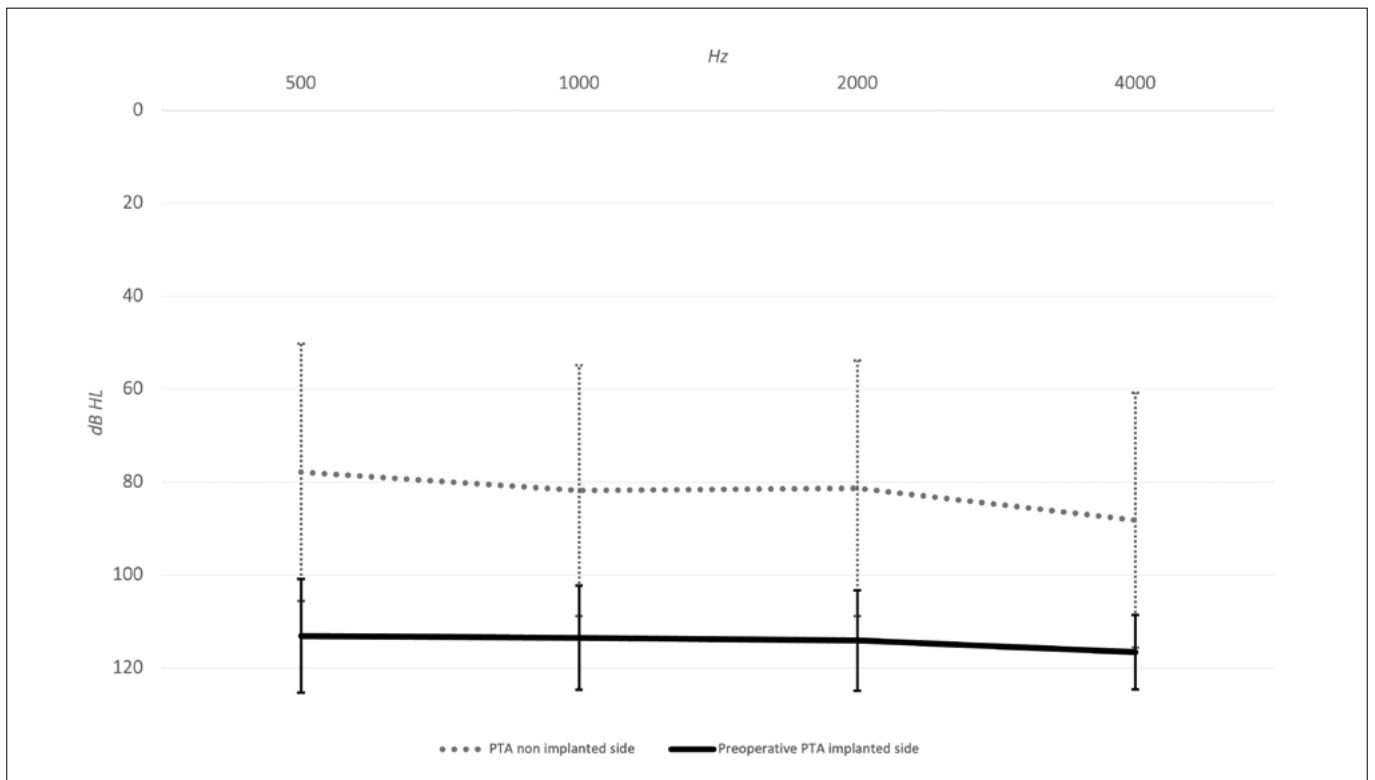


Figure 1. Pre-operative pure tone audiometry. Graphic depiction of PTA for each frequency for both implanted and non-implanted side. Horizontal lines represent PTA trending line, while vertical lines represent SD for each frequency.

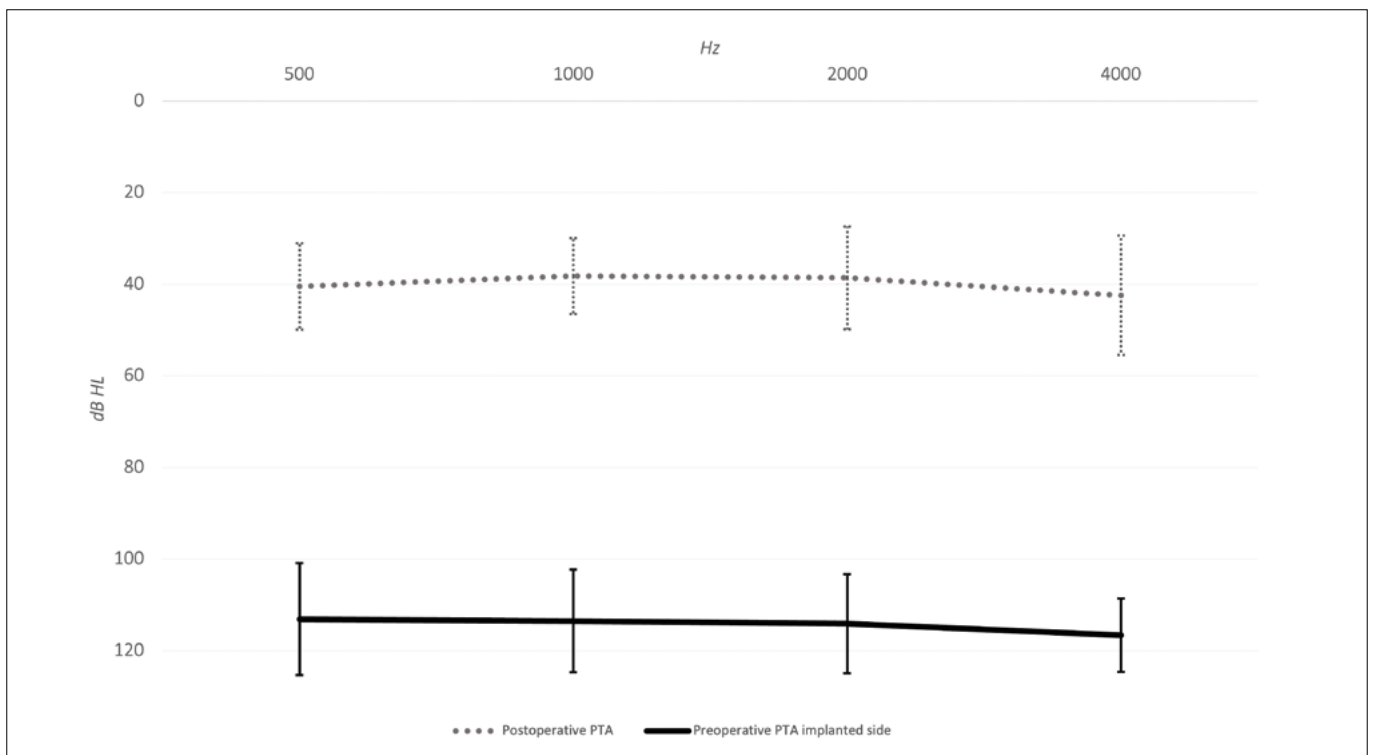


Figure 2. Pre- vs post-operative pure tone audiometry. Graphic depiction of PTA for each frequency for the implanted side, pre-operatively and 6 months after surgery. Horizontal lines represent PTA trending line, while vertical lines represent SD for each frequency.

of 39.9 dB HL (range 18.75-70 dB HL, SD \pm 9.7). Mean PTA functional gain after COI positioning was 74.1 dB HL (Figs. 1, 2).

Surgery

Forty-four patients (80%) underwent SP in combination with COI positioning (single-stage procedure), while 11 patients (20%) underwent two consecutive surgical procedures: SP followed by COI placement (staged procedure). None of the patients underwent a total petrosectomy. Inflammatory status at time of surgery was also investigated: active middle ear inflammation was present in 15 cases (27.3%), and no inflammation was detected among the remaining 40 patients (72.7%). Only one patient who underwent a staged procedure showed active middle ear inflammation at time of surgery (Tab. II). Surgical cavity was obliterated in 49 patients; autologous abdominal fat was used in 46 cavities (83.7%), temporalis muscle in 1 case (1.8%) and hydroxyapatite granules in 2 patients (3.6%). No obliteration material was used in 6 cases (10.9%). Mean surgical time was assessed for both single-stage and staged procedures. On average, single-stage surgeries required 196 minutes, while staged procedures required 221 minutes overall. The mean time for SP stage (first stage) was 127 minutes, while for COI positioning (second stage) it was 94 minutes. The time gap between the surgical stages was 7.8 months overall. Further details about COI model and electrode insertion are listed in Table II.

Complications

Seven of 55 patients (12.7%) experienced surgical complications. Among major complications, there was one case of abdominal haematoma needing revision surgery and one case of COI failure that occurred 40 months after surgery, requiring explantation and reimplantation. Minor complications included 2 cases of EAC closure breakdown treated by scarring of the margins of the wound. One case of retroauricular wound infection was treated with antibiotic therapy, while another patient required surgical suture and wound dressings for retroauricular suture dehiscence. Finally, 1 case of abdominal seroma was reported, but did not require any specific therapy. Other than the patient who experienced COI failure, the above-mentioned complications occurred 8.1 days after surgery on average (range, 1-22 days) (Tab. III). Among the 7 patients who experienced complications, 3 had an active inflammation at time of surgery (42.9%) and none had received a staged procedure.

Radiological follow-up

A post-operative HRCT was performed in 49.1% of cases

(27 patients). Among these, the first HRCT scan was made 12 months after COI surgery in 7 cases (25.9%). Mean radiological follow-up time was 24 months after surgery. From the available medical records, only 4 of 27 patients (14.8%) underwent more than one radiological imaging during follow-up (Tab. III).

Literature review

Tables I, II and III provide a detailed overview of the studies meeting our inclusion criteria^{3,8-18}. Twelve articles were identified, including 103 patients for a total of 103 ears. Regarding surgical indications, information about the chronic middle ear disorder was available in 24 of 103 cases (23.3%) (Tab. I). Of those 24, 7 patients were affected by COM (29.2%), 6 by CSOM (25%) and 11 by CCOM (45.8%), making CCOM the most observed disease. Information was not available in 76.7% of cases. Previous surgical details were reported in 86 cases (83.5%). Specifically, among these, 49 underwent a previous TPL CWD (57%), 17 received TPL CWU (19.8%) and 20 patients had a previous radical cavity (23.2%). For the remaining 16.5% of patients, surgical history was not recorded. Surgical details about contralateral ear were reported in 2 papers accounting for only 6 cases (6.9%) among the 86 with an available surgical information. Regarding cochlear implantation, all patients enrolled in the study received a SP (Tab. II). For 80 cases (77.7%), a single stage surgery was performed, whereas for 9.7% (10 cases) the surgical intervention was staged. Finally, for 13 cases (12.6%) data about surgical staging were not available. Obliteration material of the cavity was also assessed, when described. Abdominal fat was the most common obliteration material used (75 cases of 103; 72.8%), while in 3 patients the temporalis muscle was preferred. In 25 cases, details about the obliteration material were not available. A total of 9 complications were identified among the included patients (8.7%), and all were classified as major according to the proposed criteria of Hansen et al.⁴ (Tab. III).

Discussion

Constant improvements in the field of cochlear implantation have been made over the years. Profoundly deaf patients require an effective hearing rehabilitation and when deafness is concomitant with chronic refractory middle ear pathologies, hearing rehabilitation must be combined with the successful eradication of the disease. While some bone conduction hearing implants can be positioned away from an open cavity or a chronically discharging middle ear¹⁹, cochlear implantation in these scenarios seems hazardous. SP overcomes these limits, resulting in a “safe and dry” cavity that is optimal for COI positioning⁵. The efficacy and the advantages of this surgical

Table II. Surgical details.

Author, year	Cases	Ears	Type of petrosectomy		Inflammatory status at time of surgery		Staging	Median time between stages	Obliteration material	COI model	Electrode insertion
			Subtotal	Total	Active	Stable					
Baranano et al. 2013 ⁸	7	7	7	0	N/A	N/A	N/A	N/A	Abdominal fat, temporalis muscle or bone pate – N/A	N/A	N/A
Vincenti et al. 2014 ⁹	9	9	9	0	1	8	Single stage – 8	6 months	Abdominal fat – 9	N/A	Complete
Bernardeschi et al. 2015 ¹⁰	4	4	4	0	4	0	Staged – 1 Single stage – 4	/	Abdominal fat – 4	CI24 – 2	Complete
Casserly et al. 2016 ¹¹	2	2	2	0	2	0	Staged – 2	N/A	Temporalis muscle – 2	N/A	N/A
Szymanski et al. 2016 ¹²	9	9	9	0	4	N/A	Single stage – 8	6 months	Abdominal fat – 9	N/A	N/A
Altuna et al. 2017 ¹³	3	3	3	0	1	N/A	Staged – 1 Single stage – 3	/	Abdominal fat – 2 Temporalis muscle – 1	N/A	N/A
D'Angelo et al. 2020 ¹⁴	7	7	7	0	4	N/A	Single stage – 7	/	Abdominal fat – 7	N/A	N/A
Kurkure et al. 2020 ¹⁵	7	7	7	0	N/A	N/A	Single stage – 7	/	N/A	N/A	N/A
Yoon et al. 2020 ¹⁶	3	3	3	0	N/A	N/A	Single stage – 3	/	Abdominal fat – 3	N/A	N/A
Lee et al. 2020 ¹⁷	2	2	2	0	/	2	Single stage – 2	/	Abdominal fat – 2	CI422, CI522	N/A
Grinblat et al. 2020 ³	39	39	39	0	3*	3*	Single stage – 33	Range 2-9 months	Abdominal fat – 39	N/A	Complete – 91.5% (overall)
Zhang et al. 2021 ¹⁸	11	11	11	0	1	N/A	Staged – 1 N/A – 5 Single stage – 5	2 months – 1	Temporalis muscle ± fascia ± bone paté ± fibroperiosteal flap – N/A	N/A	N/A
Present study	55	55	55	0	15	40	Staged – 5 N/A – 1 Single stage – 44 Staged – 11	7.8 months	<ul style="list-style-type: none"> Abdominal fat – 46 Temporalis muscle – 1 Hydroxyapatite granules – 2 No obliteration – 6 	CI422 – 1 CI512 – 4 CI522 – 1 CI532 – 2 CI612 – 1 CI622 – 2 CI632 – 1 CI24RE – 2 Digisonic SP – 1 Flex 28 – 18 Flexsoft – 1 Form 24 – 1 Hires90k Mid-scala – 4 Hires90k HiFocus 1J – 1 Sonata – 1 Synchrony medium – 2 Pulsar – 1 N/A – 11	Complete – 42 Non complete – 2 N/A – 11

COI: Cochlear Implant; N/A: Not Available; *: N/A for the other cases.

Table III. Complications and follow-up.

Author, year	Cases	Major complications	Minor complications	Onset	Treatment	Follow-up time	Radiological follow-up
Baranano et al. 2013 ⁸	7	Abscess – 1	N/A	N/A	Explantation after 5 months and reimplantation after 2 weeks of antibiotic therapy	N/A	N/A
Vincenti et al. 2014 ⁹	9	EAC closure breakdown – 1*	/	N/A	Rotation skin flap	144 months	HRCT between 12 and 18 months
Bernardeschi et al. 2015 ¹⁰	4	0	0	/	/	21 months	HRCT in all cases (timing N/A)
Casserly et al. 2016 ¹¹	2	0	0	/	/	37 months (overall)	HRCT if cholesteatoma is suspected
Szymanski et al. 2016 ¹²	9	0	0	/	/	36.6 months (overall)	HRCT at 1 year, optional at 3 years
Altuna et al. 2017 ¹³	3	Cavity infection – 1	0	N/A	Explantation	26 months (overall)	2, 5 and 10 years with HRCT
D'Angelo et al. 2020 ¹⁴	7	N/A	N/A	N/A	N/A	N/A	3 months and 3 years with HRCT
Kurkure et al. 2020 ¹⁵	7	N/A	N/A	N/A	N/A	37.2 months (overall)	N/A
Yoon et al. 2020 ¹⁶	3	0	0	/	/	24 months	N/A
Lee et al. 2020 ¹⁷	2	0	0	/	/	38 months	1, 3 and 5 years with HRCT or MRI
Grinblat et al. 2020 ³	39	a. Postauricular fistula/receiver exposure – 1 b. Cavity infection – 1 c. Postauricular fistula/receiver exposure – 1	0	a. 12 months b. 20 months c. 11 months	Explantation and reimplantation (a, b, c)	85 months (overall)	1, 2, 3, 5, 7, 9 years with HRCT
Zhang et al. 2021 ¹⁸	11	a. Electrode exposure – 1 b. COI exposure – 1 c. EAC closure breakdown – 1	0	N/A	a. Revision surgery (tragal cartilage to cover the electrode) b. COI explantation c. Wound dressing + antibiotics	24.2 months (overall)	N/A
Present study	55	a. Abdominal hematoma – 1 b. COI failure – 1	c. EAC closure breakdown – 2 d. Retroauricular wound infection – 1 e. Retroauricular suture dehiscence – 1 f. Abdominal seroma – 1	• 8.1 days (average) • 40 months (COI failure)	a. Revision surgery b. Explantation and reimplantation c. Scarring of the margins d. Antibiotic therapy e. Medications and suture f. None	44 months	• At 2 years on average (27 cases) • N/A for 28 cases

EAC: External Auditory Canal; COI: Cochlear Implant; HRCT: High-Resolution Computed Tomography; MRI: Magnetic Resonance Imaging; N/A: Not Available; *: classified as a major complication after review by adopting Hansen et al. criteria.

technique are increasingly acknowledged. However, surgical management in terms of staging and follow-up still remains controversial²⁰. Middle ear surgery failures are undeniably affected by the clinical behaviour of chronic middle ear pathologies over time. This tight clinical-surgical relationship led us to collect one of the largest series of patients submitted to SP in combination with cochlear implantation. In fact, data from the literature show that personal history of otitis media accounts for 55.4% of indications for SP and the presence of a mastoid cavity accounts for 35.5%. This makes these two entities the first and second most common indications for SP, as previously observed in the one of the largest studies in lit-

erature by Polo et al.⁶. Based on this evidence, a review of the most recent literature was carried out to identify all patients affected by chronic middle ear disorders with a history of failed prior surgery. According to our literature review, CCOM is the most common indication for SP (11 of 24 cases, 45.8%), which is consistent with the results from our series (50.9% of cases). Concerning previous surgical history, surprisingly, almost half of patients in our cohort had a history of TPL CWU (49.1%), compared to only 19.8% of patients in the literature who underwent this type of surgery before SP and COI. Of note, the literature does not usually report the surgical history of patients with middle ear diseases, and thus the results ob-

tained from our review can be underestimated. Postelmans et al.²¹ proposed a decisional algorithm based on the presence or absence of active middle ear inflammation in order to solve one of the main controversies in surgical management. As a rule, all patients with evidence of active middle ear inflammation were staged and none experienced post-operative complications. This is consistent with our experience, in which none of the patients who underwent staged procedures experienced complications. However, the main reason prompting staged surgery was not the presence of active inflammation, but the evidence of CCOM (9 of 11 staged SP were affected by CCOM). In fact, 11 of 14 patients with signs of active inflammation underwent a single stage procedure without experiencing adverse events. Conversely, it is worth noticing that the other 3 cases with active inflammation at time of surgery were among the 7 with post-operative complications. The absence of complications among the staged patients is an indicator of the safety of staged surgeries. In our opinion, there is no interdependence between the presence of active inflammation and post-operative complications development. This hypothesis was confirmed by Grinblat et al. in whose experience complications occurred predominantly in patients with inactive inflammatory status³. The timing of staging in our series was 7.8 months on average. This was consistent with literature in which second stage surgery was usually performed at 6 months^{7,9,12}. Six months is the estimated time interval for small residual pearls of cholesteatoma to manifest, which might have gone undetected during surgery¹². Autologous abdominal fat was, by far, the most preferred among obliteration materials for the surgical cavity. It was chosen in 72.8% of cases in our review and in 83.7% of patients in our series. The main reasons are the low metabolic rate and easy accessibility for grafting, as well as the creation of a radiological visual interface that enables better recognition of indirect signs of cholesteatoma at HRCT^{5,6,20}. More specifically, MRI-induced artifacts produced by a COI do not allow to check for cholesteatoma recurrences: even if tailored COI positioning makes it feasible to monitor specific intracranial structures, its role in cholesteatoma detection is still debated^{22,23}. The use of HRCT on a cavity obliterated with abdominal fat partially overcomes this limit even though the timing of radiological follow-up is controversial. Gruppo Otologico⁵⁻⁷ has proposed a HRCT follow up at 1, 3, 5 and 10 years, while Vincenti et al.⁹ advocate the execution of a HRCT from 12 to 18 months after surgery for reference and a second scan only in the presence of alarming symptoms. In our retrospective series, 49.1% of patients had a post-operative HRCT at a mean time of 24 months after surgery and no recurrences of cholesteatoma were observed during follow-up (44 months on average). As reported in the literature, SP provides better results in terms of surgical risks and complications than other alter-

native surgical approaches. In particular, the risk of array extrusion is lower in SP than in revision mastoidectomy approaches and the technique is more feasible compared to approaches that bypass the middle ear like the middle cranial fossa one^{12,21,24}. In our multicentric case series, only 12.7% of patients experienced complications, which is undeniably lower compared to patients who underwent CWD tympanoplasty with cochlear implantation (30% according to Hunter et al.)²⁴. An additional, non-negligible benefit given by SP is quality of life improvement in terms of clinical follow-up and daily living (swimming, vertigo induced by pressure or temperature changes)²⁴.

The multicentric nature of this study may be considered a limitation in terms of heterogeneity of the series. Many studies included in our review failed to provide adequate information about previous surgical history, contralateral ear status, COI model, or concomitant nasal pathology.

Conclusions

In patients with chronic middle ear disorders recalcitrant to previous treatments, SP with cochlear implantation is a safe and effective approach for disease eradication and simultaneous hearing rehabilitation. A single stage procedure is the most recommended strategy. Staging is advocated when CCOM is present rather than in cases of active inflammation. Optimal follow-up, in terms of timing and imaging technique, is still debated. The usefulness of SP for the paediatric population and its application along with implantable hearing devices (e.g. transcutaneous bone conduction implants, active middle ear implants) should be the object of further investigation.

Conflict of interest statement

The authors declare no conflict of interest.

Funding

This research did not receive any specific grant from funding agencies in the public, commercial, or not-for-profit sectors.

Author contributions

PC, SM, SB, MBE: conception and design of the study, acquisition and interpretation of data, drafting of the article, literature revision, critical revision for important intellectual content and final approval of the version to be published. LB, FF, FL, DM: conception and design of the study, acquisition of data and final approval of the version to be published. AA, MBA, AC, EC, EC, DC, FD, MF, SF, LG, SG, AL, RL, MM, EP, GR, FV, DZ, EZ: acquisition of data and final approval of the version to be published.

Ethical consideration

This study was approved by the Institutional Ethics Committee of the IRCCS Policlinico San Matteo, Pavia (IRB# 0062983/22). The research was conducted ethically, with all study procedures being performed in accordance with the requirements of the World Medical Association's Declaration of Helsinki. Written informed consent was obtained from each volunteer for study participation and data publication.

References

- 1 Fisch U, Mattox DE. *Microsurgery of the Skull Base*. First edition. Thieme-Verlag; 1988.
- 2 Gacek RR. Mastoid and middle ear cavity obliteration for control of otitis media. *Ann Otol Rhinol Laryngol* 1976;85:305-309. <https://doi.org/10.1177/000348947608500301>
- 3 Grinblat G, Vlad Di, Caruso A, et al. Evaluation of subtotal petrosectomy technique in difficult cases of cochlear implantation. *Audiol Neurotol* 2020;25:323-335. <https://doi.org/10.1159/000507419>
- 4 Hansen S, Anthonsen K, Stangerup SE, et al. Unexpected findings and surgical complications in 505 consecutive cochlear implantations: A proposal for reporting consensus. *Acta Otolaryngol* 2010;130:540-549. <https://doi.org/10.3109/00016480903358261>
- 5 Free RH, Falcioni M, Di Trapani G, et al. The role of subtotal petrosectomy in cochlear implant surgery—a report of 32 cases and review on indications. *Otol Neurotol* 2013;34:1033-1040. <https://doi.org/10.1097/MAO.0b013e318289841b>
- 6 Polo R, Del Mar Medina M, Arístegui M, et al. Subtotal petrosectomy for cochlear implantation: lessons learned after 110 cases. *Ann Otol Rhinol Laryngol* 2016;125:485-494. <https://doi.org/10.1177/0003489415620427>
- 7 Vashishth A, Fulcheri A, Prasad SC, et al. Cochlear implantation in cochlear ossification: retrospective review of etiologies, surgical considerations, and auditory outcomes. *Otol Neurotol* 2018;39:17-28. <https://doi.org/10.1097/MAO.0000000000001613>
- 8 Barañano CF, Kopelovich JC, Dunn CC, et al. Subtotal petrosectomy and mastoid obliteration in adult and pediatric cochlear implant recipients. *Otol Neurotol* 2013;34:1656-1659. <https://doi.org/10.1097/MAO.0b013e3182a006b6>
- 9 Vincenti V, Pasanisi E, Bacciu A, et al. Long-term results of external auditory canal closure and mastoid obliteration in cochlear implantation after radical mastoidectomy: a clinical and radiological study. *Eur Arch Otorhinolaryngol* 2014;271:2127-2130. <https://doi.org/10.1007/s00405-013-2698-3>
- 10 Bernardeschi D, Nguyen Y, Smail M, et al. Middle ear and mastoid obliteration for cochlear implant in adults: indications and anatomical results. *Otol Neurotol* 2015;36:604-609. <https://doi.org/10.1097/MAO.0000000000000702>
- 11 Casserly P, Friedland PL, Atlas MD. The role of subtotal petrosectomy in cochlear implantation. *J Laryngol Otol* 2016;130:S35-S40. <https://doi.org/10.1017/S0022215116000979>
- 12 Szymański M, Ataide A, Linder T. The use of subtotal petrosectomy in cochlear implant candidates with chronic otitis media. *Eur Arch Otorhinolaryngol* 2016;273:363-370. <https://doi.org/10.1007/s00405-015-3573-1>
- 13 Altuna X, García L, Martínez Z, et al. The role of subtotal petrosectomy in cochlear implant recipients. *Eur Arch Otorhinolaryngol* 2017;274:4149-4153. <https://doi.org/10.1007/s00405-017-4762-x>
- 14 D'angelo G, Donati G, Bacciu A, et al. Subtotal petrosectomy and cochlear implantation. *Acta Otorhinolaryngol Ital* 2020;40:450-456. <https://doi.org/10.14639/0392-100X-N0931>
- 15 Kurkure R, Rayamajhi P, Castellino A, et al. Subtotal petrosectomy in cochlear implant surgery: our experience. *Indian J Otolaryngol Head Neck Surg* 2020;72:320-325. <https://doi.org/10.1007/s12070-020-01819-8>
- 16 Yoon YH, Lee J Bin, Chung JH, et al. Cochlear implantation in patients with chronic suppurative otitis media: surgical outcomes and a management algorithm. *Audiol Neurotol* 2020;25:151-157. <https://doi.org/10.1159/000505509>
- 17 Lee S, Lee J Bin, Chung JH, et al. Surgical outcomes of simultaneous cochlear implantation with subtotal petrosectomy. *Auris Nasus Larynx* 2020;47:943-949. <https://doi.org/10.1016/j.anl.2020.05.009>
- 18 Zhang K, Yan F, Nguyen SA, et al. Subtotal petrosectomy with cochlear implantation or osseointegrated hearing rehabilitation: a single institutional study. *Otol Neurotol* 2021;42:1499-1506. <https://doi.org/10.1097/MAO.00000000000003326>
- 19 Canzi P, Avato I, Beltrame M, et al. Retrosigmoidal placement of an active transcutaneous bone conduction implant: surgical and audiological perspectives in a multicentre study. *Acta Otorhinolaryngol Ital* 2021;41:91-99. <https://doi.org/10.14639/0392-100X-N0609>
- 20 Yan F, Reddy PD, Isaac MJ, et al. Subtotal petrosectomy and cochlear implantation: a systematic review and meta-analysis. *JAMA Otolaryngol Head Neck Surg* 2021;147:23-33. <https://doi.org/10.1001/jamaoto.2020.3380>
- 21 Postelmans JTF, Stokroos RJ, Linmans JJ, et al. Cochlear implantation in patients with chronic otitis media: 7 years' experience in Maastricht. *Eur Arch Otorhinolaryngol* 2009;266:1159-1165. <https://doi.org/10.1007/s00405-008-0842-2>
- 22 Canzi P, Magnetto M, Simoncelli A, et al. The role of cochlear implant positioning on MR imaging quality: a preclinical in vivo study with a novel implant magnet system. *Eur Arch Otorhinolaryngol* 2022;279:2889-2898. <https://doi.org/10.1007/s00405-021-07005-y>
- 23 Canzi P, Luzzi S, Carlotto E, et al. Customized cochlear implant positioning in a patient with a low-grade glioma: towards the best MRI artifact management. *Otol Neurotol* 2022;43:E628-E634. <https://doi.org/10.1097/MAO.00000000000003532>
- 24 Hunter JB, O'Connell BP, Wanna GB. Systematic review and meta-analysis of surgical complications following cochlear implantation in canal wall down mastoid cavities. *Otolaryngol Head Neck Surg* 2016;155:555-563. <https://doi.org/10.1177/0194599816651239>