

# The effectiveness of bevacizumab in radionecrosis after radiosurgery of a single brain metastasis

Durim Delishaj,<sup>1</sup> Stefano Ursino,<sup>1</sup> Francesco Pasqualetti,<sup>1</sup> Ilaria Pesaresi,<sup>2</sup> Ilaria Desideri,<sup>2</sup> Mirco Cosottini,<sup>2</sup> Concetta Laliscia,<sup>1</sup> Fabiola Païar,<sup>1</sup> Maria Grazia Fabrini<sup>1</sup>

<sup>1</sup>Department of Radiotherapy,

<sup>2</sup>Neuroradiology Unit, University Hospital of Pisa, Italy

## Abstract

Radionecrosis (RN) of brain tissue is a serious late complication of brain irradiation and historically has been treated with corticosteroid therapy and alternatively surgical decompression. Recently, bevacizumab has been suggested for treatment of cerebral radiation necrosis. We present a case of a 73-years-old woman affected by a primary non-small cell lung cancer with a single brain metastasis treated with radiosurgery. Two years after radiosurgery the patient referred neurological symptoms and a brain magnetic resonance confirmed the presence of RN. The patient refused surgical decompression so underwent at the treatment with bevacizumab 7.5 mg/kg/2 weeks for a total of 4 cycles. After two months of treatment the patient reported instrumental and clinical improvement. Ten months after bevacizumab discontinuation the patient experienced a recurrence of RN with evident clinical manifestation and confirmed by radiological imaging. A new treatment with bevacizumab was not performed due to the systemic progression disease and the worsening of clinical status. Despite limited to only one clinical case, our study suggests the efficacy of bevacizumab to treat RN. Future studies are needed to confirm its mechanism and to properly define the optimal scheduling, dosage and duration of therapy.

## Introduction

Radionecrosis (RN) is the most severe toxicity of radiosurgery (SRS) or stereotactic radiotherapy (SRT) of brain metastases, usually occurring three or more months after completion of therapy. The symptoms range from focal to generalized neurologic deficits with loss of patient autonomy and negative impact

on the quality of life.<sup>1</sup> The total radiation dose and volume as well as fractionation regimen are recognized as the main predictive factors of this severe sequela.<sup>2-5</sup>

The pathogenesis is associated to endothelial cell dysfunction with an increased release of vascular endothelial growth factor (VEGF) and a subsequent serious damage of the blood-brain barrier. Deregulation of VEGF levels causes vascular permeability, brain edema, neuronal demyelination and finally necrosis.<sup>6-8</sup>

Despite the difficulty to discriminate between tumor recurrence and radiation-induced tissue damage, magnetic resonance (MR) imaging is considered the gold standard for the diagnosis of RN showing a contrast-enhancing mass with brain white matter changes and an edema within or adjacent to the site of the original.<sup>9-11</sup>

Historically, the RN has always been treated with corticosteroid therapy with poor results and many side effects such as behavioral changes, altered sleep patterns and changes in appetite. Alternatively, the surgical decompression of necrotic area can provide a beneficial palliative effect despite the radical removal of the whole necrotic process is difficult to obtain in most cases.<sup>10,12</sup>

Recently, bevacizumab (a humanized murine monoclonal antibody against VEGF) has been suggested as a new treatment modality for brain RN.<sup>11,13-22</sup>

Here, we report a case of a patient affected by a post-SRS brain necrosis, who experienced a prolonged clinical benefit from several cycles of therapy with bevacizumab.

## Case Report

A 73-year-old woman, affected by a non small cell lung cancer (histological type: adenocarcinoma) with a solitary brain metastasis at diagnosis, was referred to our institution hospital in August 2010 for a stereotactic treatment. The staging exams [thorax-abdomen computed tomography (CT) and whole body PET/CT] excluded other distant metastases at lung, liver and bone whereas a MR of brain confirmed the presence of an asymptomatic 16×14 mm lesion located at the frontal subcortical left gyrus. First surgical removal of lesion was proposed, since the unique localization, but the patient refused so was candidate to a SRS. The radiation treatment was performed using a dedicated Linear Accelerator (TrueBeam Stx, Varian Medical System, PA, USA), X6MV photon beam and a volumetric modulated arc therapy (VMAT) technique was used.

A total dose of 30 Gy in a single fraction was prescribed to the isocenter with a target covered of 90% isodose line, as described by the

Correspondence: Durim Delishaj, Department of Radiotherapy, Azienda Ospedaliero Universitaria Pisana, Via Roma 67, Pisa, Italy.

Tel.: +39.050.992829 - Fax: +39.050.992960.

E-mail: delishaj@hotmail.com

Key words: Bevacizumab; stereotactic radiotherapy; radionecrosis.

Contributions: MC, IP, ID, contributed in brain MR examination and analysis of MRI images with detailed description of radiation induced necrosis before and after treatment with bevacizumab; SU, FP, CL, FaP, participate in drafting the article and revising it critically for important intellectual content; MGF, give final approval of the version to be submitted and any revised version.

Conflict of interest: the authors declare no conflict of interest.

Received for publication: 16 may 2015.

Revision received: 26 July 2015.

Accepted for publication: 29 July 2015.

This work is licensed under a Creative Commons Attribution NonCommercial 3.0 License (CC BY-NC 3.0).

©Copyright D. Delishaj et al., 2015

Licensee PAGEPress, Italy

Rare Tumors 2015; 7:6018

doi:10.4081/rt.2015.6018

Fukuoka et al.<sup>12</sup>

Next, the patient underwent to 5 cycles of cisplatin + pemetrexed with a partial response followed by a radiation treatment of the primary tumor and involved nodes. Then, she continued medical therapy with erlotinib for three months.

Two years after SRS treatment the patient reported neurological disorders such as cognitive slowing and loss of memory.

As shown in Figure 1, a MR of the brain detected presence of a well defined RN area corresponding to previously SRS-treated region. Specifically, the FSE T2 weighted images (Figure 1a) showed a hypointense lesion with irregular borders surrounded by evident vasogenic edema whereas the diffusion and post contrast SE T1 weighted images revealed a central necrotic core and a peripheral enhancing component with restricted diffusion. Moreover, the spectroscopic analysis showed a reduction of normal peaks and an abnormal increase of lipids (arrow) and lactate (arrowhead). At first we started medical therapy with Dexamethasone at a dose of 8 mg twice daily, however no improvements of neurological symptoms were observed. Then, surgical decompression was suggested but the patient refused it. Thus, after obtained written informed consent, we started medical therapy

with bevacizumab 7.5 mg/Kg/2 weeks for a total of 4 cycles with clinical remission of neurological symptoms. Moreover, 2 months after the end of bevacizumab treatment, MR indicated significant reduction of RN area as shown in Figure 2.

The axial FSE T2 weighted images (Figure 2a), the diffusion weighted images (Figure 2b) and the SE T1 weighted images revealed the reduction of the RN lesion together with the perilesional edema whereas the subsequent spectroscopic analysis showed the recovery of normal peaks and the disappearance of lipids and lactate (Figure 2).

The clinical and radiological remission remained stable for an overall 8 months after the end of Bevacizumab

Next, a subsequent MR at 10 months after discontinuation of Bevacizumab showed a recurrence of RN area together with the reappearance of abnormal peaks typical of necrosis (Figure 3).

Due to the systemic progression disease and the worsening of clinical status, the medical therapy with Bevacizumab was definitely discontinued.

## Discussion

RN of brain tissue is a possible late complication occurring after SRS of brain metastases, usually diagnosed both at follow-up imaging or at the appearance of neurological symptoms.

Common symptoms include psychomotor slowing, seizures, generalized signs with loss of patient autonomy and negative impact on the life quality.<sup>1-5</sup>

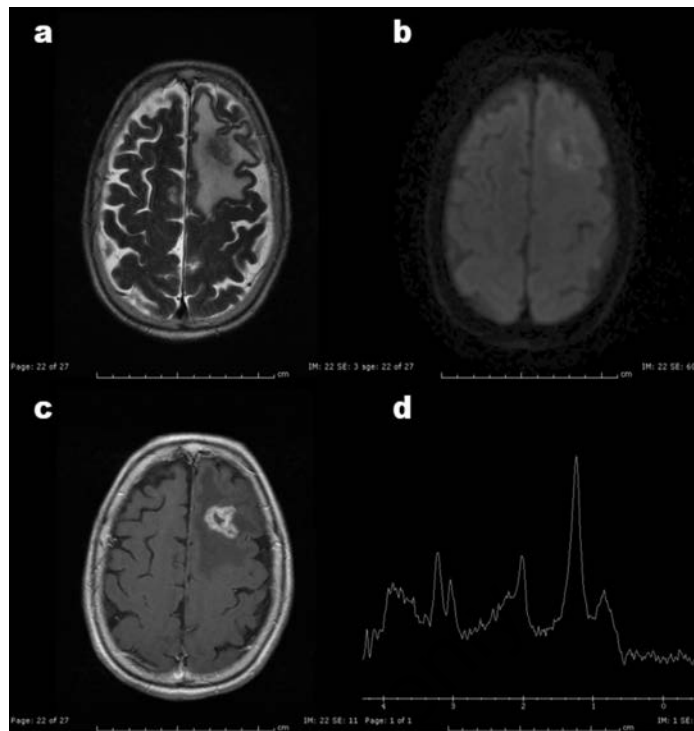
In this paper, we report the case of a patient who refused surgical removal and underwent both to a clinical and radiological remission of RN lesion after four cycles with low dose of bevacizumab.

Despite poor data in literature, bevacizumab treatment seems to be clinical beneficial for patients affected by post radiation necrosis lesions.<sup>11,13-22</sup>

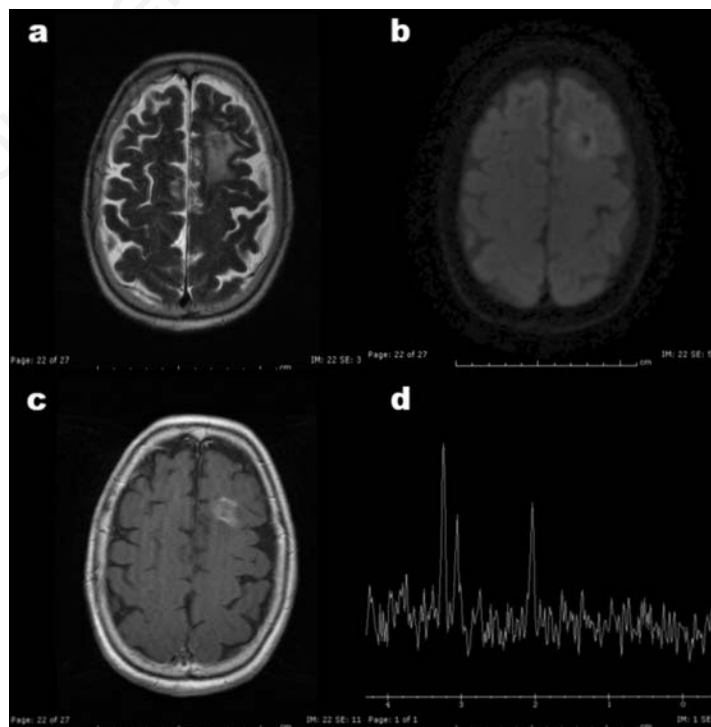
Gonzalez *et al.*<sup>13</sup> retrospectively reported significant reduction of neurological symptoms and radiological partial remission in 8 patients using bevacizumab at the dose of 5 mg/kg/2 weeks or 7.5 mg/kg/3 weeks.

Torcuator *et al.*<sup>14</sup> demonstrated radiographic response in 6 patients with biopsy proven RN treated with low doses of bevacizumab. All patients had an average reduction of 79% for the post gadolinium studies and 49% for the FLAIR images.

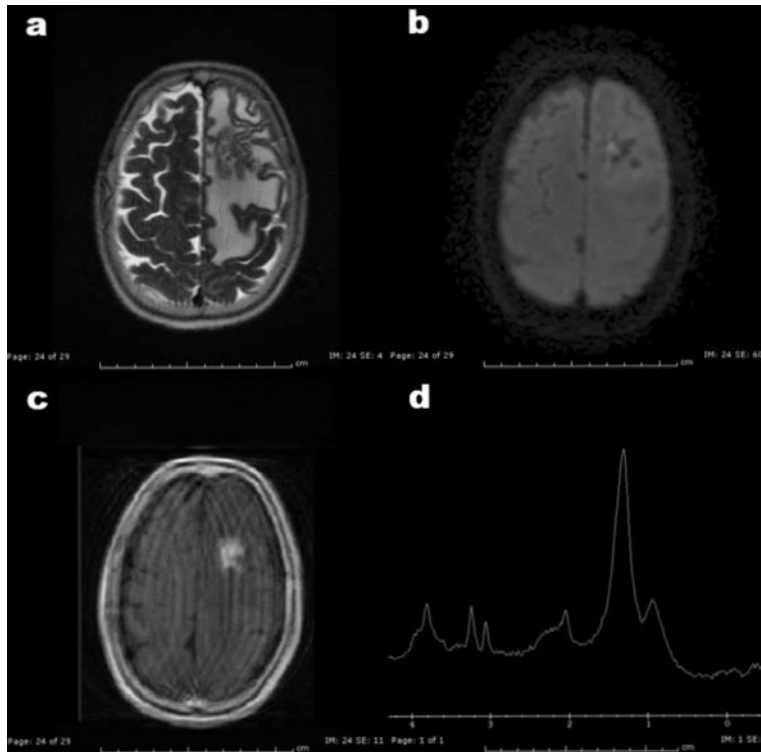
Moreover, Wang *et al.*<sup>17</sup> reported that bevacizumab administered at the dose of 7.5 mg/kg/2 weeks was effective in reduction of cerebral edema at RMI evaluation with a sub-



**Figure 1.** Magnetic resonance before treatment with bevacizumab. The axial FSE T2 weighted image (a) revealed a hypointense lesion with irregular borders surrounded by evident vasogenic edema. The diffusion weighted (b) and post contrast SE T1 weighted (c) axial images allowed to distinguish a central core with necrotic behavior and an enhancing peripheral component with restricted diffusion. The proton MRS (d) showed a reduction of normal peaks, and an abnormal accumulation of lipids (arrow) and lactate (arrowhead).



**Figure 2.** Magnetic resonance imaging two months after treatment with bevacizumab. The axial FSE T2 weighted (a), diffusion weighted (b) and SE T1 weighted (c) axial images revealed a reduction of the lesion and reactive edema. The MRS (d) showed a recovery of the normal peaks and the disappearance of lipids and lactate. The Magnetic Resonance imaging remained stable for other six months after treatment.



**Figure 3.** Magnetic resonance imaging examination of the brain acquired 10 months after discontinuation of treatment with bevacizumab. The axial FSE T2 weighted (a), diffusion weighted (b) and SE T1 weighted (c) axial images demonstrated a recrudescence of the radionecrotic phenomena with increased perilesional oedema and the MRS (d) allowed to detect the reappearance of the abnormal peaks indicative of necrosis.

sequent improvement of clinical symptoms in 17 patients affected by a symptomatic brain RN.

Also Levin *et al.*<sup>18</sup> in 14 patients with biopsy proven RN, reported the efficacy of bevacizumab at the dose of 7.5 mg/kg/3 weeks to both reduce the necrotic area and improve clinical symptoms.

Furthermore, similar results were reported by Boothe *et al.*<sup>19</sup> and Furuse *et al.*<sup>20,21</sup> in their retrospective studies.

Finally, Tye *et al.*<sup>22</sup> reviewed 16 different studies for a total of 71 brain RN patients treated with.

The authors report that the median time of starting treatment with Bevacizumab was 11 months by the end of radiotherapy and the most frequently used scheduling was 7.5 mg/kg/2 weeks for a total of 4 cycles. In these studies was observed a median decrease of 63% of contrast enhancement rate in T1 images and of 59% of signal abnormality in T2/FLAIR, when compared pre-treatment and post treatment images.

Overall, based on the current available data, low doses of bevacizumab seem to be efficacious in reducing RN in patients affected by brain metastases undergone to SRS or SRT, apparently without any risk of clinical complication.

Currently, the optimal scheduling and treatment duration has not been yet established.

Nevertheless, a significant amount of recurrence has been described several months after bevacizumab discontinuation, indicating repeated cycles might be warranted in absence of contraindications.

## Conclusions

Bevacizumab seem to be very promising agent for the treatment of brain RN as well as anti-cancer drug. Our experience, despite limited to a case patient, supports the current available literature. Future studies are required to properly evaluate the role of bevacizumab as an efficacious agent against post radiation necrosis as well as to define the optimal scheduling, dosage and duration of therapy.

## References

1. Marks JE, Wong J. The risk of cerebral radiation necrosis in relation to dose, time, and fractionation. *Prog Exp Tumor Res* 1985;29:210-8.

2. Ruben JD, Dally M, Bailey M, et al. Cerebral radiation necrosis: incidence, outcomes, and risk factors with emphasis on radiation parameters and chemotherapy. *Int J Radiat Oncol Biol Phys* 2006;65:499-508.
3. Wara WM, Bauman GS, Sneed PK, et al. Brain, brain stem and cerebellum. In: Perez CA, Brady LW, eds. *Principles and practice of radiation oncology*. 3rd ed. Philadelphia: Lippincott-Raven; 1998. pp 777-828.
4. Li YQ, Ballinger JR, Nordal RA, et al. Hypoxia in radiation-induced blood-spinal cord barrier breakdown. *Cancer Res* 2001;61:3348-54.
5. Burger PC, Boyko OB. The pathology of central nervous system radiation injury. In: Gutin PH, Leibel SA, Sheline GE, eds. *Radiation injury of the nervous system*. New York: Raven Press Ltd; 1991. pp 191-208.
6. Nonoguchi N, Miyatake S, Fukumoto M, et al. The distribution of vascular endothelial growth factor-producing cells in clinical radiation necrosis of the brain: pathological consideration of their potential roles. *J Neurooncol* 2011;105:423-31.
7. Wong ET, Brem S. Antiangiogenesis treatment for glioblastoma multiforme: challenges and opportunities. *Natl Compr Canc Netw* 2008;6:515-22.
8. Kim JH, Chung YG, Kim CY, et al. Upregulation of VEGF and FGF2 in normal rat brain after experimental intraoperative radiation therapy. *J Korean Med Sci* 2004;19:879-86.
9. Gerstner ER, Chen PJ, Wen PY, et al. Infiltrative patterns of glioblastoma spread detected via diffusion MRI after treatment with cediranib. *J Clin Oncol* 2010;28:e91-3.
10. McPherson CM, Warnick RE. Results of contemporary surgical management of radiation necrosis using frameless stereotaxis and intraoperative magnetic resonance imaging. *J Neurooncol* 2004;68:41-7.
11. Boström JP, Seifert M, Greschus S, et al. Bevacizumab treatment in malignant meningioma with additional radiation necrosis. An MRI diffusion and perfusion case study. *Strahlenther Onkol* 2014;190:416-21.
12. Fukuoka S, Seo Y, Takanashi M, et al. Radiosurgery of brain metastases with the gamma knife. *Stereotact Funct Neurosurg* 1996;66:193-200.
13. Gonzalez J, Kumar AJ, Conrad CA, Levin VA. Effect of bevacizumab on radiation necrosis of the brain. *Int J Radiat Oncol Biol Phys* 2007;67:323-6.
14. Torcuator R, Zuniga R, Mohan YS, et al. Initial experience with bevacizumab treatment for biopsy confirmed cerebral radia-

- tion necrosis. *J Neurooncol* 2009;94:63-8.
15. Sanborn MR, Danish SF, Rosenfeld MR, et al. Treatment of steroid refractory, Gamma Knife related radiation necrosis with bevacizumab: case report and review of the literature. *Clin Neurol Neurosurg* 2011;113:798-802.
  16. Matuschek C, Bölke E, Nawatny J, et al. Bevacizumab as a treatment option for radiation-induced cerebral necrosis. *Strahlenther Onkol* 2011;187:135-9.
  17. Wang Y1, Pan L, Sheng X, et al. Reversal of cerebral radiation necrosis with bevacizumab treatment in 17 Chinese patients. *Eur J Med Res* 2012;23:17-25.
  18. Levin VA, Bidaut L, Hou P, et al. Randomized double-blind placebo-controlled trial of bevacizumab therapy for radiation necrosis of the central nervous system. *Int J Radiat Oncol Biol Phys* 2011;79:1487-95.
  19. Boothe D, Young R, Yamada Y, et al. Bevacizumab as a treatment for radiation necrosis of brain metastases post stereotactic radiosurgery. *Neuro Oncol* 2013;15:1257-63.
  20. Furuse M, Nonoguchi N, Kawabata S, et al. Bevacizumab treatment for symptomatic radiation necrosis diagnosed by amino acid PET. *Jpn J Clin Oncol* 2013;43:337-41.
  21. Furuse M, Kawabata S, Kuroiwa T, Miyatake SI. Repeated treatments with bevacizumab for recurrent radiation necrosis in patients with malignant brain tumors: a report of 2 cases. *J Neurooncol* 2011;102:471-5.
  22. Tye K, Engelhard HH, Slavin KV, et al. An analysis of radiation necrosis of the central nervous system treated with bevacizumab. *J Neurooncol* 2014;117:321-7.

Non commercial use only