

## Accepted Manuscript

Title: Small Bowel Protection against NSAID-injury in Rats:  
Effect of Rifaximin, a poorly absorbed, GI targeted, antibiotic

Author: Matteo Fornai Luca Antonioli Caronina Pellegrini  
Rocchina Colucci Deborah Sacco Erika Tirota Gianfranco  
Natale Alessia Bartalucci Marina Flaibani Cecilia Renzulli  
Emilia Ghelardi Corrado Blandizzi Carmelo Scarpignato



PII: S1043-6618(15)00296-0  
DOI: <http://dx.doi.org/doi:10.1016/j.phrs.2015.12.031>  
Reference: YPHRS 3024

To appear in: *Pharmacological Research*

Received date: 8-8-2015  
Revised date: 17-12-2015  
Accepted date: 25-12-2015

Please cite this article as: Fornai Matteo, Antonioli Luca, Pellegrini Caronina, Colucci Rocchina, Sacco Deborah, Tirota Erika, Natale Gianfranco, Bartalucci Alessia, Flaibani Marina, Renzulli Cecilia, Ghelardi Emilia, Blandizzi Corrado, Scarpignato Carmelo. Small Bowel Protection against NSAID-injury in Rats: Effect of Rifaximin, a poorly absorbed, GI targeted, antibiotic. *Pharmacological Research* <http://dx.doi.org/10.1016/j.phrs.2015.12.031>

This is a PDF file of an unedited manuscript that has been accepted for publication. As a service to our customers we are providing this early version of the manuscript. The manuscript will undergo copyediting, typesetting, and review of the resulting proof before it is published in its final form. Please note that during the production process errors may be discovered which could affect the content, and all legal disclaimers that apply to the journal pertain.

## Small Bowel Protection against NSAID-injury in Rats: Effect of Rifaximin, a poorly absorbed, GI targeted, antibiotic

Matteo Fornai<sup>a</sup>, Luca Antonioli<sup>a</sup>, Caronina Pellegrini<sup>a</sup>, Rocchina Colucci<sup>b</sup>, Deborah Sacco<sup>a</sup>, Erika Tirotta<sup>a</sup>, Gianfranco Natale<sup>c</sup>, Alessia Bartalucci<sup>c</sup>, Marina Flaibani<sup>c</sup>, Cecilia Renzulli<sup>d</sup>, Emilia Ghelardi<sup>e</sup>, Corrado Blandizzi<sup>a</sup>, Carmelo Scarpignato<sup>f</sup>

<sup>a</sup>Division of Pharmacology, Department of Clinical & Experimental Medicine, University of Pisa, Via Roma 55, 56126 Pisa, Italy

<sup>b</sup>Department of Pharmaceutical and Pharmacological Sciences, University of Padova, Padova, Italy

<sup>c</sup>Department of Translational Research and New Technologies in Medicine and Surgery, University of Pisa, Via Roma 55, 56126 Pisa, Italy

<sup>d</sup>Department of Research & Development, Alfa Wassermann SpA, Via Ragazzi del '99, 5, 40133, Bologna, Italy

<sup>e</sup>Department of Translational Research and New Technologies in Medicine and Surgery, University of Pisa Via San Zeno 37, 56127 Pisa

<sup>f</sup>Clinical Pharmacology & Digestive Pathophysiology Unit, Department of Clinical & Experimental Medicine, University of Parma, Via Gramsci 14, 43126, Parma, Italy

### Address for Correspondence:

**Carmelo SCARPIGNATO, MD, DSc (Hons), PharmD, MPH, FRCP (London), FACP, FCP, FACG, AGAF**

Professor of Pharmacology & Therapeutics

Associate Professor of Gastroenterology

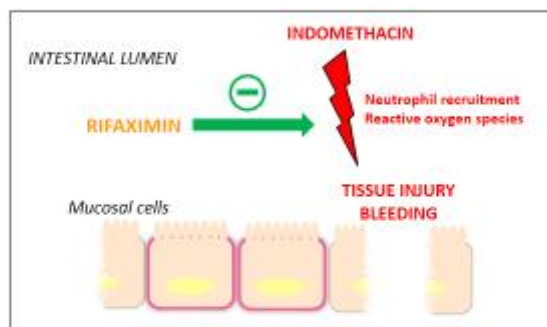
*Head*, Clinical Pharmacology & Digestive Pathophysiology Unit

Department of Clinical & Experimental Medicine, University of Parma

Maggiore University Hospital, Cattani Pavillon, I-43125 Parma, Italy

Phone: +39 0521 903863; E-mail: [scarpi@tin.it](mailto:scarpi@tin.it)

## Graphical Abstract



Graphical abstract

**Abstract**

Nonsteroidal anti-inflammatory drugs, besides exerting detrimental effects on the upper digestive tract, can also damage the small and large intestine. Although the underlying mechanisms remain unclear, there is evidence that enteric bacteria play a pivotal role. The present study examined the enteroprotective effects of a delayed-release formulation of rifaximin-EIR (R-EIR, 50 mg/kg BID, i.g.), a poorly absorbed antibiotic with a broad spectrum of antibacterial activity, in a rat model of enteropathy induced by indomethacin (IND, 1.5 mg/kg BID for 14 days) administration. R-EIR was administered starting 7 days before or in concomitance with IND administration. At the end of treatments, blood samples were collected to evaluate hemoglobin (Hb) concentration (as an index of digestive bleeding). Small intestine was processed for: 1) histological assessment of intestinal damage (percentage length of lesions over the total length examined); 2) assay of tissue myeloperoxidase (MPO) and TNF levels, as markers of inflammation; 3) assay of tissue malondialdehyde (MDA) and protein carbonyl concentrations, as an index of lipid and protein peroxidation, respectively; 4) evaluation of the major bacterial phyla. IND significantly decreased Hb levels, this effect being significantly blunted by R-EIR. IND also induced the occurrence of lesions in the jejunum and ileum. In both intestinal regions, R-EIR significantly reduced the percentage of lesions, as compared with rats receiving IND alone. Either the markers of inflammation and tissue peroxidation were significantly increased in jejunum and ileum from IND-treated rats. However, in rats treated with R-EIR, these parameters were not significantly different from those observed in controls. R-EIR was also able to counterbalance the increase in *Proteobacteria* and *Firmicutes* abundance induced by IND. R-EIR treatment significantly prevents IND-induced intestinal damage, this enteroprotective effect being associated with a decrease in tissue inflammation, oxidative stress and digestive bleeding as well as reversal of NSAID-induced alterations in bacterial population.

**Keywords:** Nonsteroidal anti-inflammatory drugs, intestinal damage, intestinal bleeding, rifaximin, enteroprotection, bacterial flora

## 1. Introduction

Nonsteroidal anti-inflammatory drugs (NSAIDs) are very effective medications [1,2], but their use is associated with a broad spectrum of adverse reactions involving the liver, kidney, cardiovascular (CV) system, skin and gut [3]. Gastrointestinal (GI) adverse effects are the most common and cover a wide clinical spectrum, ranging from dyspepsia, heartburn and abdominal discomfort to more serious events, such as peptic ulcer with life-threatening complications of bleeding and perforation [4,5].

While proton pump inhibitors (PPIs) reduce the development of peptic ulcer and related complications in patients taking NSAIDs or/and low-dose aspirin, their beneficial effect, which is related to their gastric antisecretory activity [6], is not expected to take place beyond the duodenum [7]. The appreciation that NSAID-associated GI damage does extend also to the lower digestive tract dates back to the early 90's, when a few observational studies and the first large prevention study (i.e. the MUCOSA trial) were published [8]. In the more recent VIGOR trial, more than 40% of NSAID-related events occurred in the lower GI tract (i.e. small bowel and colon) [9].

Over the past decade, there has been a progressive change in the overall pattern of GI events leading to hospitalization, with a clear decreasing trend in upper GI events and a slight, but significant, increase in lower GI events [10]. The availability of video capsule endoscopy has allowed a precise quantification of the incidence and characterization of small bowel damage, which appears to be time-dependent. Indeed, available studies [11,12] have shown that about 75% of NSAID users display intestinal mucosal injury, with *most* denuded areas identified in the proximal part of the small bowel and *all* ulcers in its distal part [13]. In healthy volunteers [12,14,15] and patients [11], omeprazole did not prevent NSAID-associated intestinal damage, evaluated by video capsule or/and fecal calprotectin measurement. Recent experimental (*for review see* [16]) and clinical [17,18] evidence suggests that PPIs may actually aggravate NSAID injury in the small bowel. The lack of protective effect is clearly due to the fact that

NSAID-enteropathy does not depend on gastric acid and is therefore not a pH-dependent phenomenon [5].

The pathogenesis of small intestinal damage is still not completely understood. Although drug-induced inhibition of mucosal prostaglandin (PG) synthesis during NSAID use occurs along the *entire* digestive tract, there are significant differences between the distal and proximal GI tract in the concurrence of other pathogenic factors that may add to mucosal damage. Among them, the absence of acid and the presence in the intestinal lumen of bacteria and bile, which may trigger specific NSAID-related pathogenic mechanisms at level of the distal GI tract, are the most prominent ones [19].

Increasing experimental evidence suggests that inhibition of both COX-1 and COX-2 is necessary to cause significant GI damage [20,21,22]. However, NSAID-induced injury to the intestinal epithelium is set in motion by direct effects of the drug after oral administration, a persistent *local* action, due to enterohepatic circulation and systemic effects after absorption. Initial cellular damage is due to entrance of the usually acidic NSAIDs into the cell *via* damage to the brush border cell membrane, and disruption of the mitochondrial processes of oxidative phosphorylation, with consequent ATP deficiency [20,21,22]. This leads to increased mucosal permeability [23], which facilitates the entry and actions of luminal factors, such as dietary macromolecules, bile acids, components of pancreatic juice, and bacteria, activating the inflammatory cascade [20,21,22].

Amongst luminal aggressors, intestinal bacteria are the main neutrophil chemoattractants. Several studies [24] show that antimicrobials (tetracycline, kanamycin, metronidazole or neomycin plus bacitracin) attenuate NSAID-enteropathy, thus supporting further the pathogenic role of enteric bacteria. Additional, albeit indirect, support to the role of gut bacteria in the pathogenesis of NSAID-enteropathy, is represented by the similarity between indomethacin-induced intestinal damage and

Crohn's disease (CD). Not only are the lesions both macro- and microscopically similar, but are they also sensitive to the same drugs (e.g. sulphasalazine, corticosteroids, immunosuppressants and antibiotics) [25], at least in the experimental setting. A recent video capsule study [26] showed also that mesalazine granules were able to reduce naproxen-induced intestinal damage in patients with inflammatory arthropathies.

Early studies [27] showed that metronidazole (an antimicrobial targeting most Gram-negative and Gram-positive anaerobic bacteria [28]) is able to reduce inflammation and blood loss in patients taking NSAIDs, thus suggesting a therapeutic potential of antimicrobials in this clinical setting. However, potential adverse effects of systemic antimicrobials and the possible occurrence of drug resistance have so far precluded this interesting approach [24].

Rifaximin (4-deoxy-4'-methylpyrido[1',2'-1,2]imidazo [5,4-c]rifamycin SV) is a synthetic derivative of rifamycin, characterized by very low GI absorption, while retaining a broad spectrum of antibacterial activity [29,30,31]. Being virtually non-absorbed, its GI bioavailability is high, with fecal concentrations largely exceeding minimum inhibitory concentrations against pathogenic enterobacteria, while its scarce impact on extra-GI sites minimizes the risk of antimicrobial resistance and systemic adverse events [25]. Upon appreciation of the pathogenic role of gut flora in several GI diseases, the use of rifaximin has been extended from GI infections to hepatic encephalopathy, small intestine bacterial overgrowth and colonic diverticular disease [25,32]. The drug is also being investigated in the treatment of inflammatory bowel disease [33].

Since rifaximin does display all the characteristics of an ideal antibiotic for targeting enterobacteria [34], we felt it worthwhile to assess its ability to prevent NSAID-enteropathy in a rat model of indomethacin-induced enteropathy. To this aim, we selected the recently developed extended intestinal release (EIR) formulation, which contains microgranules of rifaximin, coated with a gastric acid-resistant polymer. This

formulation, under development also for the treatment of Crohn's disease, has been designed to bypass the stomach and release the microgranules directly in the intestine, thereby increasing the local concentration of rifaximin, and to maximize its therapeutic efficacy [33].

## **2. Methods**

### **2.1 Animals**

Experiments were performed on aged (40 week-old) male Wistar rats (500-600 g) (Harlan Laboratories, Udine, Italy). The animals were fed standard laboratory chow and tap water ad libitum, and were not employed for at least one week after their delivery to the laboratory. They were housed, three in a cage, in temperature-controlled rooms on a 12-h light cycle at 22-24°C and 50-60% humidity.

### **2.2 Experimental design**

Enteropathy was induced by indomethacin in accordance with the method previously developed in our laboratory [35]. The dose of indomethacin and duration of treatment were selected in order to obtain small bowel injuries mirroring those induced by NSAIDs in humans. To pursue this goal, non-fasted rats were treated for 14 days with indomethacin 1.5 mg/kg BID by intragastric route, suspended in 1% methylcellulose and administered in a volume of 0.3 ml/rat. This dose was previously shown to suppress COX-1 and COX-2 activity in rats by 97% and 98%, respectively [35] and to reduce inflammation in rat models of adjuvant arthritis [36] and carrageenan-induced paw edema [37].

The EIR formulation of rifaximin polymorph alpha (R-EIR 50 mg/kg BID) (Alfa Wassermann SpA, Bologna, Italy) was administered 1 hour before indomethacin for 14 days (suspended in 1% methylcellulose, 1 ml/rat). In a subgroup of animals, treatment



with rifaximin was initiated 7 days before starting indomethacin administration and continued for 14 days until the end of treatment with the NSAID. The dose of 50 mg/kg BID had been found to protect against enteropathy induced by indomethacin in a preliminary dose-response study (25, 50 and 100 mg/kg BID). In addition, the selected rifaximin dose was similar to that employed in previous studies in rats [38,39]. Twenty four hours after the last dose of test drugs, rats were anesthetized with chloral hydrate. Blood samples were collected by cardiac puncture from each animal for hemoglobin measurement. The whole GI tract was excised and samples of jejunum and ileum were snap frozen in liquid nitrogen and stored at -80°C for subsequent analysis of myeloperoxidase (MPO), tumor necrosis factor (TNF), malondialdehyde (MDA) and protein carbonyl levels. Samples of ileum were also processed for the evaluation of bacterial phyla abundance, as reported below. Other portions of tissues were fixed in 10% formalin for subsequent evaluation of microscopic damage.

Experimental groups were arranged as follows: **Group 1**: animals treated with vehicle (control, n=10); **Group 2**: animals treated with indomethacin 1.5 mg/kg BID (IND, n=15); **Group 3**: animals treated with indomethacin plus R-EIR (50 mg/kg BID) for 14 days (IND+R-EIR<sub>14</sub>, n=12); **Group 4**: pretreatment with R-EIR (50 mg/kg BID) for 7 days, followed by indomethacin co-treatment with R-EIR (50 mg/kg BID) for 14 days (IND+R-EIR<sub>21</sub>, n=12).

### 2.3 Microscopic assessment of intestinal damage

Histological evaluation of small bowel injury was carried out as previously described [35]. Upon removal, the small intestine was immediately injected with 10% formalin and left in the same fixative solution. After 30 min, it was opened along the anti-mesenteric border, cleaned of its fecal contents, and fixed again in 10% formalin for 24 h. In order to rule out any bias, intestinal tissue samples were taken in accordance to the following procedure: the full length of small intestine was measured; in the

jejunum, two specimens of 1.5-2 cm were taken 5 cm far from both the proximal and distal end of 81% of the total small bowel length; in the ileum, 1 cm of tissue proximal to the ileo-cecal valve was discarded and two specimens of 1.5-2 cm were taken at this edge as well as 5 cm from the first ileum sample.

Sections of jejunum and ileum were embedded into paraffin blocks and cut into 3 consecutive serial 7-8  $\mu\text{m}$  sections. The slices were cut at two different points of the block: two on the surface and three at a deeper level. Each slice was placed on a glass slide for staining with haematoxylin and eosin. Histological damage was assessed by two observers, blind to treatments, according to the score system adopted in our laboratory [35]. The intestinal damage was scored as reported in **Table 1**. Representative pictures, showing the histological appearance of type 1, 2 and 3 lesions of jejunum and ileum, are displayed in **Figure 1**.

#### 2.4 Evaluation of tissue myeloperoxidase levels

MPO, as a quantitative index to estimate the degree of intestinal wall infiltration by inflammatory polymorphonuclear cells, was assessed as described by Fornai et al. [35]. Specimens of small intestinal tissues (30 mg) were homogenized on ice with a polytron homogenizer (QIAGEN, Milan, Italy) in 0.6 mL of ice-cold lysis buffer (200 mM NaCl, 5 mM EDTA, 10 mM Tris, 10% glycerine, 1 mM phenylmethylsulfonyl fluoride, 1  $\mu\text{g}/\text{ml}$  leupeptin and 28  $\mu\text{g}/\text{ml}$  aprotinin (pH 7.4). The homogenate was centrifuged 2 times at 4°C for 15 min at 1,500 g. The supernatant was diluted 1:5 and used for determination of MPO concentration by means of an enzyme-linked immunosorbent assay (ELISA) (Hycult Biotech, Uden, Netherlands). The results were expressed as nanograms of MPO per milligram of intestinal tissue.

## 2.5 Evaluation of tissue TNF levels

Tissue levels of TNF, a potent inflammatory cytokine, whose intestinal production is increased dose-dependently by indomethacin [40] were measured as previously described [41]. Briefly, samples of jejunum and ileum, collected as reported above, were weighed, thawed, and homogenized in 0.4 ml of PBS (0.4 ml/20 mg of tissue), pH 7.2 at 4°C, and centrifuged at 10,000g for 5 min. Aliquots (100 µL) of the supernatants were then used for subsequent assay by means of a commercial ELISA kit (Abcam, Cambridge, UK). Tissue TNF levels were expressed as picograms per milligram of tissue.

## 2.6 Evaluation of tissue malondialdehyde levels

MDA concentration in intestinal tissues was determined to obtain quantitative estimates of membrane lipid peroxidation [35]. For this purpose, intestinal tissue was excised, weighed, minced by forceps, homogenized in 2 ml of cold buffer (Tris-HCl 20 mM, pH 7.4) using a polytron homogenizer (QIAGEN, Milan, Italy), and centrifuged at 1,500 g for 10 min at 4°C. Aliquots of supernatants were then used for subsequent assay procedures. Mucosal MDA concentrations were estimated using a colorimetric assay kit (Cayman Chemical, Ann Arbor, MI, U.S.A.). Results were expressed as nmoles of MDA per milligram of intestinal tissue.

## 2.7 Evaluation of protein oxidation levels

Oxidative stress can give rise to protein carbonyl derivatives, *via* a variety of mechanisms that include fragmentation and amine oxidation either due to metal catalysis or by hypochlorous acid. As a consequence, measurement of protein carbonyls as a marker of tissue injury has become popular [42]. In the rat intestine, the extent of protein oxidation was estimated using a colorimetric assay kit (Cayman

Chemical, Ann Arbor, MI, USA), according to Reznick & Packer [43]. Specimens of jejunum and ileum (30 mg) were homogenized on ice with a Polytron homogenizer (Qiagen, Milan, Italy) in 0.6 ml of ice-cold lysis buffer (RIPA buffer containing 1 µg/ml leupeptin, and 28 µg/ml aprotinin, pH 7.4). The homogenate was centrifuged at 4°C for 10 minutes at 1,600g. Aliquots (200 µL) of supernatants were then used for subsequent assay procedures. Results were expressed as nanomoles of carbonyl content per milligram of proteins.

## 2.8 Assessment of blood haemoglobin concentration

Haemoglobin analysis was performed on blood samples, collected as reported above, by means of Quantichrom Hemoglobin assay kit (Bioassay Systems, Hayward, CA, USA) and expressed as g/dL.

## 2.9 DNA extraction and metagenomic analysis of bacterial population in ileal tissue

DNA was extracted from 250 mg of ileal tissue using the QIAamp DNA Mini kit (Qiagen, Hildens, Germany) and following the manufacturer's instructions. The final elution volume was 200 µl, the DNA concentration was determined by absorbance at 260 nm (A260), and the purity was estimated by determining the A260/A280 ratio with a spectrophotometer. Extracted DNA was adjusted to a final concentration of 40 ng/µl. Genomic DNA from pure bacterial cultures was extracted using Wizard Genomic DNA Purification Kit (Promega Corporation, Wisconsin, USA) according to the manufacturer's instructions.

Total DNA extracted from ileal tissue was analyzed for the mucosal-associated microbiota through 16S rDNA metagenomics (MiSeq). Metagenomic analysis was performed with MiSeq, Illumina platform at GenProbio SRL (Parma, Italy). Amplicons of the V3-V4 bacterial 16S rRNA gene region were obtained and sequenced using the

Illumina MiSeq platform, according to Illumina specific protocols. The number of sequences and operational taxonomic units (OTUs) for each sample were calculated using Quantitative Insights Into Microbial Ecology software (QIIME, <http://qiime.org/scripts/version1.9.1>) and taxonomic classification on Silva v. 119 database was assessed.

### 2.10 Statistical analysis

Results are presented as mean  $\pm$  standard error of mean (S.E.M.). The statistical significance of data was evaluated by one way analysis of variance (ANOVA) followed by *post hoc* analysis by Student–Newman–Keuls test, and p values less than 0.05 were considered significant. All statistical calculations were performed using GraphPad Prism™ 3.0 software (GraphPad, San Diego, CA, USA).

## 3. Results

### 3.1 Mortality Rate

At the end of the treatment period, the group treated with indomethacin displayed a 13.3% mortality rate (**Table 2**). In both groups of animals treated with rifaximin (IND+R-EIR<sub>14</sub> or IND+R-EIR<sub>21</sub>) the mortality rate was lower (i.e. 8.3%), albeit not significantly (**Table 2**).

### 3.2 Macroscopic Appearance of the Intestine

Owing to the large extension of intestinal mucosal surface, it was quite difficult to perform a reliable quantitative estimation of the macroscopic injury elicited by indomethacin. However, qualitative inspection allowed to detect macroscopic alterations, including diaphragm-like strictures and multiple ulcerative lesions in

animals treated with this NSAID. By contrast, no appreciable macroscopic changes were evident in intestinal tissues from rats treated with indomethacin plus rifaximin.

### 3.3 Microscopic assessment of intestinal damage

#### 3.3.1 Effects of indomethacin

In the jejunum and ileum from control animals, microscopic examination did not reveal any type of lesion (**Figure 2 and 3**). Administration of indomethacin (1.5 mg/kg BID) for 14 days was associated with the occurrence of type 1, 2 and 3 lesions in both jejunum and ileum (**Figure 2 and 3**).

#### 3.3.2 Effects of rifaximin on indomethacin-induced intestinal damage

R-EIR alone did not cause any mucosal injury and did not modify any of study parameters (*data not shown*), with the sole exception of bacterial population.

In the jejunum from rats of groups IND+R-EIR<sub>14</sub> or IND+R-EIR<sub>21</sub> the rates of type I, type II or type III lesions were significantly decreased or not present at all, as compared with the group treated with IND alone (**Figure 2**). Likewise, in the ileum from animals of groups IND+R-EIR<sub>14</sub> or IND+R-EIR<sub>21</sub>, indomethacin-induced lesions displayed a significant decrease or were not evident at all, as compared with animals treated with indomethacin alone (**Figure 3**).

### 3.4 Tissue MPO levels

#### 3.4.1 Effects of indomethacin

MPO levels in jejunal specimens excised from control rats were 9.74 ng/mg of tissue. In animals treated with indomethacin (1.5 mg/kg BID) for 14 days, MPO concentrations

were significantly increased (**Figure 4A**). In the ileum, MPO concentration in control animals was 7.48 ng/mg of tissue, and the administration of indomethacin (1.5 mg/kg BID) for 14 days was associated with a significant increase in MPO (**Figure 4B**).

#### 3.4.2 Effects of rifaximin

In the jejunum from rats of groups IND+R-EIR<sub>14</sub> or IND+R-EIR<sub>21</sub>, tissue MPO levels were similar to those estimated in control rats, and significantly lower, as compared with MPO concentrations in jejunal tissues from indomethacin-treated animals (**Figure 4A**). Likewise, in the ileum from rats of groups IND+R-EIR<sub>14</sub> or IND+R-EIR<sub>21</sub>, there was a significant decrease in MPO concentration, as compared with animals treated with indomethacin alone (**Figure 4B**).

### 3.5 Tissue TNF levels

#### 3.5.1 Effects of indomethacin

TNF levels in jejunum from control rats accounted for 2.37 pg/mg of tissue. The administration of indomethacin (1.5 mg/kg BID) for 14 days was associated with a significant increase in TNF concentration (**Figure 5A**). In the ileum, tissue TNF levels in control rats were 2.09 pg/mg of tissue. In rats treated with indomethacin there was a significant increment of this cytokine (**Figure 5B**).

#### 3.5.2 Effects of rifaximin

Rats treated with IND+R-EIR<sub>14</sub> or IND+R-EIR<sub>21</sub> displayed a significant decrease in tissue TNF levels both in jejunum and ileum, compared with animals treated with

indomethacin alone, showing values not significantly different from those observed in control animals (**Figure 5A and B**).

### 3.6 Tissue MDA levels

#### 3.6.1 Effects of indomethacin

In the jejunum of control rats, MDA concentration was 28.23 nmol/mg of tissue. Animals treated with indomethacin (1.5 mg/kg BID) for 14 days displayed significant increments of tissue MDA concentrations (**Figure 6A**). In the ileum, MDA levels in tissue samples from control animals were 20.63 nmol/mg of tissue. These levels were significantly increased by indomethacin (**Figure 6B**).

#### 3.6.2 Effects of rifaximin

In animals of groups IND+R-EIR<sub>14</sub> or IND+R-EIR<sub>21</sub> a significant decrease in MDA levels was observed both in the jejunum and ileum, as compared with indomethacin alone, with values similar to those estimated in intestinal tissues from control animals (**Figure 6A and B**).

### 3.7 Protein carbonyl levels

#### 3.7.1 Effects of indomethacin

The tissue amounts of protein carbonyl in jejunum and ileum from control rats were 18.74 and 19.24 nmol/mg of proteins, respectively. The administration of indomethacin (1.5 mg/kg BID) for 14 days elicited a significant increase in protein carbonyl levels both in jejunum and ileum (**Figure 7A and B**).



### 3.7.2 Effects of rifaximin

In rats treated with IND+R-EIR<sub>14</sub> or IND+R-EIR<sub>21</sub>, there was a significant decrease in tissue protein carbonyl levels both in jejunum and ileum, with values not significantly different from those assessed in control tissues (**Figure 7A and B**).

### 3.8 Hemoglobin blood levels

Animals treated with indomethacin (1.5 mg/kg BID) for 14 days displayed a significant decrease in blood hemoglobin concentration, as compared with controls. In rats of groups IND+R-EIR<sub>14</sub> or IND+R-EIR<sub>21</sub>, hemoglobin levels were significantly higher than those measured in the group treated with indomethacin alone (**Figure 8**). Under rifaximin, however, the hemoglobin levels of indomethacin-treated rats were still lower than those of control animals, likely because upper GI bleeding was not affected by the antibiotic.

### 3.9 Abundance of Proteobacteria, Firmicutes and Bacteroidetes in the ileum

In control animals, the relative abundance of *Proteobacteria*, *Firmicutes* and *Bacteroidetes* was 10.4, 23.5 and 14.4%, respectively. Treatment with indomethacin (1.5 mg/kg BID) for 14 days was associated with an increase in the relative abundance of *Proteobacteria* and *Firmicutes* and a slight decrease in *Bacteroidetes* (**Figure 9**). In rats treated with IND+R-EIR<sub>14</sub>, the relative abundance of such phyla returned toward those observed in control animals, while R-EIR<sub>14</sub> alone did not exert significant effects (**Figure 9**).

#### 4. Discussion

Results of the present investigation clearly show that rifaximin administration along with indomethacin protects the small bowel from the damaging effect of this NSAID. Despite a previous, small study in guinea-pigs [44] reported a protective effect of this antibiotic on indomethacin-induced intestinal damage, the predictive value of the experimental model adopted (as well as the drug regimens) is of limited (if any) relevance to clinical settings.

The present study was conducted on aged rats, since ageing is a risk factor for NSAID-induced enteropathy [45,46]. Indeed, elderly patients could display altered basal conditions as a consequence of aging and/or co-morbidities and co-therapies. Moreover, our model was set up to mirror clinical practice with NSAID *chronic* administration in humans, and indeed the present indomethacin regimen caused small bowel alterations, such as diaphragm-like strictures and multiple erosive lesions, together with a decrease in blood hemoglobin, known to occur in patients receiving chronic NSAID therapy [12]. Of note, repeated administration of low dose (i.e. 3 mg/kg) indomethacin, besides mimicking regimens adopted in clinical practice, has been shown to ensure intraluminal indomethacin concentrations, high enough to elicit consistent small bowel mucosal damage [47].

The majority of experimental studies on NSAID-enteropathy have used single, high-dose indomethacin administration to induce mucosal damage. In these models, the injury pattern consists mainly of multiple, hemorrhagic lesions involving the full thickness of intestinal wall [48,49,50], a picture that differ greatly from the ones seen at enteroscopy or video capsule endoscopy in patients taking NSAIDs chronically [11,12,13]. Most importantly, these acute models of intestinal damage may be not suitable to evaluate the protective effect of poorly absorbed antibiotics, like rifaximin, which need at least 7-10 days to consistently affect intestinal bacterial load, composition and activity [51]. Last but not least, guinea-pig is not considered a

reference species to implement a model of NSAID-enteropathy. As matter of fact, guinea-pigs have been mostly used for *in vivo* or *in vitro* studies to evaluate the effect of indomethacin on intestinal neuromuscular functions [52,53,54], while *in vivo* models of enteropathy have been developed in rats or mice, including transgenic animals. All the above drawbacks strongly limit the translational value of the guinea-pig acute model and the respective results.

Over 40 years ago, Robert and Asano [55] showed for the first time that germ-free rats are resistant to the intestinal damaging effect of indomethacin, becoming sensitive again to such NSAID when mono-contaminated with *E. coli*. On the other hand, oral administration of indomethacin is followed by a time-dependent bacterial invasion of intestinal mucosa (with increase in both aerobic and anaerobic strains) [56], which is facilitated by the drug-induced increase in intestinal permeability that is also time-dependent [57]. Enterobacteria then trigger toll-like receptors, whose activation is followed by an increased mucosal expression of inflammatory cytokines [58]. This elicits neutrophil recruitment with subsequent release of proteases and reactive oxygen species (ROS) leading ultimately to mucosal injury [19].

In line with the above-outlined sequence of pathogenic events, we found that indomethacin did increase mucosal inflammation, as reflected by the increased MPO and TNF tissue concentrations, thus confirming previous findings [35,59]. Likewise, lipid and protein peroxidation, mirrored by elevated MDA and protein carbonyl levels, respectively, also increased after the NSAID administration.

Current prevention strategies to reduce the extent of damage in the upper GI tract are not effective in the lower GI one. While therapy with celecoxib (a non acidic, COX-2 selective inhibitor) is safer than that with conventional NSAIDs [7], the dose-dependent increase in the risk of severe CV events associated with long-term therapy with this class of drugs is of concern in patients with CV risk factors. New alternatives, including the use of selective and *poorly absorbed* antibiotics, like rifaximin, probiotics

or prebiotics, are therefore important avenues to explore with the aim of correcting the shift of intestinal microflora towards pro-inflammatory Gram-negative bacteria [19]. Although current clinical support to this view is still weak, therapeutic manipulation of luminal microecology is particularly attractive as a physiologic, non-toxic approach to prevent, if not to treat, NSAID enteropathy.

Being the prevalence of small intestine bacterial overgrowth (SIBO) high in patients on long-term NSAID therapy [60], the use of rifaximin appears to be an even more rational choice for prevention of NSAID-enteropathy. Indeed, this poorly absorbed antibiotic is very effective and widely adopted for treatment of SIBO [61,62], whose occurrence correlates with the severity of intestinal damage [60].

Our results demonstrate that rifaximin significantly prevents indomethacin-induced intestinal damage, as documented by macro and microscopic assessment as well as digestive bleeding. This entero-protective effect was associated with a decrease in tissue inflammation (i.e. MPO and TNF mucosal concentrations) and oxidative stress (i.e. MDA and protein carbonyl tissue levels). These findings are consistent with those obtained in our laboratories with diclofenac-enteropathy [63]. Under similar experimental conditions, rifaximin was also able to reduce the NSAID-induced increase in fecal calprotectin as well as to counterbalance the overexpression of TLR-4 and TLR-2 in the intestinal mucosa [63]. Along the same lines, a video capsule study in healthy volunteers [64] has recently shown an overall protective effect of rifaximin EIR on diclofenac-associated intestinal mucosal lesions. Interestingly enough, our experiments have shown that pre-treatment with rifaximin for 7 days prior to indomethacin administration does not add further protection in comparison to what observed when the antibiotic administration was started together with the NSAID, thus suggesting that a priming effect on enteric microflora is not needed. And indeed, the pivotal clinical trial [64] confirmed that rifaximin co-administration with NSAID is effective in affording intestinal protection. The clinical implications of these findings are important since pre-administration of a protective agent would delay the start

(and benefits) of anti-inflammatory therapy and its co-administration would improve compliance.

The entero-protective effect of rifaximin likely depends on its broad spectrum of antibacterial activity, including Gram-positive and Gram-negative bacteria, both aerobes and anaerobes [32]. More recent experimental studies [65,66] not only confirmed that rifaximin reduces the total bacterial load, but also modulates bacterial community composition, increasing the relative abundance of *Lactobacillaceae*. This peculiar property was associated with a reduction of intestinal inflammation and alterations in intestinal permeability [66]. Along the same lines, rifaximin co-treatment was able – under our experimental conditions – to counterbalance the inflammation as well as lipid and protein peroxidation induced by indomethacin in the rat small bowel. Rifaximin-induced changes in bacterial composition may also impact on indomethacin pharmacokinetics within the intestinal lumen via reduction of the cleavage of its aglicone by bacterial beta-glucuronidase [67,68]. This would decrease the drug uptake by enterocytes and, consequently, impair entero-hepatic circulation, which prolongs the mucosal noxious activity of the NSAID.

The anti-inflammatory activity of rifaximin could be either indirect (i.e. a consequence of its antimicrobial properties) or direct in nature. Indeed, besides the antibiotic activity, this drug is endowed with an intrinsic anti-inflammatory activity, which seems to be class-dependent. Rifamycins indeed inhibit human neutrophil functions [69,70] and early studies have indeed shown that intra-articular rifamycin is an effective compound in patients in chronic arthritides, like juvenile rheumatoid arthritis and ankylosing spondylitis [71]. This anti-inflammatory, which was mirrored in our study by a significant decrease in MPO (and TNF) tissue levels, could translate into a reduction of MPO-induced formation of indomethacin reactive metabolites [72].

Recent evidence points out that – besides non-antimicrobial activities – rifaximin displays also “eubiotic” properties. Indeed, in patients with inflammatory conditions (like inflammatory bowel disease, colonic diverticular disease or hepatic

encephalopathy), rifaximin - while not altering the overall structure of human colonic microbiota - increased the relative abundance of *Bifidobacteria* and *Lactobacilli* [73,74]. Similarly, our study found that rifaximin was able to counterbalance the increase in *Proteobacteria* and *Firmicutes* abundance induced by indomethacin administration. Recent investigations [75] found a marked increase in *Proteobacteria* in naproxen-treated rats and suggested that these microbial changes may contribute to NSAIS-induced intestinal damage.

Rifaximin in the prevention of NSAID-enteropathy should clearly used long-term. As for every drug used in the long-term, safety - besides efficacy - is of paramount importance. Rifaximin proved to be extremely safe, even when given continuously (at standard therapeutic doses) for 6 months and its minimal, if any, systemic absorption (not exceeding 1%) accounts for the adverse event profile, which overlapped that of placebo [76]. In addition, long-term studies in IBS patients have shown that there were no clinically relevant changes in bacterial sensitivity to other antibiotic classes, no emergence of pathogenic bacteria, no occurrence of opportunistic infections, and no alteration of the overall microbiota [77].

*In summary*, co-administration of rifaximin with indomethacin can prevent NSAID-induced small bowel damage. Although the mechanisms need to be further elucidated, other experimental [63] and clinical [64] studies lend support to the present conclusions and suggest that targeting enteric bacteria by a poorly absorbed antibiotic is an attractive therapeutic avenue for the prevention of NSAID-enteropathy [19].

### **Conflicts of Interest**

Corrado Blandizzi has occasionally been involved, as a speaker, in satellite symposia supported by Alfa Wassermann, the manufacturer of rifaximin.

Carmelo Scarpignato is member of the Advisory Board and of the Speakers' Bureau of Alfa Wassermann.

Cecilia Renzulli is an employee of Alfa Wassermann SpA.

The other authors have no conflict of interest to disclose.

## 5. References

- [1] Brooks PM, Day RO. Nonsteroidal anti-inflammatory drugs--differences and similarities. *N Engl J Med* 1991;324:1716-25.
- [2] Tramèr MR, Williams JE, Carroll D, Wiffen PJ, Moore RA, McQuay HJ. Comparing analgesic efficacy of non-steroidal anti-inflammatory drugs given by different routes in acute and chronic pain: a qualitative systematic review. *Acta Anaesthesiol Scand* 1998;42:71-79.
- [3] Aronson JK. *Meyler's Side Effects of Analgesics and Anti-Inflammatory Drugs*. Amsterdam: Elsevier; 2009.
- [4] Lanas A, Hunt R. Prevention of anti-inflammatory drug-induced gastrointestinal damage: benefits and risks of therapeutic strategies. *Ann Med* 2006;38:415-28.
- [5] Scarpignato C, Hunt RH. Nonsteroidal anti-inflammatory drug-related injury to the gastrointestinal tract: clinical picture, pathogenesis, and prevention. *Gastroenterol Clin North Am* 2010;39:433-64.
- [6] Scarpignato C, Pelosini I. Prevention and treatment of non-steroidal anti-inflammatory drug-induced gastro-duodenal damage: rationale for the use of antisecretory compounds. *Ital J Gastroenterol Hepatol* 1999;31 (Suppl 1):S63–72.
- [7] Scarpignato C, Lanas A, Blandizzi C, Lems WF, Hermann M, Hunt RH; International NSAID Consensus Group. Safe prescribing of non-steroidal anti-inflammatory drugs in patients with osteoarthritis - an expert consensus addressing benefits as well as gastrointestinal and cardiovascular risks. *BMC Med* 2015;13:55.
- [8] Silverstein FE, Graham DY, Senior JR, Davies HW, Struthers BJ, Bittman RM, Geis GS. Misoprostol reduces serious gastrointestinal complications in patients with rheumatoid arthritis receiving nonsteroidal anti-inflammatory drugs. A randomized, double-blind, placebo-controlled trial. *Ann Intern Med*

1995;123:241-9.

- [9] Laine L, Connors LG, Reicin A, Hawkey CJ, Burgos-Vargas R, Schnitzer TJ, et al. Serious lower gastrointestinal clinical events with nonselective NSAID or coxib use. *Gastroenterology* 2003;124:288-92.
- [10] Lanas A, Garcia-Rodriguez LA, Polo-Tomas M, Ponce M, Alonso-Abreu I, Perez-Aisa MA, et al. Time trends and impact of upper and lower gastrointestinal bleeding and perforation in clinical practice. *Am J Gastroenterol* 2009;104:1633-41.
- [11] Graham DY, Opekun AR, Willingham FF, Qureshi WA. Visible small-intestinal mucosal injury in chronic NSAID users. *Clin Gastroenterol Hepatol* 2005;3:55-9.
- [12] Maiden L, Thjodleifsson B, Theodors A, Gonzalez J, Bjarnason I. A quantitative analysis of NSAID-induced small bowel pathology by capsule enteroscopy. *Gastroenterology* 2005;128:1172-8.
- [13] Fujimori S, Gudis K, Takahashi Y, Seo T, Yamada Y, Ehara A, et al. Distribution of small intestinal mucosal injuries as a result of NSAID administration. *Eur J Clin Invest* 2010;40:504-10.
- [14] Goldstein JL, Eisen GM, Lewis B, Gralnek IM, Zlotnick S, Fort JG. Video capsule endoscopy to prospectively assess small bowel injury with celecoxib, naproxen plus omeprazole, and placebo. *Clin Gastroenterol Hepatol* 2005;3:133-41.
- [15] Goldstein JL, Eisen GM, Lewis B, Gralnek IM, Aisenberg J, Bhadra P, et al. Small bowel mucosal injury is reduced in healthy subjects treated with celecoxib compared with ibuprofen plus omeprazole, as assessed by video capsule endoscopy. *Aliment Pharmacol Ther* 2007;25:1211-22.
- [16] Wallace JL. Mechanisms, prevention and clinical implications of nonsteroidal anti-inflammatory drug-enteropathy. *World J Gastroenterol* 2013;19:1861-76.



- [17] Fujimori S, Takahashi Y, Tatsuguchi A, Sakamoto C. Omeprazole increased small intestinal mucosal injury in two of six disease-free cases evaluated by capsule endoscopy. *Dig Endosc* 2014;26:676-9.
- [18] Washio E, Esaki M, Maehata Y, Miyazaki M, Kobayashi H, Ishikawa H, et al. Proton pump inhibitors exacerbate NSAID-induced small bowel injury: A prospective, double-blind, randomized trial. *Clin Gastroenterol Hepatol* 2015, in press.
- [19] Scarpignato C. NSAID-induced intestinal damage: are luminal bacteria the therapeutic target? *Gut* 2008;57:145-148.
- [20] Smale S, Tibble J, Sigthorsson G, Bjarnason I. Epidemiology and differential diagnosis of NSAID-induced injury to the mucosa of the small intestine. *Best Pract Res Clin Gastroenterol* 2001;15:723-38.
- [21] Bjarnason I, Scarpignato C, Takeuchi K, Rainsford KD. Determinants of the short-term gastric damage caused by NSAIDs in man. *Aliment Pharmacol Ther* 2007;26:95-106
- [22] Higuchi K, Umegaki E, Watanabe T, Yoda Y, Morita E, Murano M, et al. Present status and strategy of NSAIDs-induced small bowel injury. *J Gastroenterol* 2009;44:879-88.
- [23] Bjarnason I, Takeuchi K. Intestinal permeability in the pathogenesis of NSAID-induced enteropathy. *J Gastroenterol* 2009;44 (Suppl 19):23-9.
- [24] Lanas A, Scarpignato C. Microbial flora in NSAID-induced intestinal damage: a role for antibiotics? *Digestion* 2006;73 (Suppl 1):136-50.
- [25] Scarpignato C, Pelosini I. Rifaximin, a poorly absorbed antibiotic: pharmacology and clinical potential. *Chemotherapy* 2005;51 (Suppl 1):36-66.
- [26] Rácz I, Szalai M, Kovács V, Regőczy H, Kiss G, Horváth Z. Mucosal healing effect of

- mesalazine granules in naproxen-induced small bowel enteropathy. *World J Gastroenterol* 2013;19:889-96.
- [27] Bjarnason I, Hayllar J, Smethurst P, Price A, Gumpel MJ. Metronidazole reduces intestinal inflammation and blood loss in non-steroidal anti-inflammatory drug induced enteropathy. *Gut* 1992;33:1204-8.
- [28] Freeman CD, Klutman NE, Lamp KC. Metronidazole. A therapeutic review and update. *Drugs* 1997;54:679-708.
- [29] Marchi E, Montecchi L, Venturini AP, Mascellani G, Brufani M, Cellai L. 4-Deoxyprido[1',2':1,2]imidazo[5,4-c]rifamycin SV derivatives. A new series of semisynthetic rifamycins with high antibacterial activity and low gastroenteric absorption. *J Med Chem* 1985;28:960-3.
- [30] Jiang ZD, DuPont HL. Rifaximin: in vitro and in vivo antibacterial activity - review. *Chemotherapy* 2005;51 (Suppl 1):67-72.
- [31] Calanni F, Renzulli C, Barbanti M, Viscomi GC. Rifaximin: beyond the traditional antibiotic activity. *J Antibiot (Tokyo)* 2014;67:667-70.
- [32] Scarpignato C, Pelosini I. Experimental and clinical pharmacology of rifaximin, a gastrointestinal selective antibiotic. *Digestion* 2006;73 (Suppl 1):13-27.
- [33] Prantera C, Lochs H, Grimaldi M, Danese S, Scribano ML, Gionchetti P; Retic Study Group (Rifaximin-EIR Treatment in Crohn's Disease). Rifaximin-extended intestinal release induces remission in patients with moderately active Crohn's disease. *Gastroenterology* 2012;142:473-81.
- [34] DuPont HL, Ericsson CD. Prevention and treatment of traveler's diarrhea. *N Engl J Med* 1993;328:1821-7.

- [35] Fornai M, Antonioli L, Colucci R, Pellegrini C, Giustarini G, Testai L, et al. NSAID-induced enteropathy: are the currently available selective COX-2 inhibitors all the same? *J Pharmacol Exp Ther* 2014;348:86-95.
- [36] Blackham A, Burns JW, Farmer JB, Radziwonik H, Westwick J. An X-ray analysis of adjuvant arthritis in the rat. The effect of prednisolone and indomethacin. *Agents Actions* 1977;7:145-51.
- [37] Amann R, Schuligoi R. Inhibition of carrageenan-induced edema by indomethacin or sodium salicylate does not prevent the increase of nerve growth factor in the rat hind paw. *Neurosci Lett* 2000;278:173-6.
- [38] Miglioli PA, Allerberger F, Calabrò GB, Gaion RM. Effects of daily oral administration of rifaximin and neomycin on faecal aerobic flora in rats. *Pharmacol Res* 2001;44:373-5.
- [39] Harputluoglu MM, Demirel U, Gul M, Temel I, Gursoy S, Selcuk EB, et al. Effects of rifaximin on bacterial translocation in thioacetamide-induced liver injury in rats. *Inflammation* 2012;35:1512-7.
- [40] Bertrand V, Guimbaud R, Tulliez M, Mauprivez C, Sogni P, Couturier D, et al. Increase in tumor necrosis factor-alpha production linked to the toxicity of indomethacin for the rat small intestine. *Br J Pharmacol* 1998;124:1385-94.
- [41] Antonioli L, Fornai M, Colucci R, Ghisu N, Da Settimo F, Natale G, et al. Inhibition of adenosine deaminase attenuates inflammation in experimental colitis. *J Pharmacol Exp Ther* 2007;322:435-42.
- [42] Dalle-Donne I, Rossi R, Giustarini D, Milzani A, Colombo R. Protein carbonyl groups as biomarkers of oxidative stress. *Clin Chim Acta* 2003;329:23-38.
- [43] Reznick AZ, Packer L. Oxidative damage to proteins: spectrophotometric method for carbonyl assay. *Methods Enzymol* 1994;233:357-63.

- [44] Ciobanu L, Taulescu M, Prundus R, Diaconu B, Andreica V, Catoi C, et al. Effects of rifaximin on indomethacin-induced intestinal damage in guinea-pigs. *Eur Rev Med Pharmacol Sci* 2014;18:344-51.
- [45] Lanas A, Goldstein JL, Chan FK, Wilcox CM, Peura DA, Li C, Sands GH, et al. Risk factors associated with a decrease  $\geq 2$  g/dL in haemoglobin and/or  $\geq 10\%$  haematocrit in osteoarthritis patients taking celecoxib or a nonselective NSAID plus a PPI in a large randomised controlled trial (CONDOR). *Aliment Pharmacol Ther* 2012;36:485-92.
- [46] Watanabe T, Tanigawa T, Nadatani Y, Nagami Y, Sugimori S, Okazaki H, et al. Risk factors for severe nonsteroidal anti-inflammatory drug-induced small intestinal damage. *Dig Liver Dis* 2013;45:390-5.
- [47] Nygård G, Anthony A, Khan K, Bounds SV, Caldwell J, Dhillon AP, et al. Intestinal site-dependent susceptibility to chronic indomethacin in the rat: a morphological and biochemical study. *Aliment Pharmacol Ther* 1995;9:403-10.
- [48] Gyenge M, Amagase K, Kunimi S, Matsuoka R, Takeuchi K. Roles of pro-angiogenic and anti-angiogenic factors as well as matrix metalloproteinases in healing of NSAID-induced small intestinal ulcers in rats. *Life Sci* 2013;93:441-447.
- [49] Abimosleh SM, Tran CD, Howarth GS. Emu oil reduces small intestinal inflammation in the absence of clinical improvement in a rat model of indomethacin-induced enteropathy. *Evid Based Complement Alternat Med* 2013;2013:429706.
- [50] Yamamoto A, Itoh T, Nasu R, Nishida R. Sodium alginate ameliorates indomethacin-induced gastrointestinal mucosal injury via inhibiting translocation in rats. *World J Gastroenterol* 2014;20:2641-52.
- [51] Testa R, Eftimiadi C, Sukkar GS, De Leo C, Rovida S, Schito GC, et al. A non-

absorbable rifamycin for treatment of hepatic encephalopathy. *Drugs Exp Clin Res* 1985;11:387-92.

- [52] Kubota M, Ito Y, Domae M. Actions of prostaglandins and indomethacin on the electrical and mechanical properties of smooth muscle cells of the guinea-pig ileocecal junction. *Pflugers Arch* 1982;394: 347-54.
- [53] Nakahata N, Ono T, Nakanishi H. Possible involvement of a product of the 5-lipoxygenase pathway in mediation of indomethacin-induced inhibition of cholinergic transmission in guinea-pig ileum. *Eur J Pharmacol* 1984;104:133-8.
- [54] Shahbazian A, Schuligoi R, Heinemann A, Peskar BA, Holzer P. Disturbance of peristalsis in the guinea-pig isolated small intestine by indomethacin, but not cyclo-oxygenase isoform-selective inhibitors. *Br J Pharmacol* 2001;132:1299-309.
- [55] Robert A, Aano T. Resistance of germ free rats to indomethacin-induced lesions. *Prostaglandins* 1977;14:331-41.
- [56] Takeuchi K, Yokota A, Tanaka A, Takahira Y. Factors involved in upregulation of inducible nitric oxide synthase in rat small intestine following administration of nonsteroidal anti-inflammatory drugs. *Dig Dis Sci* 2006;51:1250-9.
- [57] Wright MR, Davies NM, Jamali F. Toxicokinetics of indomethacin-induced intestinal permeability in the rat. *Pharmacol Res* 1997;35:499-504.
- [58] Watanabe T, Higuchi K, Kobata A, Nishio H, Tanigawa T, Shiba M, et al. Non-steroidal anti-inflammatory drug-induced small intestinal damage is Toll-like receptor 4 dependent. *Gut* 2008;57:181-7.
- [59] Takeuchi K, Tanaka A, Ohno R, Yokota A. Role of COX inhibition in pathogenesis of NSAID-induced small intestinal damage. *J Physiol Pharmacol* 2003;54 (Suppl 4): 165-82.
- [60] Muraki M, Fujiwara Y, Machida H, Okazaki H, Sogawa M, Yamagami H, et al. Role

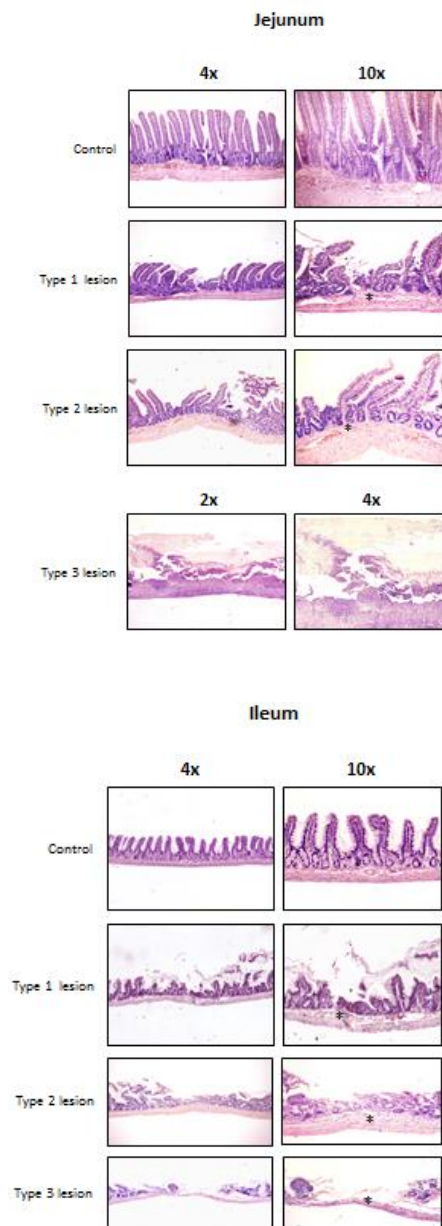
of small intestinal bacterial overgrowth in severe small intestinal damage in chronic non-steroidal anti-inflammatory drug users. *Scand J Gastroenterol* 2014;49:267-73.

- [61] Scarpignato C, Gatta L. Commentary: Towards an effective and safe treatment of small intestine bacterial overgrowth. *Aliment Pharmacol Ther* 2013;38:1409-10.
- [62] Shah SC, Day LW, Somsouk M, Sewell JL. Meta-analysis: antibiotic therapy for small intestinal bacterial overgrowth. *Aliment Pharmacol Ther* 2013;38:925-34.
- [63] Colucci R, Ghelardi E, Tirota E, Piccoli E, Sacco D, Antonioli L, et al. Rifaximin prevents enteric bacteria alterations and inflammation in a rat model of diclofenac-induced enteropathy. *United European Gastroenterol J* 2015; 3(5 Suppl): A314.
- [64] Scarpignato C, Dolak W, Lanas A, Matzneller P, Fogli MV, Grimaldi M, et al. Rifaximin for prevention of NSAID-associated intestinal lesions in healthy volunteers: a randomized, double-blind, placebo-controlled, video-capsule study. *Gastroenterology* 2015;148 (Suppl 1):S68.
- [65] Kim MS, Morales W, Hani AA, Kim S, Kim G, Weitsman S, et al. The effect of rifaximin on gut flora and Staphylococcus resistance. *Dig Dis Sci* 2013;58:1676-82.
- [66] Xu D, Gao J, Gilliland M 3rd, Wu X, Song I, Kao JY, et al. Rifaximin alters intestinal bacteria and prevents stress-induced gut inflammation and visceral hyperalgesia in rats. *Gastroenterology* 2014;146:484-96 .
- [67] LoGuidice A, Wallace BD, Bendel L, Redinbo MR, Boelsterli UA. Pharmacologic targeting of bacterial  $\beta$ -glucuronidase alleviates nonsteroidal anti-inflammatory drug-induced enteropathy in mice. *J Pharmacol Exp Ther* 2012;341:447-54.

- [68] Saitta KS, Zhang C, Lee KK, Fujimoto K, Redinbo MR, Boelsterli UA. Bacterial  $\beta$ -glucuronidase inhibition protects mice against enteropathy induced by indomethacin, ketoprofen or diclofenac: mode of action and pharmacokinetics. *Xenobiotica* 2014;44:28-35.
- [69] Spisani S, Traniello S, Martuccio C, Rizzuti O, Cellai L. Rifamycins inhibit human neutrophil functions: new derivatives with potential antiinflammatory activity. *Inflammation* 1997;21:391-400.
- [70] Spisani S, Traniello S, Onori AM, Rizzuti O, Martuccio C, Cellai L. 3-(Carboxyalkylthio) rifamycin S and SV derivatives inhibit human neutrophil functions. *Inflammation* 1998;22:459-69.
- [71] Caruso I. Twenty years of experience with intra-articular rifamycin for chronic arthritides. *J Int Med Res* 1997;25:307-17.
- [72] Ju C, Uetrecht JP. Oxidation of a metabolite of indomethacin (Desmethyldeschlorobenzoylindomethacin) to reactive intermediates by activated neutrophils, hypochlorous acid, and the myeloperoxidase system. *Drug Metab Dispos* 1998;26:676-80.
- [73] Maccaferri S, Vitali B, Klinder A, Kolida S, Ndagijimana M, Laghi L, et al. Rifaximin modulates the colonic microbiota of patients with Crohn's disease: an in vitro approach using a continuous culture colonic model system. *J Antimicrob Chemother* 2010;65:2556-65.
- [74] Ponziani FR, Scaldaferrri F, Petito V, Lopetuso L, Pecere S, Gerardi V, et al. on behalf of the GutLiver group. Rifaximin treatment increases *Lactobacillus* abundance in patients with different gastrointestinal and liver diseases. *UEG Journal* 2015;3 (Suppl):A138.

- [75] Syer SD, Blackler RW, Martin R, de Palma G, Rossi L, Verdu E, et al. NSAID enteropathy and bacteria: a complicated relationship. *J Gastroenterol* 2015;50:387-93.
- [76] Bass NM, Mullen KD, Sanyal A, Poordad F, Neff G, Leevy CB, et al. Rifaximin treatment in hepatic encephalopathy. *N Engl J Med* 2010;362:1071-81.
- [77] Pimentel M, Fodor AA, Golden P, Bortey E, Forbes QP. Characterization of Stool Microbiota in Subjects With IBS-D Receiving Repeat Treatments With Rifaximin in the TARGET 3 Study. *Gastroenterology* 2015;148 (Suppl 1):S-655.





A

B

**Figure 1.** Representative pictures showing the histological appearance of type 1, 2 and 3 lesions elicited by indomethacin in the jejunum (a) and ileum (b). Asterisks in the higher magnified pictures (right) indicate a significant thickening of the submucosal layer with the presence of inflammatory infiltration and vasodilation. In particular, in the jejunal type 3 lesion a marked thickening of the whole gut wall can be observed, requiring a lower (4x) magnification to be fully appreciated.

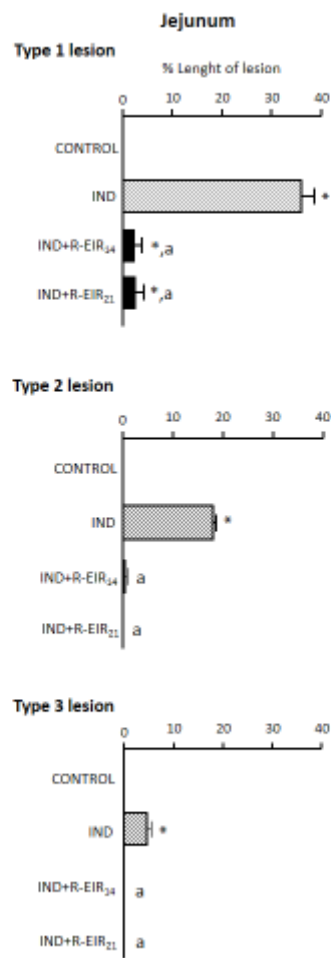


Figure 2

**Figure 2.** Histomorphometric analysis of damage in the jejunum of rats treated with vehicle (CONTROL), indomethacin (IND, 1.5 mg/kg BID), indomethacin plus rifaximin-EIR (IND+R-EIR<sub>14</sub>), or R-EIR (50 mg/kg BID) for 7 days followed by indomethacin plus rifaximin (IND+R-EIR<sub>21</sub>) for 14 days. Each column represents the mean  $\pm$  S.E.M. obtained from 10-13 animals. \* $P < 0.05$ ; significant difference vs CONTROL; <sup>a</sup> $p < 0.05$ , significant difference vs indomethacin alone.

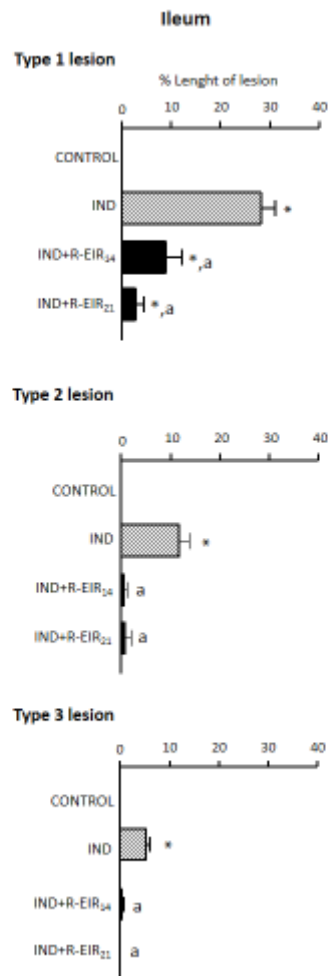


Figure 3

**Figure 3.** Histomorphometric analysis of damage in the ileum of rats treated with vehicle (CONTROL), indomethacin (IND, 1.5 mg/kg BID), indomethacin plus rifaximin-EIR (IND+R-EIR<sub>14</sub>), or R-EIR (50 mg/kg BID) for 7 days followed by indomethacin plus rifaximin (IND+R-EIR<sub>21</sub>) for 14 days. Each column represents the mean  $\pm$  S.E.M. obtained from 10-13 animals. \* $p$ <0.05; significant difference *versus* control; <sup>a</sup> $p$ <0.05, significant difference *versus* indomethacin alone.

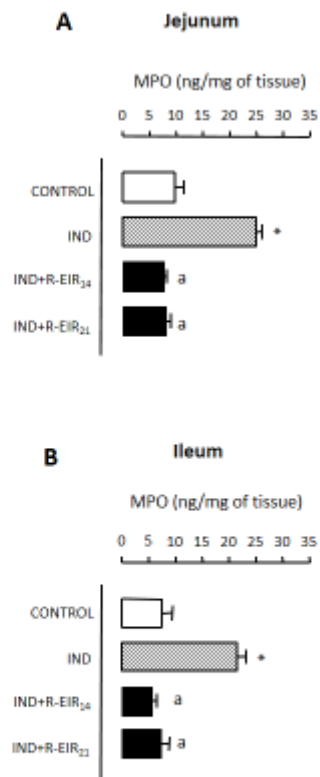


Figure 4

**Figure 4.** Effects of vehicle (CONTROL), indomethacin (IND, 1.5 mg/kg BID), indomethacin plus rifaximin-EIR (IND+R-EIR<sub>14</sub>), or R-EIR (50 mg/kg BID) for 7 days followed by indomethacin plus rifaximin (IND+R-EIR<sub>21</sub>) for 14 days on tissue myeloperoxidase (MPO) levels in the jejunum (**A**) or ileum (**B**). Each column represents the mean  $\pm$  S.E.M. obtained from 10-13 animals. \* $p < 0.05$ , significant difference *versus* control; <sup>a</sup> $p < 0.05$ , significant difference *versus* indomethacin alone.

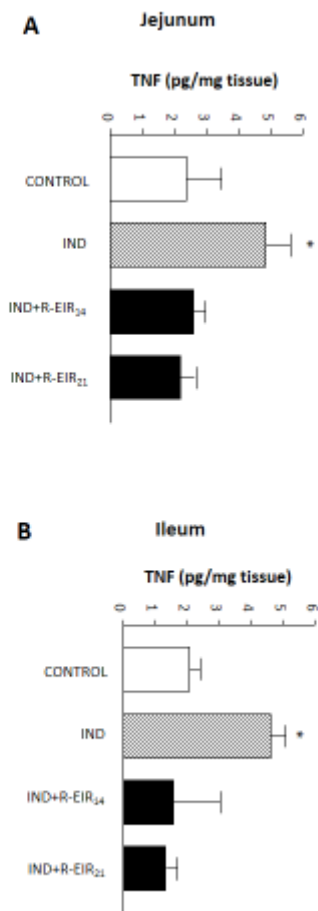


Figure 5

**Figure 5.** Effects of vehicle (CONTROL), indomethacin (IND, 1.5 mg/kg BID), indomethacin plus rifaximin-EIR (IND+R-EIR<sub>14</sub>), or R-EIR (50 mg/kg BID) for 7 days followed by indomethacin plus rifaximin (IND+R-EIR<sub>21</sub>) for 14 days on tissue tumor necrosis factor (TNF) in the jejunum (**A**) or ileum (**B**). Each column represents the mean  $\pm$  S.E.M. obtained from 10-13 animals. \* $p < 0.05$ , significant difference *versus* CONTROL

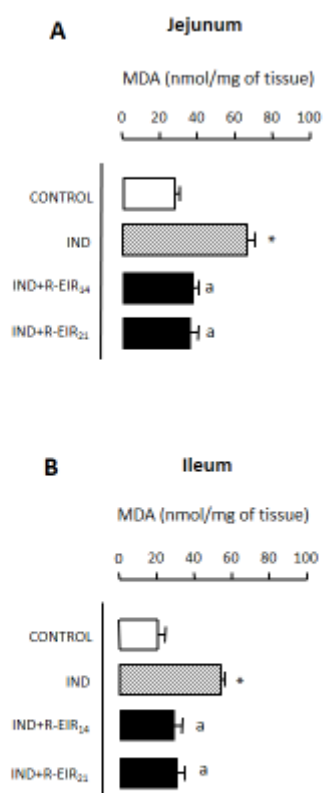


Figure 6

**Figure 6.** Effects of vehicle (CONTROL), indomethacin (IND, 1.5 mg/kg BID), indomethacin plus rifaximin-EIR (IND+R-EIR<sub>14</sub>), or R-EIR (50 mg/kg BID) for 7 days followed by indomethacin plus rifaximin (IND+R-EIR<sub>21</sub>) for 14 days on tissue malondialdehyde (MDA) in the jejunum (**A**) or ileum (**B**). Each column represents the mean  $\pm$  S.E.M. obtained from 10-13 animals. \* $p < 0.05$ , significant difference *versus* CONTROL; <sup>a</sup> $p < 0.05$ , significant difference *versus* indomethacin alone.

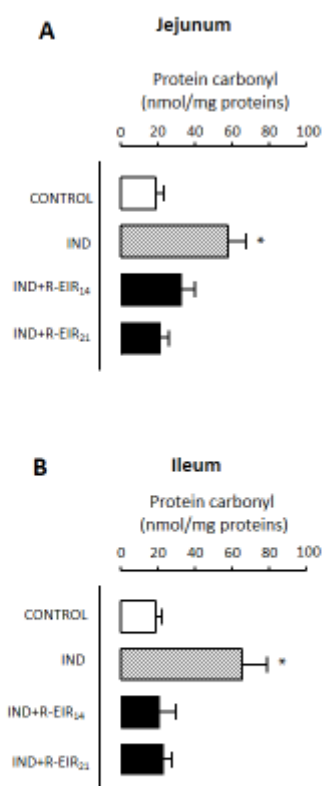


Figure 7

**Figure 7.** Effects of vehicle (CONTROL), indomethacin (IND, 1.5 mg/kg BID), indomethacin plus rifaximin-EIR (IND+R-EIR<sub>14</sub>), or R-EIR (50 mg/kg BID) for 7 days followed by indomethacin plus rifaximin (IND+R-EIR<sub>21</sub>) for 14 days on tissue protein carbonyl content in the jejunum **(A)** or ileum **(B)**. Each column represents the mean  $\pm$  S.E.M. obtained from 10-13 animals. \* $p < 0.05$ , significant difference *versus* CONTROL

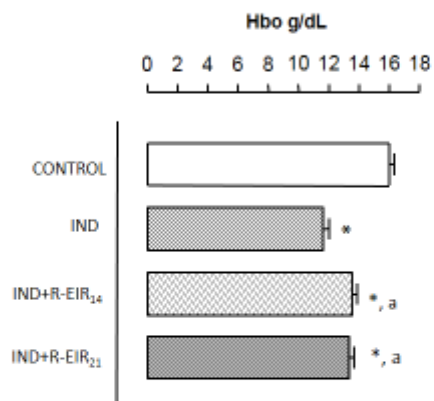


Figure 8

**Figure 8.** Effects of vehicle (CONTROL), indomethacin (IND, 1.5 mg/kg BID), indomethacin plus rifaximin-EIR (IND+R-EIR<sub>14</sub>), or R-EIR (50 mg/kg BID) for 7 days followed by indomethacin plus rifaximin (IND+R-EIR<sub>21</sub>) for 14 days on blood hemoglobin levels. Each column represents the mean  $\pm$  S.E.M. obtained from 10-13 animals. \* $p < 0.05$ , significant difference *versus* control; <sup>a</sup> $p < 0.05$ , significant difference *versus* indomethacin alone.



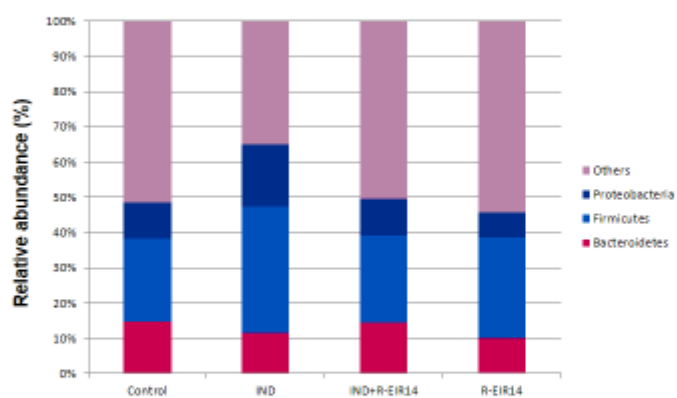


Figure 9

**Figure 9.** Relative abundance of *Proteobacteria*, *Firmicutes* and *Bacteroidetes* in ileal tissues obtained from rats treated with vehicle (CONTROL), indomethacin (IND, 1.5 mg/kg BID), indomethacin plus rifaximin-EIR (IND+R-EIR<sub>14</sub>), or R-EIR (50 mg/kg BID) for 7 days followed by indomethacin plus rifaximin (IND+R-EIR<sub>21</sub>) for 14 days.

**Table 1.** Microscopic criteria for quantitative estimation of the intestinal injury elicited by indomethacin

Type injury	1	<ul style="list-style-type: none"> <li>• Damage confined to the tunica mucosa</li> <li>• De-epithelization</li> <li>• Significant morphological alterations of the villi</li> </ul>
Type injury	2	<ul style="list-style-type: none"> <li>• Inflammatory infiltration in the submucosa, with thickening of the tunica muscularis or serosa</li> <li>• The morphologic framework of tunica mucosa is preserved</li> </ul>
Type injury	3	<ul style="list-style-type: none"> <li>• Damage involves the full thickness of intestinal wall</li> <li>• The morphologic patterns of tunicae are lost</li> <li>• Inflammatory reaction widely extended to the tunica serosa with a significant increase in thickness</li> </ul>

**Table 2.** Mortality rates in the groups of treatment

<b>Treatment</b>	<b>Dose (mg/kg/day)</b>	<b>N</b>	<b>Mortality (%)</b>
CONTROL	-	10	(0/10) 0
IND	3	15	(2/15) 13.3
IND+R-EIR <sub>14</sub>	3+100	12	(1/12) 8.3
IND+R-EIR <sub>21</sub>	3+100	12	(1/12) 8.3