

Deep Pulse Fractional CO₂ Laser Combined with a Radiofrequency System: Results of a Case Series

Giovanni Cannarozzo, Mario Sannino, Federica Tamburi, Andrea Chiricozzi, Rosita Saraceno, Cristiano Morini, and Steven Nisticò

Final publication is available from Mary Ann Liebert, Inc., publishers at <http://dx.doi.org/10.1089/pho.2014.3733>

Abstract

Objective: The purpose of this study was evaluation of the safety and efficacy of this new combined technology that adds deep ablation to thermal stimulation.

Background data: Minimally ablative or subablative lasers, such as fractional CO₂ lasers, have been developed in an attempt to achieve the same clinical results observed with traditional ablative lasers, but with fewer side effects. Despite being an ablative laser, the system used in this study is able to produce a fractional supply of the beam of light. Fractional ablation of skin is performed through the development of microscopic vertical columns surrounded by spared areas of epidermis and dermis, ensuring rapid wound healing and minimum down time. Simultaneous synchronized delivery of a radiofrequency (RF) current to the deeper layers of the skin completes the therapeutic scenario, ensuring an effective skin tightening effect over the entire treated area.

Methods: Nine adult patients were treated for wrinkles and acne scars using this new laser technology. An independent observer evaluated the improvement using a five point scale.

Results: All patients had good results in terms of improvement of skin texture, with mild and transitory side effects.

Conclusions: This novel combined system produced improvement in wrinkles and acne scars, with progressive enhancement of skin tone and elasticity

Introduction

Fractional resurfacing has become one of the most popular dermatologic surgical laser procedures.¹ In our extensive experience with lasers, the ablative resurfacing CO₂ laser has always been considered the gold standard for treating wrinkles, photoaging damage, and acne scars. However, this method also entails possible postoperative infectious complications (bacterial and viral infections) and uncomfortable side effects (persistent erythema, skin alterations, postinflammatory pigmentation, and possible atrophic scarring). Therefore, because of the complete vaporization of the epidermis and part of the dermis, as well as the associated risks and prolonged healing time, its use has been limited.²

The latest laser resurfacing techniques now exploit the various synergies offered by the different techniques.

The development of medical laser systems now guarantees dedicated and customized delivery pulse wavelengths, aimed at treating all the various skin pathologies in a completely safe, effective, and accurate manner.²

In the case of skin rejuvenation, the last generation CO₂ medical lasers are now providing patients with constantly reduced down times and excellent skin tightening results.³

In our experience with fractional CO₂ lasers, it is now possible to treat patients with various degrees of photodamage with reduced healing times and less operative and postoperative discomfort.⁴

This technique has proved its effectiveness on wrinkles, acne scars, and sun spots, because of an enhanced new collagen synthesis process with the new generation pulse waveforms and a synchronized bipolar radiofrequency current for enhancing skin tightening, elasticity, and smoothness.⁵

As shown recently, radiofrequency (RF) increases fibroblast activation and collagen synthesis that would add efficacy in terms of skin tightening to traditional fractional CO₂ laser treatments.^{4,5}

This method can be considered a valid response to the growing technological demand for high-quality results versus continuously reduced healing times.

Consequently, over the last 10 years, the rapid development of medical laser systems has made it possible to perform safer and more effective treatments on numerous injuries, even the most complex and severe. This has also been possible thanks to a more in-depth understanding of laser–tissue interactions and antiaging technologies, leading to the production of “clinically more flexible” systems, especially in dermatology.

The CO₂ systems are now called on to provide additional answers to the increasing demand for reduced down time coupled with excellent skin tightening.⁵ To date, CO₂ laser technology has been developed to improve fine lines, skin texture, and tone, and now this new challenge also includes significant skin tightening.³

The optimal clinical performance currently obtained with this new fractional laser system, which combines laser energy with bipolar radiofrequency, has enabled us to achieve excellent results.

The characteristics of the skin of patients who respond most positively to this laser technique are: yellow/grayish skin color, the presence of superficial pigmentation, fine lines, wrinkles, medium skin roughness, enlarged pores, impaired skin texture, and various kinds of acne scars.⁶

Moreover, this treatment seems to be particularly indicated and effective for the treatment of delicate areas such as the periocular area.⁷

Patients and methods

Nine patients (six women and three men) with Fitzpatrick skin types II and III, underwent three subsequent treatments with CO₂ plus RF. The age of the patients enrolled in our study was between 30 and 66 years old. Before starting therapy, written informed consent for therapy and images was obtained from all patients after clear medical explanations.

The inclusion criteria for this technique included: having had no topical exfoliating treatments for at least 2 months, not having taken photosensitizers drugs or oral retinoids for at least 8 months, not having had surgical treatments or therapies and local injections for at least 8 months, and not having had photorejuvenation treatments with other sources or treatments exploiting photodynamic therapy with aminolevulinic acid (ALA) for at least 1 year. We excluded patients with a positive history of keloid or collagen formation.

Four patients enrolled in the study had acne scars (rolling, boxcar, and ice-pick) and five had different degrees of photoaging in sun-exposed areas.

Clinical symptoms observed in most of our patients included atrophic acne scars, fine and deep wrinkles, dyschromia, elastosis, texture alterations, and actinic keratosis.

Because the laser treatment may induce the onset of herpes simplex in some patients, an antiviral prophylaxis was prescribed before treatment.

In order to ensure better patient compliance, a topical anesthetic cream (applied ~1h prior to treatment) and a light dynamic cooling (cool shot) system were applied before and during the treatment.

Also, digital clinical images were obtained before and after every session.

We used a combined CO₂ 10,600 nm laser-RF device (DEKA, M.E.L.A, Calenzano, Italy) equipped with a fractional scanning system (SmartXide2, DEKA, M.E.L.A, Florence) capable of producing fractional microablation and heat diffusion of the tissue. Parameters used were: power, 8–14W; spacing between dots, 500–1000 µm; number of pulses on same spot (stack), 2–4; pulse length, 600–1000ms; scanning area (square 15mm × 15 mm); and RF 20–40 W, 2–3 sec.

Results

Each patient underwent three treatment sessions with an interval time of 2 months; 80% of patients reported a mild burning sensation during treatment but immediate good clinical appearance. Immediately after surgery, several patients experienced slight, transient episodes of erythema and edema (more evident with treatment of the eye area).

At the end of treatment, compression with saline solution soaked gauze was applied for 20 min followed by an application of a cold emollient cream. These medications were also recommended for home use by patients. Small scabs showing a color change (to brown) appeared on the treated skin 3 days after treatment and fell off after 1 week, leaving a furfural desquamation.

Treated areas included the periocular area, forehead, perioral area, chin, and cheeks.

All patients were photographed in high resolution and were assessed by an independent physician on a five point scale for improvement of wrinkles and acne scars in comparison with baseline from 0 to 4, considering 0 as no improvement versus baseline, 1 as a moderate improvement, 2 as a good improvement, 3 as a very good improvement, and 4 as an excellent improvement.

Results obtained were excellent in five out of nine patients, and very good in three out of nine patients. One patient with boxcar acne scars obtained a good improvement after three sessions (Table 1 and Figs 1 and 2)

Discussion

The demand for the excellent clinical results of an ablative laser such as CO₂, with a lower risk of side effects associated with post-treatment and a shorter down time, has led to the development of a minimally ablative fractional laser with bipolar RF.

This new generation fractionated CO₂ laser is equipped with a fractional scanning system (HiScanDOT/RF) that creates microcolumns of thermal damage surrounded by healthy tissue.⁸ These columns of light are able to provide authentic vertical scaling of the epidermis, with a true microablation of the epidermis, and variable microthermal zones (MTZ) produced by the controlled heat released by the selected pulse (usually S-pulse for increased thermal release and D-pulse for greater thermal control with a reduced action on the dermal layers in the case of skin laxity) induce an immediate shrinkage of the tissues, promoting stimulation of growth factors and wound repair proteins that generate and reorganize new collagen fibers⁴ in the areas of healthy tissue in between the MTZs.

The areas of healthy tissue in between the MTZs, allow for faster tissue repair and an enhanced overall stimulation of the dermal component.

The great variety of combinations among the MTZs, pulse duration (dwell time) and power (measured in Watts) make this laser the gold standard for treating all skin types in a completely safe manner. The variety of waveform pulses possible with this new CO₂ laser and RF unit also makes this unit an effective tool for reducing healing times, postoperative pain, and side effects. At the same time, the system delivers a bipolar RF current that stimulates the tissue from the inside up to the reticular dermis, exploiting lower energy levels in order to prevent undesirable skin damage.

Normally, only 10% of the RF current penetrates the deeper skin layers as a result of the physiological impedance that this current encounters along the way.

A controlled laser emission delivery reduces the resistance of the epidermis and dermis because of hyperemia of the fine superficial vessels. This means that the RF current (+ 40% vs. standard techniques) can easily penetrate deeper into the reticular dermis, generating a more homogeneous biostimulation distribution from the inside because of the deeper generation of homogeneous and constant volumetric heat. In this way the tissue between the MTZs is also tightened, with excellent visible results. With this new method, a far more significant reduction in superficial erythema has also been observed at the 2–3-day follow-up compared with the standard CO₂ laser ablation. The limitation of the study was, in our opinion, the small number of patients; also a split face study would be needed to further assess the results shown.

Conclusions

This new fractional technique is highly acclaimed by everyone involved in skin rejuvenation of the face and neck.

This combined/synchronized system has proven its effectiveness on wrinkles and acne scars, with progressive enhancement of skin elasticity, because of the fibroblast activation and neocollagenogenesis, with great improvement in smoothness and reduction of roughness of the skin, in addition to the overall volumetric skin tightening.³

The healing time (disappearance of erythema) was between 3 and 7 days in almost all patients, and the duration of erythema did not exceed 5 days in any patients. No persistent edema was observed.

The equipment that combines laser energy with bipolar radiofrequency system ensures a significant reduction in side effects and postoperative complications (bacterial infections, atrophic scars, hypopigmentation, postinflammatory hyperpigmentation) compared with standard ablative treatments or other nonablative laser systems used for different aesthetic and dermatological conditions.⁹⁻¹⁵ Appropriate therapy should, however, be implemented for preventing the possibility of pre- and post-treatment herpes complications.

This synergic action allows for reduction of the overall down time, and provides an excellent skin tightening effect.³ It is particularly indicated and effective on very delicate areas, such as the cheeks, chin, and forehead, which are difficult to treat with traditional methods, or in cases of hypertrophic scars or ice-pick acne scars, or whenever the down time needs to be reduced.

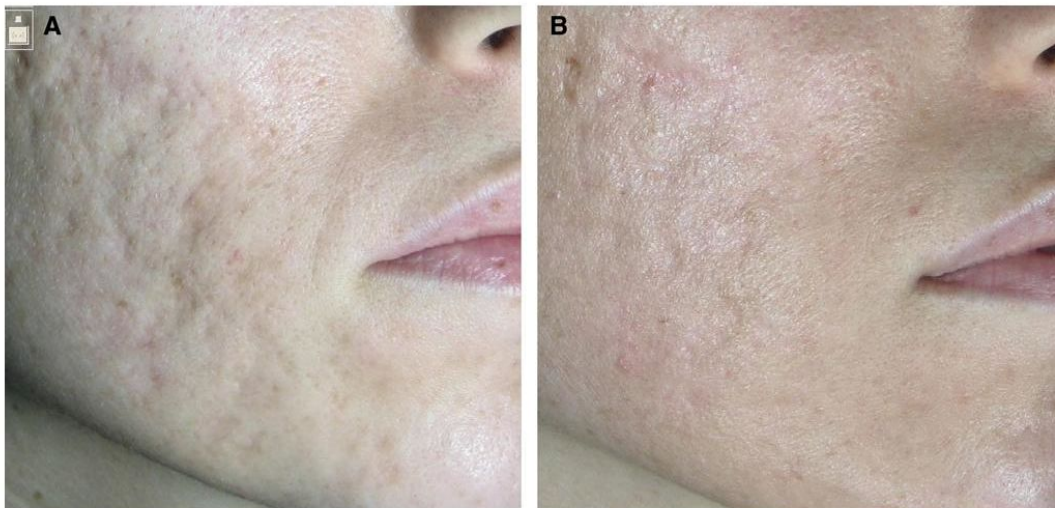
TABLE 1. PATIENTS' DEMOGRAPHICS, METHODS, RESULTS

<i>Patient, Sex, Age, Skin Type</i>	<i>Indication</i>	<i>Treated area</i>	<i>Laser energy, Time, RF energy</i>	<i>Improvement</i>
AG, F, 42, III	Acne scars (boxcar and ice pick)	Cheeks	9W, 700ms, 30W	3
DS, F, 66, II	Fine wrinkles	Cheeks, perioral area	12W, 700ms, 30W	4
AC, F, 30, III	Acne scars (rolling and boxcar)	Cheeks	10W, 600ms, 30W	4
FT, F 54, III	Deep wrinkles	Periocular area	11W, 600ms, 30W	4
ER F, 49, III	Deep wrinkles	Cheeks, perioral area	12W, 600ms, 40W	4
AT, M, 51, II	Fine wrinkles	Periocular area, Cheeks	12W, 600ms, 20W	4
PS, M, 43, III	Acne scars (boxcar)	Cheeks, Chin	12W, 700ms, 30W	3
LC, M, 38, III	Acne scars (boxcar)	Cheeks, Chin	14W, 700ms, 30W	3
SD, F, 41, III	Acne scars (boxcar and ice pick)	Cheeks	12W, 1000ms, 30W	2

FIG. 1. (A) Patient (DS, 66-year-old woman) with photoaging and fine wrinkles before treatment. (B) Excellent improvement after three monthly treatments. Parameters used were: 12 W, 700 μ m spacing, 1.2 ms timing, and 30 W per 3 sec radiofrequency RF.

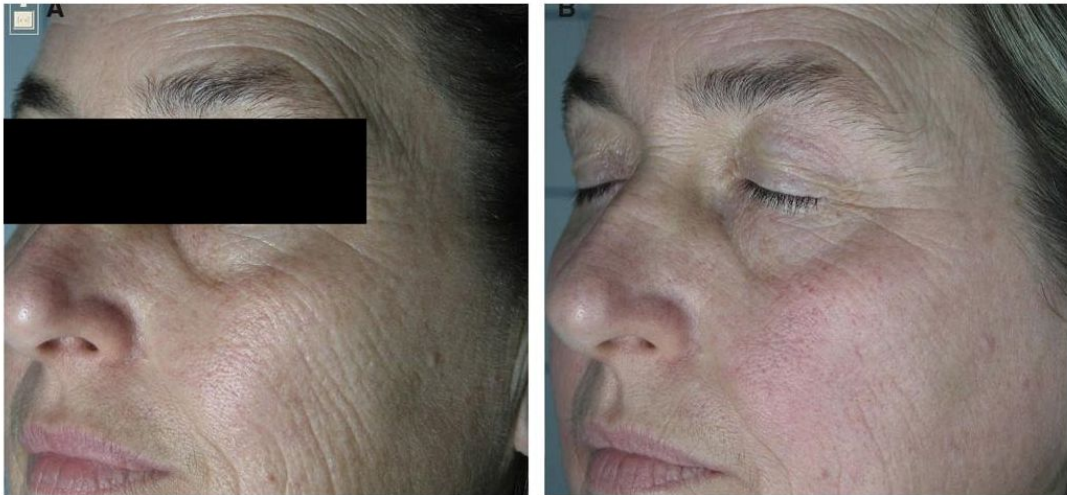

FIG. 2. (A) Acne scars (boxcar and icepick) before treatment in a 41-year-old patient. (B) Good improvement after three monthly treatments. Parameters used were: 12 W, 1000 μ m spacing, 1.5 ms timing and 30 W per 3 sec radiofrequency (RF).



References

1. Jih, M.H., and Kimyai-Asadi, A. (2008). Fractional photothermolysis: a review and update. *Semin. Cutan. Med. Surg.* 27, 63–71.
2. Tarijian, A.L., and Goldberg, D.J. (2011). Fractional ablative laser skin resurfacing: a review. *J. Cosmet. Laser Ther.* 13(6), 262–264.
3. Rahman, Z., MacFalls, H., Jiang, K. et al. (2009). Fractional deep dermal ablation induces tissue tightening. *Lasers Surg Med.* 41, 78–86.
4. Prignano, F., Campolmi, P., Bonan, P. et al. (2009). Fractional CO₂ laser: a novel therapeutic device upon photobiomodulation of tissue remodeling and cytokine pathway of tissue repair. *Dermatol. Ther.* 22, Suppl. 1, S 8–15.
5. Prignano, F., Bonciani, D., Campolmi, P., Cannarozzo, G., Bonan, P., and Lotti, T. (2011). A study of fractional CO₂ laser resurfacing: the best fluences through a clinical, histological, and ultrastructural evaluation. *J. Cosmet. Dermatol.* 10, 210–216.
6. Peterson, J.D., Palm, M.D, Kiripolsky, M.G., Guiha, I.C., and Goldman, M.P. (2011). Evaluation of the effect of fractional laser with radiofrequency and fractionated radiofrequency on the improvement of acne scars. *Dermatol. Surg.* 37, 1260–1267.
7. Bonan, P., Campolmi, P., Cannarozzo, G. et al. (2012) Eyelid skin tightening: a novel niche for fractional CO₂ rejuvenation. *J. Eur. Acad. Dermatol. Venereol.* 26, 186–938.
8. Hantash, B.M., Bedi, V.P., Kapadia, B. et al. (2007) In vivo histological evaluation of a novel ablative fractional resurfacing device. *Lasers Surg. Med.* 39, 14–18.
9. Nisticò, S.P., Saraceno, R., Stefanescu, S., and Chimenti, S. (2006). A 308-nm monochromatic excimer light in the treatment of palmoplantar psoriasis. *J. Eur. Acad. Dermatol. Venereol.* 20, 523–526.
10. Nisticò, S.P., Saraceno, R., Schipani, C., Costanzo, A., and Chimenti, S. (2009). Different applications of monochromatic excimer light in skin diseases. *Photomed. Laser Surg.* 27, 647–654.
11. Saraceno, R., Nisticò, S.P., Capriotti, E., and Chimenti S. (2009). Monochromatic excimer light 308 nm in monotherapy and combined with topical khellin 4% in the treatment of vitiligo: a controlled study. *Dermatol. Ther.* 22, 391–394.
12. Saraceno, R., Nisticò, S.P., Capriotti, E, de Felice, C., Rhodes, L.E., Chimenti, S. (2009). Monochromatic excimer light (308 nm) in the treatment of prurigo nodularis. *Photodermatol. Photoimmunol. Photomed.* 24, 43–45.
13. Nisticò, S., Chiricozzi, A., Saraceno, R., Schipani, C., and Chimenti, S. (2012). Vitiligo treatment with monochromatic excimer light and tacrolimus: results of an open randomized controlled study. *Photomed. Laser Surg.* 30, 26–30.
14. Nisticò, S.P., Saraceno, R., Chiricozzi, A., Giunta, A., Di Stefani, A., and Zerbinati N. (2013). UVA-1 Laser in the treatment of palmoplantar pustular psoriasis. *Photomed. Laser Surg.* 31, 434–438.
15. Chiricozzi, A., Pitocco, R., Saraceno, R., Nistico, S.P., Giunta, A., and Chimenti, S. (2014). New topical treatments for psoriasis. *Exp Op Pharmacother.* 15, 461-470