

Acute myocardial infarction following off label retrobulbar injection of desmopressin for non-arteritic anterior ischemic optic neuropathy (NAION). Causal correlation or coincidence?

Marco Di Paolo¹, Valentina Bugelli^{2,3,*}, Michele Figus⁴, Stefania Fornaro¹, Benedetta Guidi¹, Chiara Giannarelli⁵, Marco Tuccori⁶

Abstract: A 60-year-old man, apparently healthy with negative history for cardiovascular diseases, was hospitalized because of an unilateral sudden and painless severe visual loss. Diagnosis of NAION was made. Two separate and immediately consecutive injections of betamethasone (2 mg/0.5 mL) and desmopressin (2 mcg/0.5 mL) were performed in the retrobulbar space. Fifteen minutes later, the patient suddenly developed cold sweat, dyspnoea, thoracic pain and severe hypotension. Acute myocardial infarction was diagnosed by ECG. Desmopressin was the probable causative agent. Thrombotic events following intravenous or oral administration of desmopressin have been documented in the medical literature. To the best of our knowledge this is the first case in which a thrombotic event was associated with the retrobulbar route.

Retrobulbar desmopressin administration in patients with NAION can be probably associated with AMI. Considering its invasiveness and the unproven benefit in the treatment of NAION, this therapeutic approach can not be currently recommended.

Key Words: forensic science, forensic pathology, acute myocardial infarction, coronary thrombosis, desmopressin, non-arteritic anterior ischemic optic neuropathy.

INTRODUCTION

Off-label use of a drug refers to the administration of a registered medicine in a clinical setting or for achieving a therapeutical goal that are not disclaimed in the summary of product characteristics. Examples include use in a indication, patient age range, dose or route, different to that approved by regulatory authorities [1].

Studies in the United States have shown that off-label use may account for approximately 20% of prescriptions, or 150 million prescriptions per year [2]. While off label prescribing is not illegal, and may sometimes be clinically appropriate, it brings with it, a number of clinical, safety and ethical issues [3].

Non-arteritic anterior ischemic optic neuropathy (NAION) is a multifactorial disease with

1) University of Pisa, Forensic Medicine Unit, Department of Surgical, Medical, Molecular Pathology and Critical Care, Pisa, Italy

2) University of Molise, Dept. of Medicine and Health Sciences (DiMeS), Campobasso, Italy

* Corresponding author: University of Molise via De Sanctis, Dept. of Medicine and Health Sciences (DiMeS), 86100 Campobasso, Italy, Tel.: +393939124481, Fax: +39 0550763213, E-mail: vale.buge@gmail.com

3) University of Florence, Forensic Science Section, Dept of Medicine and Health Sciences, Firenze, Italy

4) University of Pisa, Ophthalmology Unit, Department of Surgical, Medical, Molecular Pathology and Critical Care, Pisa, Italy

5) University of Pisa, Internal Medicine Unit, Department of Surgical, Medical, Molecular Pathology and Critical Care, Pisa, Italy

6) University of Pisa, Laboratory of Pharmacovigilance, Division of Pharmacology and Chemotherapy, Pisa, Italy

several risk factors including diabetes, hypertension and hypercholesterolemia [4]. Other associations have been suggested or identified, including nocturnal hypotension, anemia, hyperhomocysteinemia, obstructive sleep apnea syndrome, and some coagulopathies [5]. Most cases of NAION occurs in patients older than 55 years. The majority have underlying systemic vascular disease, although this may be undiagnosed at the time of onset [6].

Small vessel circulatory insufficiency of the optic nerve head is the most widely accepted pathophysiology of NAION, but the location of the associated vasculopathy and the mechanism of ischemia remain uncertain. NAION is characterized histologically by ischemia at the level of the prelaminar/laminar portions of optic nerve supplied by the circle of Zinn-Haller via short posterior ciliary arteries [7].

A number of treatments for NAION have been attempted, but the evidence of beneficial effects of some of these therapeutic approaches remains weak [8]. We describe a fatal case of acute myocardial infarction (AMI) in patients receiving retrobulbar injection of bethametasone and desmopressin for the treatment of NAION. Notably, clinicians managing the present case adopted an off-label use of a drug without approval of the Ethics Committee. Due to the ethical and legal implication, the present case was evaluated by the Unit of Forensic Medicine in collaboration with the Unit of Adverse Drug Reaction Monitoring.

CASE REPORT

A 60-year-old man, apparently healthy with no history of cardiovascular diseases, was hospitalized because of an unilateral sudden and painless severe visual loss (20/200), on waking in the morning. The optic disc appeared hyperaemic and oedematous, with a focal severe swelling. Relative inferior altitudinal scotoma was present at visual field examination. The patient presented with erythrocyte sedimentation rate 20 mm/h and normal levels of plasma fibrinogen and C-reactive protein. The diagnosis of NAION was made. Two separate and immediately consecutive injections of betamethasone (2 mg/0.5 mL) and desmopressin (2 mcg/0.5 mL) were performed in the retrobulbar space. The administration of any pre-treatment medication, or cardiovascular examination are not documented. In the patient medical records, the total volume of the injections and the size of the needle used are not specified. The procedure was technically uncomplicated without any monitoring in progress during injections such as ECG, peripheral oxygen saturation, or blood pressure measurement. About twenty minutes later, the patient suddenly developed cold sweat, dyspnoea, thoracic pain, severe hypotension and ST segment elevation. Acute myocardial infarction (AMI) was diagnosed in spite of cardiac troponin and CK-MB resulted negative. Although intensive supportive

care was started, the patient became unconsciousness and developed cardiac arrest. Despite cardiopulmonary resuscitation, the patient died of irreversible cardio-respiratory arrest after about thirty minutes from onset of symptoms.

Autopsy findings

Heart presented a normal shape and weight (350g); first tract of left anterior descending coronary artery showed an atherosclerotic narrowing complicated by thrombosis of the left anterior descending artery, located 2 cm after its origin.

Examination of the other organs was unremarkable, except for pulmonary edema and polyvisceral stasis. There was no evidence of increased orbital volume or sign of vagal compression secondary to retrobulbar haemorrhage.

Cardiac specimens were obtained from right ventricular free wall; ventricular septum (anterior and posterior); anterior, lateral, and posterior left ventricular free wall, and apex.

Histological examination of the heart (Ematossiline&Eosine, trichrome stain) showed absence of cardiac ischemic findings (such as elongation of sarcomeres, nuclei contraction band necrosis, myofiber eosinophilia, etc.).

Anterior descending coronary artery showed endoluminal thrombosis. At this level Ematossilin&Eosin, trichrome stain and immunofluorescence (IF) utilizing fluorescente-labeled antibodies to detect fibrinogen, have been performed.

Microscopic findings of endoluminal thrombus showed signs coherent a very recent age of coronary thrombus. It was composed by irregular platelets reticular, erythrocytes and granulocytes (Figs 1A and 1B). Immunofluorescence stain resulted positive for fibrinogen (Fig. 2).

RESULTS AND DISCUSSION

In the present case, an off label retrobulbar injection of desmopressin and betamethasone was followed by the development of AMI.

Diagnosis of AMI outcomes from a strong correlation among clinical, strumental and autoptic data. ECG was performed with a ST elevation, cardiac troponine and CK-MB were unremarkable just as microscopic myocardial examination. This result was expected in relation to a shorter period of survival.

It's important to remember that the death has been declared about fifty minutes after the beginning of the heart attack. Notoriously, this shorter period to determine myocardium alterations microscopically detectable.

Ematossilin&Eosin in addition to IF have been useful to individuate the typical components of an early

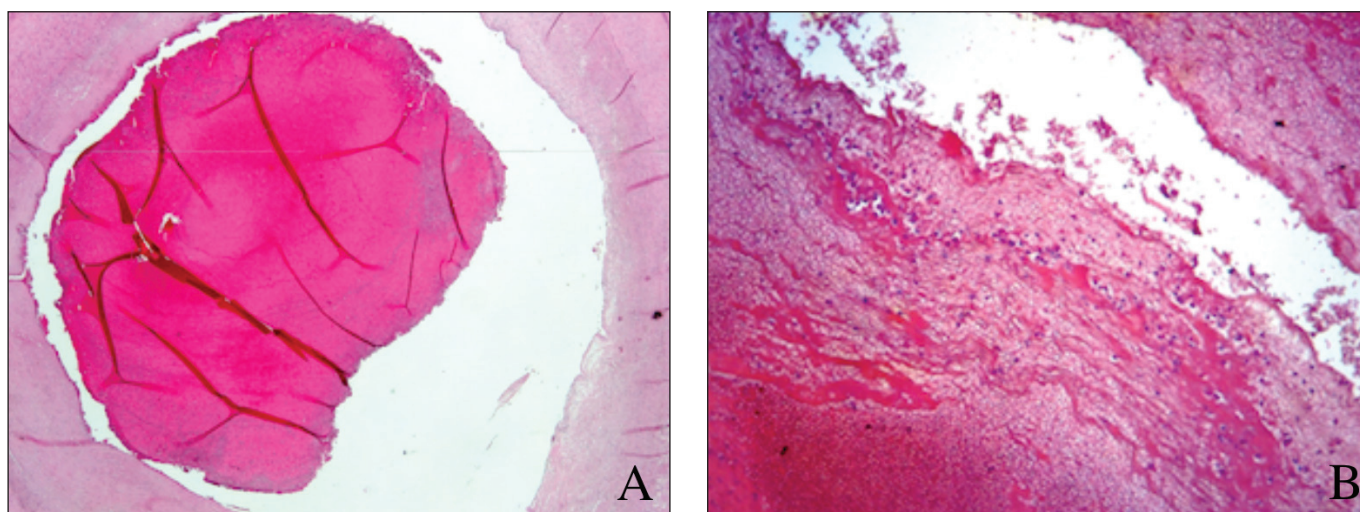


Figure 1. A. Fresh thrombus in the left anterior descending coronary artery (Ematossilin & Eosin 2X magnification). B. A particular of fresh thrombus in the left anterior descending coronary artery showing erythrocytes, fibrin and granulocytes (Ematossilin & Eosin 10 X magnification).

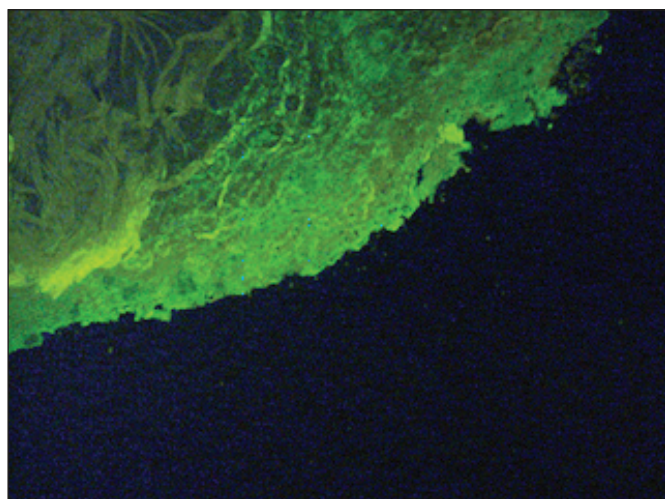


Figure 2. Immunofluorescence stain strongly positive for fibrin in coronary thrombus (10 X magnification).

stage thrombus, with particular regard for fibrinogen. The detection of this one was coherent with the chronology of the events [18].

The plausible temporal association between desmopressin administration and the development of AMI and the unlikely alternative etiology strongly support a causal relationship.

Desmopressin is a synthetic replacement for vasopressin, indicated for treatment of diabetes insipidus and nocturnal enuresis, due to its specific antidiuretic effect. It is also indicated for the treatment of mild haemophilia and type 1 von Willebrand (vW) disease, due to its ability of increasing plasma Factor VIII (FVIII) and vW Factor (vWF). It may be taken nasally, subcutaneously, intravenously, or as an oral or sublingual tablet [9, 10].

The potential for thrombotic events associated with the use of intravenous administration of desmopressin have been reported since the 80's and includes cerebrovascular accident, [11] coronary

syndromes [12] and myocardial infarction [13, 14]. A case of abdominal arterial thrombosis has been recently documented even after oral administration of desmopressin [15]. To the best of our knowledge this is the first case reported describing the development of a thrombotic event following retrobulbar administration of desmopressin in a patient with NAION.

It is important to note that in the present case desmopressin was administered locally in lower doses (2 mcg) as compared to that (0.19 mcg/Kg, 30 minutes infusion) administered intravenously in previously reported cases of desmopressin-induced AMI [13]. Notably, AMI was reported even after a single test dose of desmopressin (0.19 mcg/Kg) [14].

The mechanism of desmopressin-induced thrombotic events is probably represented by the increase of plasma levels of FVIII and vWF (3 to 5-fold both in healthy individuals and haemophilic patients), with the consequent increase of the risk of thrombotic complications [16]. It is reasonable to suppose that this risk of AMI would be particularly high in elderly and in patients with coronary heart disease.

Although in the present case the cardiovascular adverse event was facilitated by the asymptomatic arterial coronary disease of the patient, disclosed at autopsy, the most probable triggering cause of thrombotic event remains desmopressin. Among other potential causative agents, betamethasone and other corticosteroids have not usually associated with the development of thrombotic events. Finally, procedural complications (i.e. accidental endovenous injection with consequent thrombus development) have been ruled out by autoptic findings.

Since an evidence-based effective standard treatment for NAION is not available to date, most therapeutic approaches are empirical and include a wide range of agents presumed to act on thrombosis, on the blood vessels, on the disk edema, or supposed to have a neuroprotective effect. Among other proposed

treatment retrobulbar injection of corticosteroid and desmopressin represents an invasive approach, with potential local and systemic complications, which, to the best of our knowledge, has never been documented before. The rationale of using desmopressin in the treatment of NAION is uncertain and consists probably in experimental findings demonstrating that desmopressin induces ciliary artery relaxation in dog models via vasopressin-1 receptors through a mechanism which involves nitric oxide [17]. In turn, this would enhance vascular permeability, thus facilitating the reabsorption of optic edema. A similar vasodilation effect can be attributed to corticosteroids [17].

In the present case report desmopressin was used for the treatment of NAION although the

rationale for its use was weak and the request for the off label administration was never transmitted to the local Ethics Committee. Nevertheless, the observation derived from this reckless use allows to suggest that desmopressin is endowed with thrombotic potential even when administered retrobulbarly other than by the classic routes. This could be particularly true in patients with cardiovascular diseases. This treatment should be avoided until evidence of benefits (if any) will be available. Whenever effective, this off label use should be mandatorily authorized by an ethical committee.

Conflict of interest. The authors declare that there is no conflict of interest.

References

1. Gazarian M, Kelly M, McPhee JR, Graudins LV, Ward RL, Campbell TJ. Off-label use of medicines: consensus recommendations for evaluating appropriateness. *Med J Aust* 2006;185:544-548.
2. Stafford RS. Regulating off-label drug use - rethinking the role of the FDA. *N Engl J Med* 2008;358:1427-1429.
3. Blum R. Legal consideration in off-label medication prescribing. *Arch Intern Med* 2002;162:1777-1779.
4. Atkins EJ, Bruce BB, Newman NJ, Biousse V. Treatment of nonarteritic ischemic optic neuropathy. *Surv Ophthalmol* 2010;55:47-63.
5. Worrall BB, Moazami G, Odel JG, Behrens MM. Anterior ischemic optic neuropathy and activated protein C resistance. A case report and review of the literature. *J Neuroophthalmol* 1997;17:162-165.
6. Miller NR. Current concepts in the diagnosis, pathogenesis, and management of nonarteritic anterior ischemic optic neuropathy. *J Neuroophthalmol* 2011;31:e1-3.
7. Arnold AC. Pathogenesis of anterior ischemic optic neuropathy. *J Neuroophthalmol* 2003;23:157-163.
8. Toda M, Ayajiki K, Okamura T, Azuma I, Toda N. Desmopressin-induced dog ciliary artery relaxation. *Eur J Pharmacol* 1998;344:197-201.
9. Cvetković RS, Plosker GL. Desmopressin: in adults with nocturia. *Drugs*. 2005; 65(1):99-107.
10. Franchini M, Lippi G. The use of desmopressin in acquired haemophilia A: a systematic review. *Blood Transfus*. 2011;9(4):377-82.
11. [No author listed] Desmopressin and arterial thrombosis. *Lancet* 1989;1:938-939.
12. O'Brien JR, Green PJ, Salmon G, P. Weir, D. Colin-Jones, M. Arnold et al., Desmopressin and myocardial infarction. *Lancet* 1989;1:664-665.
13. Bond L, Bevan D. Myocardial infarction in a patient with hemophilia treated with DDAVP. *N Eng J Med* 1988;318:121.
14. Virtanen R, Kauppila M, Itala M. Percutaneous coronary intervention with stenting in a patient with haemophilia A and an acute myocardial infarction following a single dose of desmopressin. *Thromb Haemost* 2004;92:1154-6.
15. Schrijver EJM, Deenik W, Chon H, Koedam N, Spoelstra-de Man AM. An unusual case of abdominal arterial thrombosis in a young woman using desmopressin. *Clin Biochem* 2012;45:185-187.
16. Mannucci PM. Desmopressin (DDVAP) in the treatment of bleeding disorders: the first 20 years. *Blood* 1997;90:2515-2521.
17. Hayreh SS, Zimmermann MB. Non-arteritic anterior ischemic optic neuropathy: role of systemic corticosteroid therapy. *Graefes Arch Clin Exp Ophthalmol* 2008;246:1029-1046.
18. Yunoki K, Naruko T, Sugioka K, Inaba M, Itoh A, Haze K, Yoshiyama M, Ueda M. Thrombus Aspiration Therapy and Coronary Thrombus Components in Patients with Acute ST-elevation Myocardial Infarction. *J Atheroscl Thromb* 2013; 524-537.