

Denosumab in patients with aneurysmal bone cysts: A case series with preliminary results

Emanuela Palmerini¹, Pietro Ruggieri², Andrea Angelini², Stefano Boriani³, Domenico Campanacci⁴, Giuseppe M. Milano⁵, Marilena Cesari¹, Anna Paioli¹, Alessandra Longhi¹, Massimo E. Abate¹, Guido Scoccianti⁴, Silvia Terzi⁶, Giulia Trovarelli², Alessandro Franchi⁷, Piero Picci¹, Stefano Ferrari¹, Martina Piccini Leopardi¹ and Michela Pierini¹

Tumori Journal
2018, Vol. 104(5) 344–351
© Fondazione IRCCS Istituto
Nazionale dei Tumori 2018



Article reuse guidelines:
sagepub.com/journals-permissions
DOI: 10.1177/0300891618784808
journals.sagepub.com/home/tmj



Abstract

Purpose: Aneurysmal bone cyst (ABC) is a rare skeletal tumor usually treated with surgery/embolization. We hypothesized that owing to similarities with giant cell tumor of bone (GCTB), denosumab was active also in ABC.

Methods: In this observational study, a retrospective analysis of ABC patients treated with denosumab was performed. Patients underwent radiologic disease assessment every 3 months. Symptoms and adverse events were noted.

Results: Nine patients were identified (6 male, 3 female), with a median age of 17 years (range 14–42 years). Primary sites were 6 spine–pelvis, 1 ulna, 1 tibia, and 1 humerus. Patients were followed for a median time of 23 months (range 3–55 months). Patients received a median of 8 denosumab administrations (range 3–61). All symptomatic patients had pain relief and 1 had paresthesia improvement. Signs of denosumab activity were observed after 3 to 6 months of administration: bone formation by computed tomography scan was demonstrated in all patients and magnetic resonance imaging gadolinium contrast media decrease was observed in 7/9 patients. Adverse events were negligible. At last follow-up, all patients were progression-free: 5 still on denosumab treatment, 2 off denosumab were disease-free 11 and 17 months after surgery, and the last 2 patients reported no progression 12 and 24 months after denosumab interruption and no surgery.

Conclusions: Denosumab has substantial activity in ABCs, with favorable toxicity profile. We strongly support the use of surgery and/or embolization for the treatment of ABC, but denosumab could have a role as a therapeutic option in patients with uncontrollable, locally destructive, or recurrent disease.

Keywords

Aneurysmal bone cyst, denosumab, bone tumor, receptor activator of nuclear factor-kappa B ligand

Date received: 31 January 2018; accepted: 5 March 2018

Introduction

Aneurysmal bone cysts (ABCs) are benign bone tumors with a peak age at incidence in the first 2 decades of life.^{1–4} ABCs usually present with a growing mass, swelling, pain, and bone destruction^{1–4}; in some cases, the lesion is locally aggressive and might be associated with pathologic fractures.^{2,5} ABCs can involve metaphysis of appendicular bones and axial bones. In case of spinal localization, neurologic deficit may be caused by infiltration and compression of nerve roots.^{4,6–10} ABCs can occur as a primary tumor in about 70% of cases or as a secondary tumor in

¹Chemotherapy Unit, IRCCS, Istituto Ortopedico Rizzoli, Bologna, Italy

²Department of Orthopedics and Orthopedic Oncology, University of Padova, Padova, Italy

³IRCCS Galeazzi Orthopedic Institute, Milan, Italy

⁴Department of Orthopedic Oncology, Florence University, Florence, Italy

⁵Bambino Gesù Children's Hospital, Rome, Italy

⁶Department of Oncological Spine Surgery, Istituto Ortopedico Rizzoli, Bologna, Italy

⁷Pisa University, Pisa, Italy

Corresponding author:

Emanuela Palmerini, MD, Chemotherapy Unit, IRCCS Istituto Ortopedico Rizzoli, Department of Experimental, Diagnostic and Specialty Medicine (DIMES), Bologna University, Via Pupilli, 1-40136, Bologna, Italy.
Email: emanuela.palmerini3@unibo.it

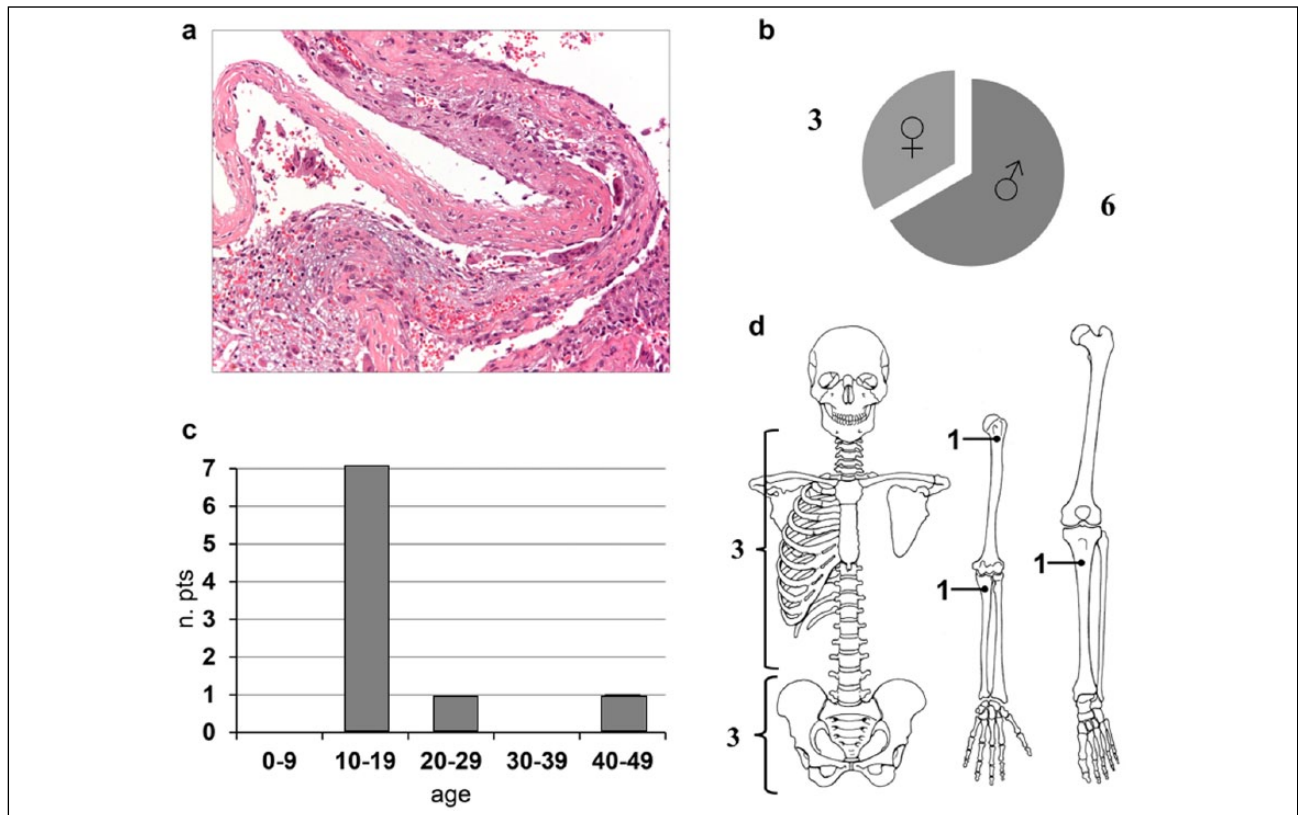


Figure 1. Blood-filled cavity separated by fibrous septa composed of spindle cells, inflammatory cells, multinucleated osteoclast-like giant cells, and fibroblast-like cells. Nuclear atypia is not present (a); gender distribution (b); age (c); tumor site (d).

30% of cases; the latter can be associated with osteoblastoma, giant cell tumor of bone (GCTB), chondroblastoma, fibrous dysplasia, or low-grade osteosarcoma.¹⁻⁴ Historically, the etiology of the lesion was attributed to an increase of venous vascular pressure in the bone, resulting in dilation of small vessels that lead to reabsorption of the matrix.² Recent studies have shown chromosomal rearrangements, such as translocations, resulting in the upregulation of *USP6* gene.^{2,5,11-15} *USP6* arrests the normal maturation of osteoblasts and increases the production of matrix metalloproteinase.¹² ABCs present as an expansive osteolytic lesion on X-rays, while magnetic resonance imaging (MRI) often shows septate cystic cavities with fluid-fluid levels due to blood sedimentation.¹⁻⁵ Histopathologically, the lesions consist of a blood-filled cavity separated by fibrous septa not lined by endothelial cells and composed of spindle cells, inflammatory cells, and multinucleated giant cells (MNGCs)² (Figure 1). Nuclear atypia is not present.² Biopsy is mandatory to exclude telangiectatic osteosarcoma^{2,16} and differential diagnoses with other lesions characterized by the presence of osteoclastic giant cells: giant cell tumor, brown tumor, and nonossifying fibroma.⁵ Treatment options for ABCs are represented by surgical resection or curettage, with bone graft or cement usually used to fill the defect,^{1,2,6,7,17,18} selective arterial embolization,^{2,6,8,9,19} sclerotherapy,^{2,20-22}

or radiotherapy.²³ However, all these therapeutic options are burdened with complications^{2,4,10,15,23} and innovative therapies are needed to treat ABCs.²⁴

Denosumab is a human monoclonal antibody that binds the cytokine receptor activator of nuclear factor-kappa B ligand (RANKL), which essentially initiates bone turnover.¹¹ RANKL inhibition blocks osteoclast maturation and function,¹¹ and denosumab has been successfully used in the treatment of osteoporosis,²⁵ skeletal metastases,²⁶ and more recently GCTB as well.²⁷ The satisfactory results with denosumab in the treatment of GCTB,²⁸ the immunohistochemical similarity and relationship between GCTB and ABCs,²⁹ and the activity of denosumab in a few cases of ABC²⁹ justify the hypothesis that denosumab may also have positive effects for ABC patients. Few series are reported in the literature about the results of the treatment of ABCs with denosumab.^{14,29,30}

The aim of this study was to evaluate the clinical and radiologic response of patients with ABCs treated with denosumab in case of inoperable tumors or when surgery was feasible, but associated with severe morbidity.

Methods

We performed a retrospective analysis of ABC patients treated off-label with denosumab, due to the impossibility

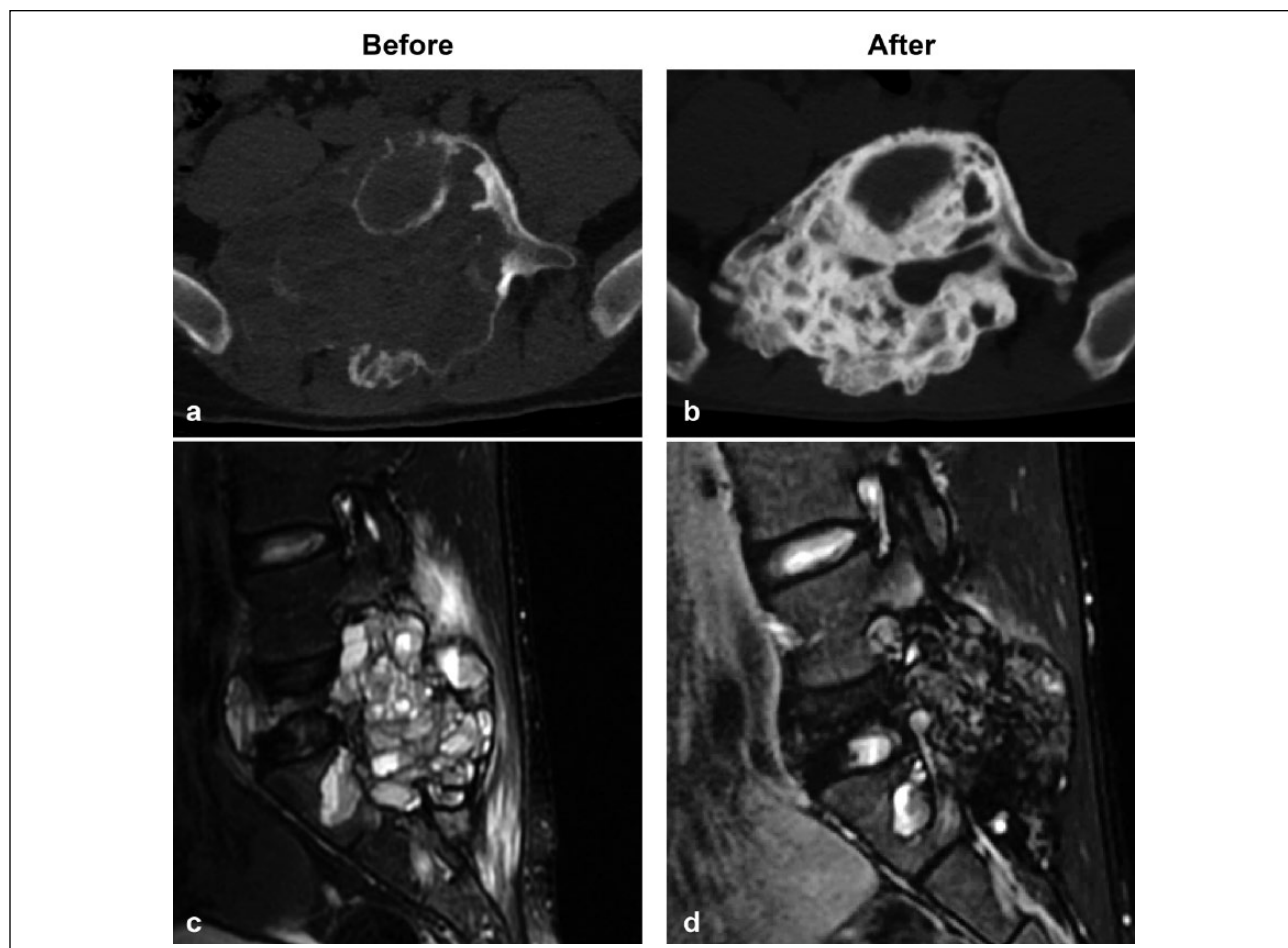


Figure 2. Denosumab-induced bone calcification on computed tomography scan (a, b) and contrast medium decrease on magnetic resonance imaging (c, d) in a 16-year-old boy with spine aneurysmal bone cyst. Baseline (a, c) and after 33 administrations of denosumab 120 mg (b, d).

to perform surgical treatment, when surgery was associated with severe morbidity, or when arterial embolization failed due to the absence of appropriate afferent arteries. The study was approved by the appropriate institutional review committee and meets the national guidelines. Denosumab was administered as a subcutaneous injection in the dose of 120 mg on days 1, 8, 15, 29, and every 4 weeks thereafter. To prevent hypocalcaemia, a daily supplementation of calcium 500 mg and vitamin D 400 IU was administered.⁹ Computed tomography (CT) scan and/or MRI disease assessment was performed at 3, 6, 9, and 12 months for all patients. All images were centralized and reviewed for the purpose of this study, with radiologic review not blinded to clinical information.

Denosumab was discontinued on the subject's decision to withdraw, for adverse side effects, or if the lesion was surgically removed. All clinical data were recorded from patient charts. We collected information on pain, symptoms, and adverse events associated with denosumab. Histologic response was assessed in patients undergoing surgical removal.

Results

From October 2012 to July 2015, 9 patients (6 male and 3 female) treated with denosumab for ABCs were identified. The median age was 17 years (range 14–42 years). The primary site was spine/pelvis in 6 cases, and ulna, tibia, and humerus in 1 case each. Two patients were surgically treated after preoperative denosumab administration. With a median follow-up of 23 months (range 3–55 months), patients received a median and mean of 8 and 21 denosumab administrations, respectively (range 3–61).

One patient was asymptomatic, whereas clinical improvement was observed in the remaining 8 patients: 7 patients with pain had relief/decrease of symptoms on the 11-point scale and 1 patient had paresthesia improvement. The radiologic outcome showed good responses after 3 to 6 months of denosumab: CT scan showed bone formation in all patients and MRI gadolinium contrast media decrease was seen in 7/9 patients. Sustained tumor control was demonstrated in all patients (RECIST does not apply, due to disease site within bone and substantial denosumab-induced calcification) (Figures 2–4).

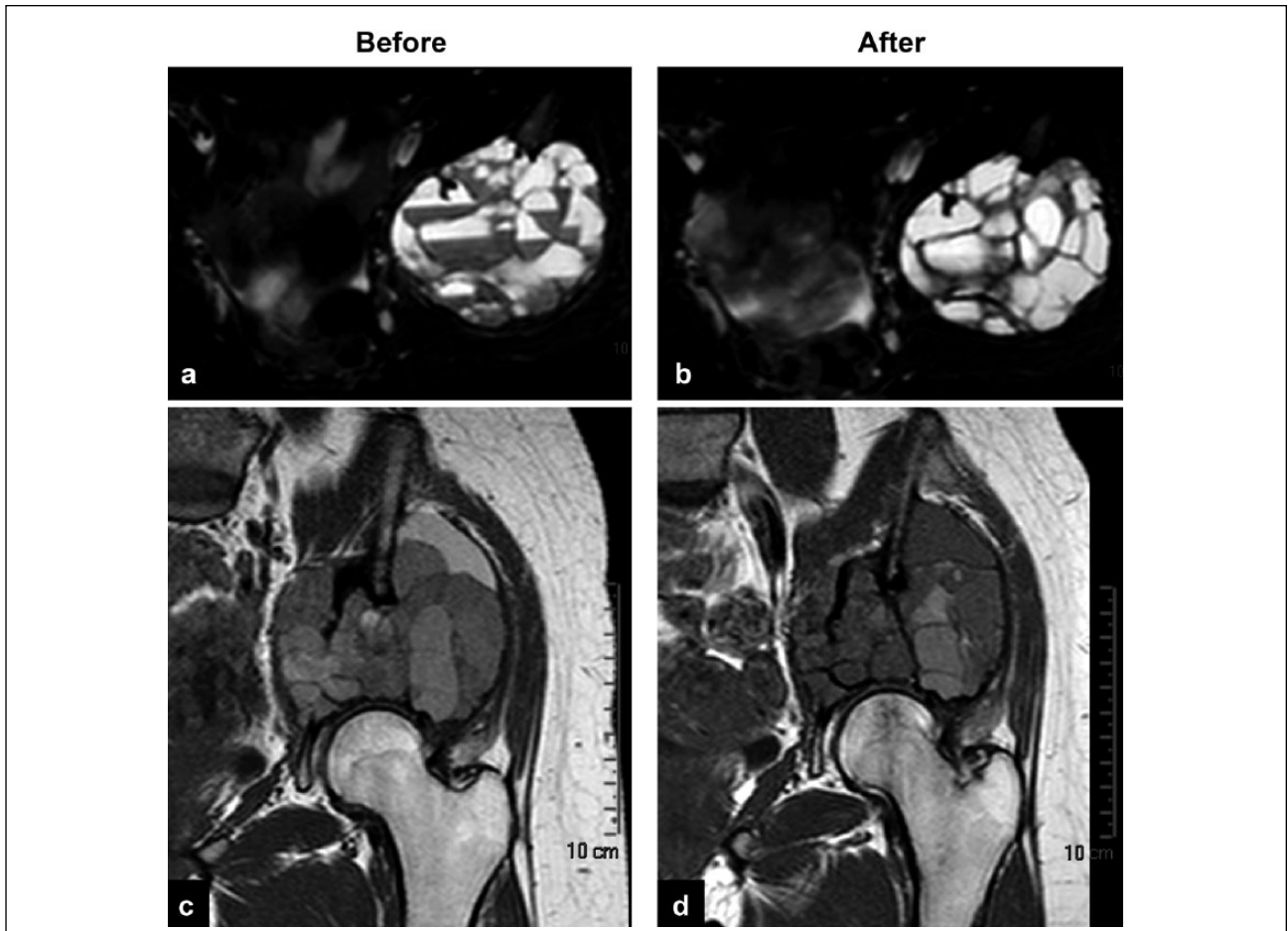


Figure 3. A 16-year-old girl with pelvic aneurysmal bone cyst presenting fluid–blood levels and contrast medium enhancement at baseline (a, c), both reduced after 9 administrations of denosumab (b, d).

Two patients, a 19-year-old man and a 17-year-old girl with proximal humerus and distal tibia ABCs, underwent surgery after 5 and 9 months of denosumab treatment. The humeral lesion had relapsed after previous surgery and sclerosants (3% polidocanol injection). Both lesions underwent curettage and bone filling. After curettage, the cavity was first filled with a gel and frozen with argon-helium cryoprobes (Endocare) as local adjuvant treatment; then bone grafting with morcelized allografts was performed. A plate fixation was applied at the humeral lesion; no fixation was performed at the tibia. Histologic complete response (i.e., disappearance of giant cell component) was demonstrated in both cases (Figure 5).

Side effects were observed in only one patient, who presented grade 1 vomiting (Table 1). None of the patients developed osteonecrosis of jaw (ONJ), nor were abnormal laboratory results observed.

At last follow-up, all patients were progression-free: 5 patients were still on denosumab treatment, 2 patients were disease-free 11 and 17 months after the curettage, while in the last 2 cases, 12- and 16-year-old patients, discontinuing denosumab after 8 months and 3 years,

respectively, no progression was documented 12 and 24 months after denosumab interruption and no surgery.

Discussion

ABCs are benign tumors with potential locally aggressive behavior, characterized by loculated blood-filled cystic areas. ABC lesions contain osteoclast-like MNGCs and fibroblast-like cells,^{1,24,31,32} similarly to GCTB.²⁴ Since osteoclasts are the only cells responsible for bone resorption, the MNGCs within GCTB and ABCs appear to be responsible for the osteolytic natures of these tumors.³³

Also, similar to GCTB, RANKL is highly expressed in stroma of ABCs and dictates the activation of MNGCs,³⁴ binding to RANK present on the surface of monocyte and macrophage lineage precursors.^{14,24-28,30,35,36} The RANK signalling pathway has an essential role in tumor progression.³¹

Several local treatment options might be used for ABCs, including surgery, embolization, sclerotherapy, and radiotherapy.^{1-3,6-9,17-19,22,29} Open surgery is considered the gold standard for the treatment of ABCs, with a local control

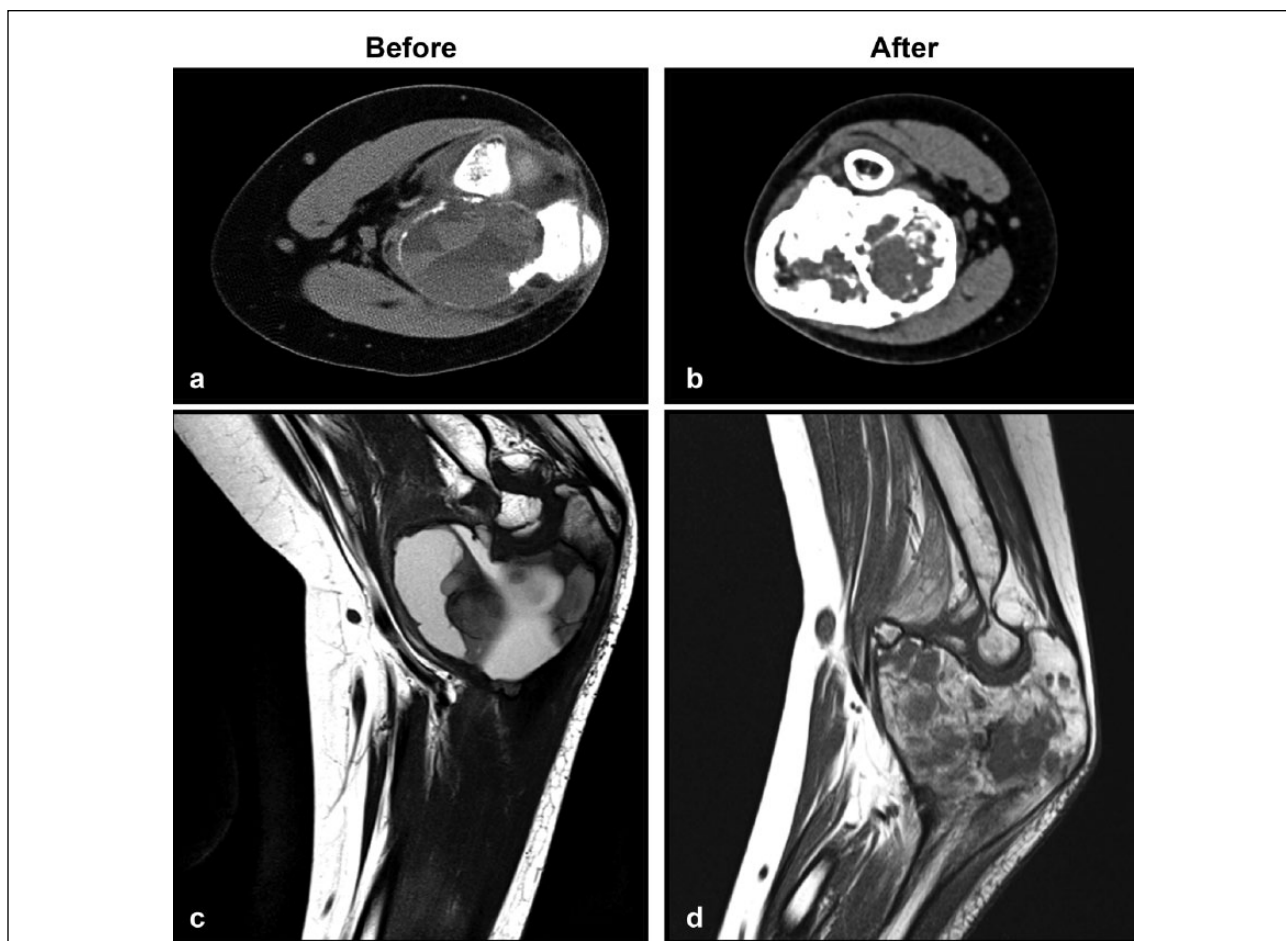

Figure 4. A 12-year-old boy presenting with ulnar aneurysmal bone cyst: fluid–blood levels and cortical disruption at baseline (a, c), responding after 6 administrations of denosumab (b, d).

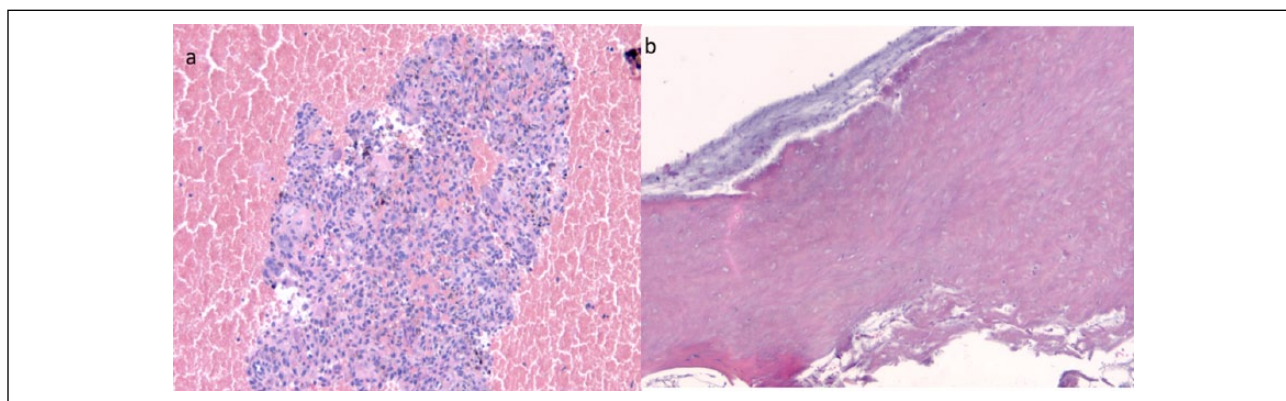


Figure 5. Biopsy of a distal tibia aneurysmal bone cyst in a 17-year-old girl pre-denosumab. (a) Abundant blood is present at periphery and giant cells in the context of high cellularity lesion rich in mononuclear cells in the central area. (b) Post-denosumab: disappearance of all mononucleated and multinucleated cells with trabecular and hyaline cells (denosumab-induced changes).

rate up to 100%.^{7,17,18} However, the complication rate is not negligible,^{2,4} particularly in case of spinal ABCs, which are associated with a high risk of morbidity such as neurologic impairment, instability, recurrence, or other vital problems.^{4,6-10} Moreover, the intense vascularization

of ABC lesions can result in significant intraoperative bleeding.^{4,10} Embolization is used sometimes as neoadjuvant treatment in order to minimize the blood loss during surgery,^{6,9,19} or as only treatment, especially if surgical options are challenging and predictably associated with

Table 1. Denosumab in the treatment of patients with aneurysmal bone cyst.

Authors	Year	No. of patients	Age, y/sex	Site	Symptoms	Clinical improvement	Bone formation	Complications
Pelle et al. ³¹	2013	1	5/M	Sacrum	Pain, bowel incontinence, urinary retention	Yes	Yes	No
Lange et al. ²⁴	2013	2	8/M	C5	Pain, radiculopathy, paresis	Yes (pain decrease)	Yes	Asymptomatic hypocalcemia
Pauli et al. ⁵	2014	1	11/M	C5	—	—	Yes	No
Our series	2017	9	21/F	Forearm	Swelling, pain	Yes	Yes	No
			14/F	Sacrum	—	—	Yes	No
			16/M	L5-S1	Pain	Yes	Yes	No
			42/M	Spine	Paresthesia	Yes	Yes	No
			16/F	Iliac wing	Pain	Yes	Yes	No
			12/M	Proximal ulna	Pain	Yes	Yes	No
			19/M	Proximal humerus	Pain	Yes	Yes	No
			17/F	Distal tibia	Pain	Yes	Yes	No
			25/M	Spine	Pain, radiculopathy	Yes	Yes	Vomiting, grade I
			19/M	Spine	Pain	Yes	Yes	No

risk of complications.^{2,9} However, there are limitations that make embolization infeasible, such as the absence of vessels that can be catheterized or the vicinity to arteries supporting vital structures such as the spinal cord.² In addition, embolization itself can be burdened by complications.^{2,10} Sclerotherapy, due to its capability to damage the endothelium, causing small vessel thrombosis and lesion healing, represents an alternative treatment.^{21,22} Radiotherapy, employed in the past alone or after surgery, is currently of limited use due to the risk of radio-induced sarcomas,^{10,23} vertebral body collapse, or metaphyseal fusion with growth arrest in young patients.²³ Altogether, in consideration of the high risk of complications related to the traditional treatment options for ABCs, innovative therapies are needed.²⁴

Denosumab is a human monoclonal antibody that binds the RANKL, which essentially initiates bone turnover.^{24,37} RANKL inhibition blocks osteoclast maturation and function.^{33,37,38} Denosumab has been successfully used in the treatment of osteoporosis,^{37,39,40} skeletal metastases,^{33,37,38,41} and, more recently, GCTB.³⁷ The positive results with denosumab in the treatment of GCTB^{35,37} as well as the clear immunohistochemical similarity and relationship between GCTB and ABCs^{31,35} justify the hypothesis that denosumab may also have positive effects on ABCs.⁴²

Although a limited number of patients have been treated to date, recent reports support this concept.^{5,24} Pelle et al.³¹ described a case of a 5-year-old boy with sacral ABC treated with denosumab, in order to avoid surgery with by a high risk of intraoperative and postoperative complications: an improvement of pain and of neurologic disease occurred after 2 and 6 weeks of treatment, respectively, with a significant reduction of tumor volume at MRI; no

complications were observed. Pauli et al.⁵ reported a case of a 21-year-old woman with local recurrence of a proximal forearm ABC, treated with denosumab: after 5 months, the tumor was better delimited by a bony rim, facilitating surgery. Lange et al.²⁴ reported 2 cases of children (8 and 11 years old) treated with denosumab for spinal ABCs where embolization failed, and reported healing of the lesion after 4 months of treatment with regression of the neurologic deficits, improvement of pain, and tumor regression. We noted clinical and radiologic improvement in our series as well, with decrease of pain and paresthesia, associated with bone formation at CT scan and a decrease of uptake of gadolinium contrast on MRI. As reported in the literature, tumor volume control was seen in all patients.³² Therefore, although denosumab does not always replace surgery, it simplifies the surgical procedure by reducing tumor size when used in the neoadjuvant setting.³²

Although the use of denosumab is associated with a dose-dependent risk to develop ONJ in 1.1%–2.0% of patients,^{34,43–46} in our series and in other reports on ABCs no complications were observed.^{5,24,31} Although children were not treated in our series and it is unclear if the side effect profile of denosumab differs in a preadolescent population, reports on denosumab's successful use in children have been published.^{24,31} Our data support the need of prospective clinical trials to confirm the role of denosumab in ABC treatment.

Conclusions

Denosumab has substantial activity in ABCs, with favorable toxicity profile. We strongly support the use of surgery and/or embolization for the treatment of ABC, but this

study clearly shows denosumab activity in the locally advanced/recurrent disease setting. Denosumab should enter the treatment armamentarium for ABC patients and could be proposed in selected patients after careful multidisciplinary discussion in a bone tumor referral center. A prospective study is warranted to confirm these findings.

Acknowledgements

The authors thank Dr. Alba Balladelli for editing the paper and Cristina Ghinelli for graphics work.

Conflict of interest

The authors declare they have no conflict of interest.

Funding

This work was supported by the Regione–Università Project, A. Liberati, Italian Ministry of Health–Project Alleanza contro il Cancro, and Associazione Matteo Amitrano ONLUS.

Ethical committee statement

All procedures performed in studies involving human participants were in accordance with the ethical standards of the institutional and/or national research committee and with the 1964 Helsinki declaration and its later amendments or comparable ethical standards. The study was approved by the appropriate institutional review committee.

Informed consent

Informed consent to be included in scientific studies was obtained from all individual participants included in the study at the time of admission.

References

- Rapp TB, Ward JP, Alaia MJ. Aneurysmal bone cyst. *J Am Acad Orthop Surg* 2012; 20: 233–241.
- Tsagozis P, Brosjö O. Current strategies for the treatment of aneurysmal bone cysts. *Orthop Rev* 2015; 7: 6182.
- Mankin HJ, Hornicek FJ, Ortiz-Cruz E, et al. Aneurysmal bone cyst: a review of 150 patients. *J Clin Oncol* 2005; 23: 6756–6762.
- Cottalorda J, Chotel F, Kohler R, et al. Aneurysmal bone cysts of the pelvis in children: a multicenter study and literature review. *J Pediatr Orthop* 2005; 25: 471–475.
- Pauli C, Fuchs B, Pfirrmann C, et al. Response of an aggressive periosteal aneurysmal bone cyst (ABC) of the radius to denosumab therapy. *World J Surg Oncol* 2014; 12: 17.
- Zenonos G, Jamil O, Governale LS, et al. Surgical treatment for primary spinal aneurysmal bone cysts: experience from Children's Hospital Boston. *J Neurosurg Pediatr* 2012; 9: 305–315.
- Ozaki T, Halm H, Hillmann A, et al. Aneurysmal bone cysts of the spine. *Arch Orthop Trauma Surg* 1999; 119: 159–162.
- Marushima A, Matsumaru Y, Suzuki K, et al. Selective arterial embolization with n-butyl cyanoacrylate in the treatment of aneurysmal bone cyst of the thoracic vertebra: a case report. *Spine* 2009; 34: E230–E234.
- Boriani S, Lo SL, Puvanesarajah V, et al. Aneurysmal bone cysts of the spine: treatment options and considerations. *Neurooncology* 2014; 120: 171–178.
- Rossi G, Mavrogenis AF, Papagelopoulos PJ, et al. Successful treatment of aggressive aneurysmal bone cyst of the pelvis with serial embolization. *Orthopedics* 2012; 35: e963–e968.
- Lau AW, Pringle LM, Quick L, et al. TRE17/ubiquitin-specific protease 6 (USP6) oncogene translocated in aneurysmal bone cyst blocks osteoblastic maturation via an autocrine mechanism involving bone morphogenetic protein dysregulation. *J Biol Chem* 2010; 285: 37111–37120.
- Oliveira AM, Chou MM, Perez-Atayde AR, Rosenberg AE. Aneurysmal bone cyst: a neoplasm driven by upregulation of the USP6 oncogene. *J Clin Oncol* 2006; 24: e1; author reply e2.
- Ye Y, Pringle LM, Lau AW, et al. TRE17/USP6 oncogene translocated in aneurysmal bone cyst induces matrix metalloproteinase production via activation of NF-kappaB. *Oncogene* 2010; 29: 3619–3629.
- Panoutsakopoulos G, Pandis N, Kyriazoglou I, et al. Recurrent t(16;17)(q22;p13) in aneurysmal bone cysts. *Genes Chromosomes Cancer* 1999; 26: 265–266.
- Oliveira AM, Perez-Atayde AR, Inwards CY, et al. USP6 and CDH11 oncogenes identify the neoplastic cell in primary aneurysmal bone cysts and are absent in so-called secondary aneurysmal bone cysts. *Am J Pathol* 2004; 165: 1773–1780.
- Angelini A, Mavrogenis AF, Trovarelli G, Ferrari S, Picci P, Ruggieri P. Telangiectatic osteosarcoma: a review of 87 cases. *J Cancer Res Clin Oncol* 2016; 142: 2197–2207.
- Farsetti P, Tudisco C, Rosa M, et al. Aneurysmal bone cyst: long-term followup of 20 cases. *Arch Orthop Trauma Surg* 1990; 109: 221–223.
- Grzegorzewski A, Pogonowicz E, Sibinski M, et al. Treatment of benign lesions of humerus with resection and non-vascularised, autologous fibular graft. *Int Orthop* 2010; 34: 1267–1272.
- Pearl MS, Wolinsky JP, Gailloud P. Preoperative embolization of primary spinal aneurysmal bone cysts by direct percutaneous intralesional injection of n-butyl-2-cyanoacrylate. *J Vasc Interv Radiol* 2012; 23: 841–845.
- Shisha T, Marton-Szucs G, Dunay M, et al. The dangers of intraosseous fibro-sing agent injection in the treatment of bone cysts: the origin of major complications shown in a rabbit model. *Int Orthop* 2007; 31: 359–362.
- Rastogi S, Varshney MK, Trikha V, et al. Treatment of aneurysmal bone cysts with percutaneous sclerotherapy using polidocanol: a review of 72 cases with long-term follow-up. *J Bone Joint Surg Br* 2006; 88: 1212–1216.
- Varshney MK, Rastogi S, Khan SA, Trikha V. Is sclerotherapy better than intralesional excision for treating aneurysmal bone cysts? *Clin Orthop* 2010; 468: 1649–1659.
- Feigenberg SJ, Marcus RB Jr, Zlotecki RA, et al. Megavoltage radiotherapy for aneurysmal bone cysts. *Int J Radiat Oncol Biol Phys* 2001; 49: 1243–1247.

24. Lange T, Stehling C, Fröhlich B, et al. Denosumab: a potential new and innovative treatment option for aneurysmal bone cysts. *Eur Spine J* 2013; 22: 1417–1422.
25. Huang L, Xu J, Wood DJ, Zheng MH. Gene expression of osteoprotegerin ligand, osteoprotegerin, and receptor activator of NFkappaB in giant cell tumor of bone: possible involvement in tumor cell-induced osteoclast-like cell formation. *Am J Pathol* 2000; 156: 761–767.
26. Morgan T, Atkins GJ, Trivett MK, et al. Molecular profiling of giant cell tumor of bone and the osteoclastic localization of ligand for receptor activator of nuclear factor kappaB. *Am J Pathol* 2005; 167: 117–128.
27. Skubitz KM, Cheng EY, Clohisy DR, et al. Gene expression in giant-cell tumors. *J Lab Clin Med* 2004; 144: 193–200.
28. Bord S, Frith E, Ireland DC, et al. Synthesis of osteoprotegerin and RANKL by megakaryocytes is modulated by oestrogen. *Br J Haematol* 2004; 126: 244–251.
29. Branstetter DG, Nelson SD, Manivel JC, et al. Denosumab induces tumor reduction and bone formation in patients with giant-cell tumor of bone. *Clin Cancer Res* 2012; 18: 4415–4424.
30. Eghbali-Fatourehchi G, Khosla S, Sanyal A, et al. Role of RANK ligand in mediating increased bone resorption in early postmenopausal women. *J Clin Invest* 2003; 111: 1221–1230.
31. Pelle DW, Ringler JW, Peacock JD, et al. Targeting receptor-activator of nuclear kappaB ligand in aneurysmal bone cysts: verification of target and therapeutic response. *Transl Res* 2014; 164: 139–148.
32. Dubory A, Missenard G, Domont J, Court C. Interest of denosumab for the treatment of giant-cells tumors and aneurysmal bone cysts of the spine: about nine cases. *Spine* 2016; 41: E654–E660.
33. Purdue E. Aneurysmal bone cysts: denosumab extends its reach. *Transl Res* 2014; 164: 135–138.
34. Henry DH, Costa L, Goldwasser F, et al. Randomized, doubleblind study of denosumab versus zoledronic acid in the treatment of bone metastases in patients with advanced cancer (excluding breast and prostate cancer) or multiple myeloma. *J Clin Oncol* 2011; 29: 1125–1132.
35. Won KY, Kalil RK, Kim YW, Park YK. RANK signalling in bone lesions with osteoclast-like giant cells. *Pathology* 2011; 43: 318–321.
36. Hofbauer LC, Schoppet M. Clinical implications of the osteoprotegerin/RANKL/RANK system for bone and vascular diseases. *JAMA* 2004; 292: 490–495.
37. Thomas D, Henshaw R, Skubitz K, et al. Denosumab in patients with giant-cell tumour of bone: an open-label, phase 2 study. *Lancet Oncol* 2010; 11: 275–280.
38. Kostenuik PJ, Nguyen HQ, McCabe J, et al. Denosumab, a fully human monoclonal antibody to RANKL, inhibits bone resorption and increases BMD in knock-in mice that express chimeric (murine/human) RANKL. *J Bone Miner Res* 2009; 24: 182–195.
39. Silva-Fernández L, Rosario MP, Martínez-López JA, et al. Denosumab for the treatment of osteoporosis: A systematic literature review. *Rheumatol Clin* 2013; 9: 42–52.
40. Burkiewicz JS, Scarpace SL, Bruce SP. Denosumab in osteoporosis and oncology. *Ann Pharmacother* 2009; 43: 1445–1455.
41. Lipton A, Fizazi K, Stopeck AT, et al. Superiority of denosumab to zoledronic acid for prevention of skeletal-related events: a combined analysis of 3 pivotal, randomised, phase 3 trials. *Eur J Cancer* 2012; 48: 3082–3092.
42. Taylor RM, Kashima TG, Hemingway FK, et al. CD14–mononuclear stromal cells support (CD141) monocyte-osteoclast differentiation in aneurysmal bone cyst. *Lab Invest* 2012; 92: 600–605.
43. Stopeck AT, Lipton A, Body JJ, et al. Denosumab compared with zoledronic acid for the treatment of bone metastases in patients with advanced breast cancer: a randomized, double-blind study. *J Clin Oncol* 2010; 28: 5132–5139.
44. Miller PD. A review of the efficacy and safety of denosumab in postmenopausal women with osteoporosis. *Ther Adv Musculoskelet Dis* 2011; 3: 271–282.
45. Kyrgidis A, Toulis KA. Denosumab-related osteonecrosis of the jaws. *Osteoporos Int* 2011; 22: 369–370.
46. Palmerini E, Chawla NS, Ferrari S, et al. Denosumab in advanced/unresectable giant-cell tumour of bone (GCTB): for how long? *Eur J Cancer* 2017; 76: 118–112.