

STANDARD ARTICLE

Comparison of smartphone-based and standard base-apex electrocardiography in healthy dairy cows

Francesca Bonelli¹  | Tommaso Vezzosi¹  | Mireille Meylan²  | Irene Nocera¹ |
Vincenzo Ferrulli¹ | Carlotta Buralli¹ | Valentina Meucci¹ | Rosalba Tognetti¹

¹Department of Veterinary Sciences,
University of Pisa, Pisa, Italy

²The Clinic for Ruminants, Vetsuisse-Faculty,
University of Bern, Bern, Switzerland

Correspondence

Francesca Bonelli, Department of Veterinary
Sciences, University of Pisa, via Livornese lato
monte, 56122 San Piero a Grado, Pisa, Italy.
Email: francesca.bonelli@unipi.it

Background: There is good diagnostic accuracy of smartphone-based ECG in the evaluation of heart rate (HR), heart rhythm, and ECG values for humans, horses, dogs, and cats.

Objectives: Assess feasibility and reliability of a smartphone ECG device to evaluate HR expressed as beats per minute and ECG values in cows.

Animals: Fifty-five healthy Holstein Friesian cows.

Methods: Prospective observational study. A standard base-apex ECG was acquired for 60 seconds in each cow. A smartphone ECG tracing was recorded simultaneously using a single-lead bipolar ECG recorder. All ECGs were reviewed by 1 blinded investigator. The following ECG variables were assessed: HR, P wave duration, PR interval, QRS complex and QT interval (milliseconds), P wave, and QRS complex polarity. Agreement between standard and smartphone ECG was evaluated by Cohen's *k* test and the Bland-Altman test.

Results: Smartphone ECG tracings were interpretable in 89% of the recordings. Minimal differences of no clinical relevance were found between standard and smartphone ECG tracings regarding HR and duration of ECG waves and interval. Good agreement found in the evaluation of QRS complex polarity (85%) but not for P wave polarity ($k = 0.006$). Artifacts were rare but of significantly higher frequency in smartphone ECG compared to standard ECG tracings (22% versus 0%; $P = .005$).

Conclusions and Clinical Importance: Good quality single-lead ECG tracings can be recorded by smartphone device in healthy cows. Smartphone tracings are reliable for evaluation of HR and selective ECG variables. Smartphone ECG can represent an additional tool for ECG screening in cows.

KEYWORDS

cow, ECG, iPhone, mobile, validation

1 | INTRODUCTION

There are various publications on ECG in different breeds of dairy cattle in the veterinary literature.¹⁻⁹ In the cattle, standard ECG represents an inexpensive, noninvasive technique for the characterization of cardiac arrhythmias, and it gives useful prognostic information.^{9,10} In cows, standard ECG is usually performed using the base-apex lead

placement.^{7,10} It requires the use of an electrocardiographic machine, cables, and electrodes. Therefore, standard ECG might not always be practicable, especially in the field and under farm conditions.

Recently, single-lead ECGs recorded with smartphone devices using specific adaptors and software have been developed in human medicine.^{11,12} The accuracy of smartphone ECG tracings in measuring heart rate (HR), evaluating heart rhythm, and detecting ECG changes associated with myocardial ischemia is acceptable.¹³⁻¹⁹ Similarly, in dogs, cats, and horses, smartphone ECG provided adequate tracings for the assessment of HR and cardiac rhythm.²⁰⁻²²

Abbreviations: App HR, heart rate automatically calculated by the smartphone application; bpm, beats per minute; HR, heart rate.

This is an open access article under the terms of the Creative Commons Attribution-NonCommercial License, which permits use, distribution and reproduction in any medium, provided the original work is properly cited and is not used for commercial purposes.

© 2018 The Authors. *Journal of Veterinary Internal Medicine* published by Wiley Periodicals, Inc. on behalf of the American College of Veterinary Internal Medicine.

The aim of our study was to assess the reliability of a smartphone ECG device to evaluate HR and ECG values in healthy dairy cows.

2 | MATERIALS AND METHODS

2.1 | Animals

A total of 55 Holstein Friesian cows were recruited from the C.I.R.A. A. "E. Avanzi," the Dairy Farm of the University of Pisa. In order to be included in the study, cows had to be healthy based on history and physical examination.

Our prospective observational study was approved by the Institutional Animal Care and Use Committee of the University of Pisa (45965/2016). An owner's written consent was obtained for ECG recording for the cows included in the study.

2.2 | ECG acquisition and analysis

The ECGs were recorded at the farm between 9.00 and 12.00 in the morning. Cows were trained to stand in self-locking stanchions where they were then restrained for a maximum of 15 minutes each for ECG measurements. Both standard base-apex ECG and smartphone ECG were simultaneously acquired for 60 seconds in the standing, unsedated, and unclipped cows. A small amount of alcohol was used to optimize contact and obtain a good quality ECG signal for both methods. The ECG tracings were recorded only when animals were standing quietly. The standard base-apex ECG (MAC 1600 ECG system; GE Healthcare, Milano, Italy) was acquired as previously described.⁷ The positive electrode was positioned at the level of the 5th left intercostal space, caudal to the olecranon, and the negative electrode on the jugular furrow in the lower 1/3 of the left side of the neck. The 3rd electrode was attached away from these 2 electrodes, at the level of the point of the left shoulder. A smartphone ECG tracing was recorded simultaneously, starting and ending at the same time as the standard ECG, using a single-lead bipolar ECG (AliveCor Veterinary Heart Monitor; AliveCor, San Francisco, California) and its software interface (AliveECG Vet; AliveCor). The smartphone ECG tracings were recorded with an iPhone 5C (Apple, Cupertino, California). The smartphone device was placed on the left chest wall slightly below the olecranon and cranial to the positive electrode. A dorsoventral orientation with a 30° cranial inclination of the smartphone case was used. The smartphone case was maintained in touch with the skin throughout ECG registration. Thus, the smartphone screen was pointed toward the operator for a real-time visualization of the ECG trace. Finally, the smartphone needed to be held with the camera located ventrally, while the "home button" was located dorsally (Figure 1). If real-time visualization of the ECG recording on the smartphone screen was impaired by the olecranon, a second operator helped pulling the left front leg slightly further cranially.

For each cow, ECG tracings obtained with the standard base-apex method were recorded and printed at 25 mm/s with a gain of 10 mm/mV. Those obtained with the smartphone ECG method were recorded at 25 mm/s with a gain of 20 mm/mV and automatically

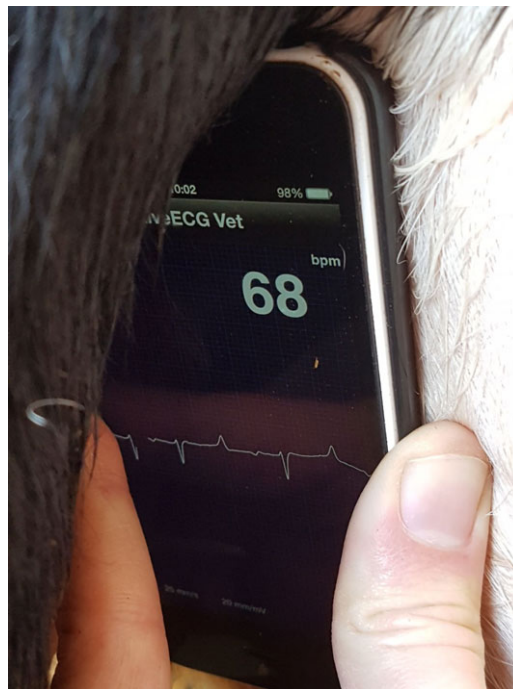


FIGURE 1 Dorsoventral orientation with a 30° cranial inclination of the smartphone, with the case maintained in touch with the skin and the smartphone screen pointed toward the investigator for a real-time visualization of the ECG trace. The smartphone was held with the camera located ventrally while the "start button" was located dorsally.

digitized by the dedicated software interface. A portable document format file was built for each ECG trace and sent via email for storage. All smartphone ECGs were recorded by the same investigator (V. Ferrulli). All 60 seconds of each ECG tracing were analyzed. In a blinded fashion, all ECG tracings were reviewed by 1 expert investigator (T. Vezzosi), who judged if the tracings were acceptable for interpretation and, if so, performed ECG measurements. Tracings were considered acceptable for interpretation if baseline artifacts were absent for at least 80% of each tracing. Baseline artifacts were defined as ECG segments in which P waves, QRS, or both complexes could not be identified. The following variables were measured: HR (beats per minute, bpm), duration of P wave (milliseconds), duration of PR interval (milliseconds), duration of QRS complex (milliseconds), duration of QT interval (milliseconds), P wave polarity (positive/negative), and QRS complex polarity (positive/negative).⁷ The mean HR was calculated as the mean value of 3 independent HR calculations. Three areas of 6 seconds in duration were randomly selected on the ECG tracings. The number of QRS complexes was counted over these 6 seconds and multiplied by 10 to calculate the HR per minute (bpm). The mean HR automatically calculated by the smartphone application (App HR) was also recorded. Bradycardia was defined as an HR < 65 bpm and tachycardia with an HR > 90 bpm.²³ Each wave or interval duration was calculated using 3 randomly selected heartbeats, and the mean of these 3 measurements was used for statistical analyses.

2.3 | Statistical analyses

The analyses were performed only with paired ECG tracings that were acceptable for interpretation, and the standard ECG was set as the

reference method. Descriptive data regarding the measurements obtained with the standard ECG and smartphone ECG methods were reported as median and range (minimum and maximum). The Kolmogorov-Smirnov test was applied to verify data distribution. Cohen's κ test was used to calculate the agreement between smartphone ECG and standard ECG for HR classification (normal, bradycardia, or tachycardia), polarity of the P wave, and polarity of the QRS complex. The κ coefficient was interpreted as follows: values ≤ 0.20 as no agreement, 0.21-0.40 as fair, 0.41-0.60 as moderate, 0.61-0.80 as good, 0.81-0.99 as very good, and 1.00 as perfect agreement. If the contingency table reported one or more values equal to 0, Cohen's kappa could not be calculated; therefore, in these cases, the percentage of agreement was used. The Bland-Altman test was applied to verify the bias and the 95% limits of agreement between standard versus smartphone ECGs for HR and App HR, and duration of the P wave, PR interval, QT interval, and QRS complex. The presence (yes/no) and duration (milliseconds) of baseline artifacts were assessed. Differences in the prevalence of baseline artifacts on smartphone and standard ECG tracings were evaluated using the Fisher' exact test.

Statistical analyses were performed with a commercial software (GraphPad Prism 6, La Jolla, CA). A *P* value < 0.05 was considered significant.

3 | RESULTS

3.1 | Animals and feasibility

All 55 recruited Holstein Frisian cows were enrolled in the study. The median age was 4 years (range: 2-7 years), the median lactation number was 3 (range: 1-5), the median number of days in milk was 78 (range: 20-110), the median body weight was 720 kg (range: 525-800 kg), and the median body condition score was 3.25 (range: 2.5-4) of 5.

Electrocardiographic recording was feasible with both standard and smartphone ECG in all cows, and all animals tolerated the procedure well. On standard ECG tracings, all cows enrolled in the study showed sinus rhythm and no baseline artifacts were identified. Forty-nine of the 55 (89%) recorded smartphone ECG tracings were judged

acceptable for interpretation (Figure 2). Six of the 55 (11%) smartphone ECG tracings were considered inadequate for interpretation because of the presence of baseline artifacts in most of the tracings and were excluded from further analyses.

3.2 | Heart rate

According to the standard ECG, 40 of 49 (82%) cows had a normal HR, 4 of 49 (8%) had bradycardia, and 5 of 49 (10%) had tachycardia. Median, minimum, and maximum values of HR evaluation obtained with the standard ECG method, HR evaluation manually measured on digitized tracings, and App HR evaluation are reported in Table 1. A perfect agreement ($\kappa = 1$) between smartphone and standard ECG was found in the classification of HR when it was measured manually on digitized tracings. The bias between the HR value measured manually on standard ECG and smartphone ECG was 3 bpm (95% limits of agreement: $-10, +17$ bpm) (Figure 3A).

In contrast, the bias between the App HR and the HR measured manually on standard ECG tracings was -7 bpm (95% limits of agreement: $-75, +61$ bpm) (Figure 3B). The App HR was less accurate than the manually measured HR on smartphone ECG but still showed a moderate concordance with standard ECG ($k = 0.60$).

3.3 | P wave, PR interval, and QT interval

Median, minimum, and maximum values for the duration of P wave, PR interval, and QT interval obtained with the standard ECG and the smartphone ECG methods are reported in Table 1. The evaluation of P wave duration measured on standard ECG and smartphone ECG showed a bias of 10 milliseconds (95% limits of agreement: $-17, +38$ milliseconds; Figure 3C), PR duration had a bias of 7 milliseconds (95% limits of agreement: $-20, +34$ milliseconds; Figure 3D), and QT duration showed a bias of -4 milliseconds (95% limits of agreement: $-36, +27$ milliseconds; Figure 3E). On the standard ECG tracings, P polarity was positive in 48 of 49 (98%) cases and negative in 1 of 49 (2%) cases. On smartphone ECG tracings, P polarity was positive in 5 of 49 (10%) cases, negative in 39 of 49 (80%) cases, and it could not be determined in 5 of 49 (10%) cases. A poor agreement ($k = 0.006$) was found between standard and smartphone ECG for P polarity.

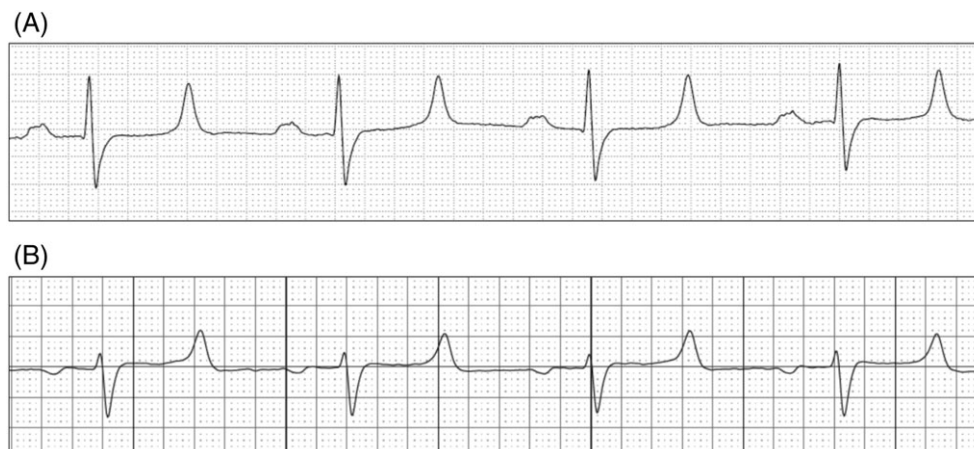

FIGURE 2 Standard ECG (A) and smartphone ECG (B) tracings in a cow. Paper speed = 50 mm/s (A and B); gain = 10 mm/mV (A) and 20 mm/mV (B).

TABLE 1 Median and range (minimum and maximum) of the values obtained with the standard ECG and smartphone ECG methods

Parameter	Standard ECG Median (range)	Smartphone ECG Median (range)
HR (bpm)	80 (60-110)	80 (60-110)
HR _{App} (bpm)	...	78 (62-265)
P wave (ms)	70 (60-120)	75 (50-90)
PR interval (ms)	220 (160-260)	205 (150-250)
QRS complex (ms)	70 (50-130)	60 (40-120)
QT interval (ms)	380 (280-440)	390 (270-460)

Abbreviations: bpm, beats per minute; HR, heart rate, HR_{App}, heart rate automatically calculated by the smartphone ECG application.

3.4 | QRS complex analysis

Median, minimum, and maximum values of QRS complex analysis obtained with the standard ECG and the smartphone ECG methods are reported in Table 1. On standard ECG, the QRS complexes showed a negative polarity in all 49 cases for which an adequate smartphone tracing was available. On smartphone ECG tracings, the QRS polarity was negative in 45 of 49 (92%) cases and positive in 4 of 49 (8%) cases. Hence, the percentage of agreement between the 2 methods in QRS polarity evaluation was 85%. The evaluation of QRS duration showed a bias of 4 milliseconds (95% limits of agreement: -18, +26 milliseconds) (Figure 3F).

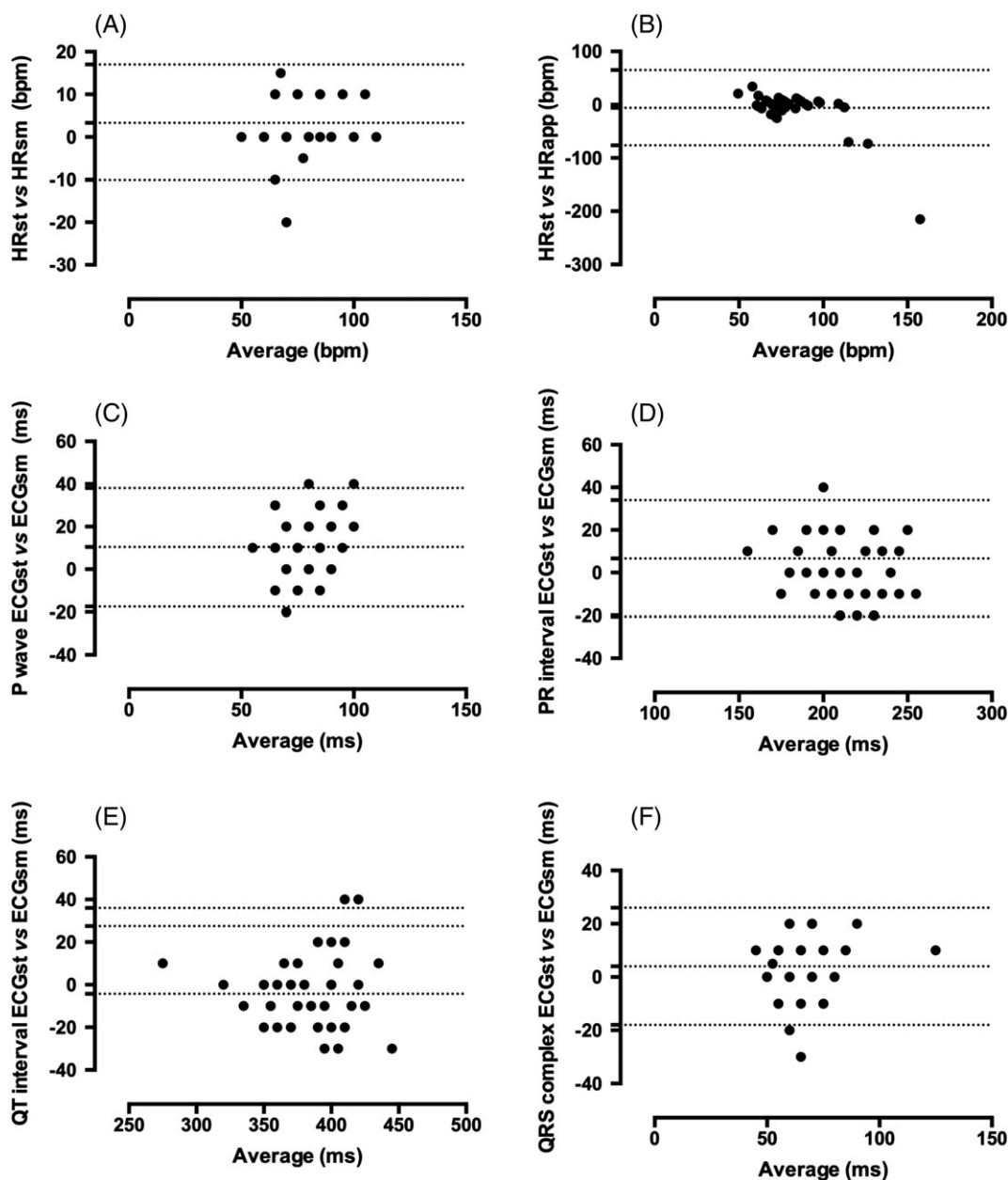


FIGURE 3 Limits of agreement (Bland-Altman) plots showing differences between heart rate (HR) values manually measured on standard ECG (HRst) and (A) smartphone ECG tracings (HRsm) and (B) values produced by the smartphone application (HRapp); (C) differences between duration of P wave measured on standard ECG (ECGst) and smartphone ECG tracings (ECGsm); (D) differences between PR interval measured on ECGst and ECGsm; (E) differences between QRS complex measured on ECGst and ECGsm; and (F) differences between QT interval measured on ECGst and ECGsm

3.5 | Artifacts

Among the 49 smartphone ECG tracings judged interpretable, 11 (22%) presented baseline artifacts. The median duration of baseline artifacts on smartphone ECG tracings was 5.7 seconds (range: 1.9-10.9 seconds), corresponding to a median 9% of the total duration of each smartphone ECG tracing. No baseline artifacts were detected on standard ECG tracings. The prevalence of artifacts was significantly higher in smartphone ECG tracings in comparison to standard ECG tracings ($P = .005$).

4 | DISCUSSION

The main findings of the present study are that (1) smartphone-based ECG was feasible in cows, (2) most smartphone ECG tracings were adequate for interpretation, and (3) reliable measurements of HR, waves, and intervals could be obtained from smartphone ECG tracings.

The recording of smartphone ECG was easy to perform in all cases and well tolerated by the animals. The smartphone ECG was considered to be feasible under field conditions and thus its application might have relevance for clinical practice.

In our study, the smartphone ECG tracings were interpretable in 89% of cases, which is in line with findings in other species. In particular, smartphone ECG tracings are interpretable in 87%-99.6% of human patients,^{17,24} in 97.6% of dogs,²¹ and in 96% of horses.²² In 22% of our smartphone ECG tracings, short segments with motion or muscle tremor artifacts on the isoelectric line were present; however, they did not prevent measuring HR and ECG waves' duration. Only 6 of all 55 smartphone ECG tracings were judged noninterpretable because of the presence of too many ($\geq 20\%$ of the tracing) motion or muscle tremor artifacts.

Regarding HR, few cows showed mild bradycardia ($n = 7$) or tachycardia ($n = 5$). The HR of cows with bradycardia was never below 60 bpm. None of these animals showed signs of cardiac disease. Sinus bradycardia has been observed in cattle under conditions of increased vagal tone, such as in cows deprived of food,^{25,26} with anorexia, and in cows with central nervous disorders.²⁷ All cows that presented bradycardia in our study had normal appetites and showed no signs of pathological conditions. Cows that showed an increased HR were all healthy based on clinical examination and did not present any signs of cardiac or general disease. The increased HR found in few animals in our study might have been caused by stress at the time of ECG recording. Thus, both bradycardia and tachycardia in otherwise normal cattle should not be taken as a sign of heart disease unless it is persistent or associated with signs of cardiac failure.²⁸ The smartphone ECG showed perfect agreement with the standard method when HR was measured manually on digitized tracings in cows, in accordance with findings in dogs and in horses where there is an excellent agreement between the 2 methods.²⁰⁻²² The accuracy of App HR was good in comparison to HR measured manually on digitized tracings. The App HR seemed to provide slightly less accurate results in cows than in dogs²¹ but was in line with findings in horses.²² In our experience, the App HR was totally unreliable in few cows ($n = 6/55$), because the App HR interpreted tall T waves as QRS complexes, leading to erroneous HR determination.

The smartphone ECG was reliable regarding the evaluation of ECG waves and intervals' duration, leading to minimal differences of no clinical relevance in comparison to the standard ECG. The only disagreement was found in the evaluation of P wave polarity. It was mainly positive on standard ECG and mainly negative on smartphone ECG. In 10% of the cases, the P wave was not clearly visible on smartphone tracings. Similarly, a previous study in horses showed that there was no good agreement in P wave polarity between standard and smartphone ECG tracings.²² A possible explanation for the observed discrepancy is that the single lead of the smartphone device is essentially a precordial lead, evaluating a different anatomic plane than the 1 of the standard ECG. Thus, the atrial depolarization vector might generate P waves of different amplitude and polarity according the ECG-lead system used. The clinical relevance of our findings should be further evaluated in a study including cows with supraventricular arrhythmias, especially atrial fibrillation, which is common in cattle with digestive disorders.^{4,25,26}

A good agreement was found for the analysis of the QRS complex polarity, and in most cows, the QRS complexes showed the same polarity on smartphone ECG and standard ECG tracings. The smartphone ECG has good agreement in the analysis of the QRS complex in assessing both duration and polarity as previously found in dogs²¹ and horses.²² The QRS complex polarity can be useful in the evaluation of ectopic beats.²⁹ Thus, further studies should be performed to verify the reliability of smartphone ECG in detecting ectopic beats in cows.

No arrhythmias were detected in our study population, thus no statistical analysis could be performed to assess the diagnostic accuracy of the smartphone ECG for detecting cardiac arrhythmias. Our result is not unexpected as only healthy cows were included in the study. Detection of cardiac arrhythmias will have to be assessed in further studies in cows with cardiac abnormalities. Another limitation of our study might be that the smartphone tracings were acquired by 1 investigator only and that the evaluation of suitability for interpretation was also done by only 1 (different) investigator. Thus, interoperator variability was not evaluated in our study and will need to be explored in further studies.

In conclusion, good quality single-lead ECG tracings could be recorded by the use of a commercial smartphone device in healthy cows. The smartphone tracings were reliable for evaluation of HR, duration of ECG waves and intervals, and QRS polarity. Smartphone ECG technology could represent a reliable diagnostic tool for electrocardiographic screening of cows, especially under field conditions. However, the smartphone ECG device cannot be a substitute for standard base-apex ECG. Further studies are needed to assess the diagnostic value of smartphone ECG in the diagnosis of cardiac arrhythmias in cows.

ACKNOWLEDGMENTS

Part of the study was presented as an oral communication at the 2017 European Buiatric Forum (EBF), October 4-6, 2017, Bilbao, Spain.

CONFLICT OF INTEREST DECLARATION

Authors declare no conflicts of interest.

OFF-LABEL ANTIMICROBIAL DECLARATION

Authors declare no off-label use of antimicrobials.

INSTITUTIONAL ANIMAL CARE AND USE COMMITTEE (IACUC) OR OTHER APPROVAL DECLARATION

The in vivo trial was approved by the IACUC of the University of Pisa (45965/2016).

HUMAN ETHICS APPROVAL DECLARATION

Authors declare human ethics approval was not needed for this study.

ORCID

Francesca Bonelli  <https://orcid.org/0000-0002-4119-7781>

Tommaso Vezzosi  <https://orcid.org/0000-0001-8301-6582>

Mireille Meylan  <https://orcid.org/0000-0003-0191-5686>

REFERENCES

- Alfredson BN, Sykes JF. Electrocardiographic studies in normal dairy cattle. *J Agri Res.* 1942;65:61-87.
- Broojmans AWM. *Electrocardiography in Horses and Cattle.* Utrecht, The Netherlands: Laboratory of Veterinary Physiology, State University; 1957.
- Upadhyay RC, Sud SC, Joshi HC, Bahga HS. Electrocardiographic studies in Jersey cattle. *Indian Vet J.* 1976;53:953-961.
- McGuirk SM, Muir WW, Sams RA, Rings DM. Atrial fibrillation in cows. Clinical findings and therapeutic considerations. *J Am Vet Med Assoc.* 1983;82:1380-1386.
- Machida NY, Okamata Y, Minami S, et al. Cardiac arrhythmias in normal Holstein heifers. *J Jap Vet Med Assoc.* 1991;44:1176-1179.
- Rezakhani A, Paphan AA. Study on prevalence of cardiac arrhythmias in dairy calves. *Iranian J Vet Res.* 2002;3:157-162.
- Rezakhani A, Paphan AA, Shekarfroush S. Analysis of base apex lead electrocardiograms of normal dairy cows. *Vet Arhiv.* 2004;74:351-358.
- Cedeno DA, Lourenco MLG, Daza CAB, et al. Electrocardiogram assessment using Eithoven and base-apex lead systems in healthy Holstein cows and neonates. *Pesq Vet Bras.* 2016;36(Supl.1):1-7.
- Reddy BS, Sivajothi S. Electrocardiographic parameters of normal dairy cows during different ages. *J Veter Sci Med.* 2016;4(1):5.
- Buczinski S, Boerboom RA. Heart disease in cattle: diagnostic, therapeutic approaches and prognosis. *Vet J.* 2010;184:258-263.
- Bruining N, Caiani E, Chronaki C, Guzik P, van der Velde E, Task Force of the e-Cardiology Working. Acquisition and analysis of cardiovascular signals on smartphones: potential, pitfalls and perspectives: by the task force of the e-cardiology working Group of European Society of cardiology. *Eur J Prev Cardiol.* 2014;21:4-13.
- Baquero GA, Banchs JE, Ahmed S, Naccarelli GV, Luck JC. Surface 12 lead electrocardiogram recordings using smart phone technology. *J Electrocardiol.* 2015;48:1-7.
- Lau JK, Lowres N, Neubeck L. iPhone ECG application for community screening to detect silent atrial fibrillation: a novel technology to prevent stroke. *Int J Cardiol.* 2013;165:193-194.
- Lee J, Reyes BA, McManus DD, et al. Atrial fibrillation detection using an iPhone 4S. *IEEE Trans Biom Eng.* 2013;60:203-206.
- Wong CK. iPhone ECG monitoring: the gateway to the new paradigm of STEMI therapy. *Int J Cardiol.* 2013;168:2897-2878.
- Ferdman DJ, Liberman L, Silver ES. A smartphone application to diagnose the mechanism of pediatric supraventricular tachycardia. *Pediatr Cardiol.* 2015;36:1452-1457.
- Lowres N, Krass I, Neubeck L, et al. Atrial fibrillation screening in pharmacies using an iPhone ECG: a qualitative review of implementation. *Int J Clin Pharmacol.* 2015;37:1111-1120.
- McManus DD, Lee J, Maitas O, et al. A novel application for the detection of an irregular pulse using an iPhone 4S in patients with atrial fibrillation. *Heart Rhythm J.* 2015;10:315-319.
- Muhlestein JB, Le V, Albert D, et al. Smartphone ECG for evaluation of STEMI: results of the ST LEUIS pilot study. *J Electrocardiol.* 2015;48:249-259.
- Kraus MS, Gelzer AR, Rishniw M. Detection of heart rate and rhythm with a smartphone-based electrocardiograph versus a reference standard electrocardiograph in dogs and cats. *J Am Vet Med Assoc.* 2016;249:189-194.
- Vezzosi T, Buralli C, Marchesotti F, et al. Diagnostic accuracy of a smartphone electrocardiograph in dogs: comparison with standard 6-lead electrocardiography. *Vet J.* 2016;216:33-37.
- Vezzosi T, Sgorbini M, Bonelli F, et al. Evaluation of a smartphone electrocardiograph in healthy horses: comparison with standard base-apex electrocardiography. *J Equine Vet Sci.* 2018;67:61-65.
- Stöber M. Segnalamento, anamnesi, procedimento semeiologico di base (basi della tecnica d'esame), esame obiettivo generale. In: Rosenberger G, ed. *L'esame Clinico del Bovino.* Piacenza, Italy: Edagricole; 1993:55-127.
- Ho CL, Fu YC, Lin MC, Chan SC, Hwang B, Jan SL. Smartphone applications (apps) for heart rate measurement in children: comparison with electrocardiography monitor. *Pediatr Cardiol.* 2014;35:726-731.
- Gentile A, Guglielmini C, Cipone M. Alterazioni del ritmo cardiaco nel bovino in rapporto col digiuno. *Arch Vet Italiano.* 1993;44:100-107.
- McGuirk MM, Bednarski RM, Clayton MK. Bradycardia in cattle deprived of food. *J Am Vet Med Assoc.* 1990;196:894-896.
- Austin AR, Pawson L, Meek S, Webster S. Abnormalities of heart rate and rhythm in bovine spongiform encephalopathy. *Vet Rec.* 1997;141:352-357.
- Rezakhani A, Paphan AA, Gheisari HR. Cardiac dysrhythmias in clinically healthy heifers and cows. *Revue Med Vet.* 2004;155:159-162.
- Reef VB. Arrhythmias. In: Marr C, ed. *Cardiology of the Horse.* London, UK: W B Saunders; 1999:179-209.

How to cite this article: Bonelli F, Vezzosi T, Meylan M, et al. Comparison of smartphone-based and standard base-apex electrocardiography in healthy dairy cows. *J Vet Intern Med.* 2018;1-6. <https://doi.org/10.1111/jvim.15396>