

Original Research Paper

Effect of Dietary Supplementation of a Mix of Chestnut and Quebracho Tannins on Intestinal Morphology, Bacterial Load, *Eimeria* spp oocyst Excretion and Immune Response after Vaccination in Rabbits

Francesca Parisi, Simone Mancini, Maurizio Mazzei, Mario Forzan, Barbara Turchi, Stefania Perrucci, Alessandro Poli and Gisella Paci

Department of Veterinary Sciences, University of Pisa, Viale delle Piagge, 2 - 56124 Pisa, Italy

Article history

Received: 30-05-2018

Revised: 14-07-2018

Accepted: 01-08-2018

Corresponding Author:

Alessandro Poli

Department of Veterinary Sciences, University of Pisa

Viale delle Piagge, 2

56124 Pisa, Italy

Tel: +390502216982

Email: alessandro.poli@unipi.it

Abstract: Among plant products, tannins exhibited a strong antioxidant activity and their employment was studied as food or feed additive with positive effects. Nevertheless, their health-enhancing properties remain to be completely clarified, particularly in rabbits. The aim of the present study was to investigate the influence of a mix of chestnut and quebracho tannins as supplementation in rabbit diet on intestinal morphology, as well as bacterial loads and *Eimeria* spp coccidial oocyst excretion and humoral immune response after vaccination. Rabbits were fed four different diets: basal diet (negative control, group CN), basal diet with anticoccidial supplementation (positive control, group CP) and basal diet with tannins mix 0.3% (group T0.3) or 0.6% (group T0.6). Samples of intestine, liver, spleen thymus, mesenteric lymph nodes, kidney and heart were submitted to histopathologic investigations. Morphometric analyses were performed on portion of duodenum, jejunum and ileum. Intestinal contents were analyzed by flotation test for *Eimeria* spp. oocysts excretion and by microbiological assays for *Clostridium perfringens* and *Escherichia coli*. Rabbits belonging to the four experimental groups were vaccinated by means of a live attenuated myxomatosis virus and sera were collected individually at three time points to determine antibody response. The obtained results demonstrated the absence of toxic effects of the tannin mix on examined organs, particularly on liver and kidney and any negative influence on the growth performance. A relevant anti-inflammatory effect on the intestinal tract, a reduction of *Eimeria* spp. oocysts excretion and a positive immunomodulatory and antibacterial effects were also observed. Diets supplemented with the tannins mix affected also the morphology of examined intestinal tracts, particularly duodenum and ileum.

Keywords: Anti-bacterial and Anti-parasitic Activities, Immunomodulation, Intestine Morphology, Rabbits, Tannins

Introduction

Rabbit meat is an important Mediterranean product and it is also consumed in Central America and Asia (FAO, 2018). Since, the most important qualities of rabbit meat are colour, texture and flavour (Dalle Zotte, 2002), so lipid oxidation, due to high content of polyunsaturated fatty acids, represents the major problem leading to reduced shelf life, because of rancidity and colour deterioration (Liu *et al.*, 2009). Therefore,

methods that are effective, safe and low cost for controlling rabbit product stability are extremely important to meat rabbit industry.

Among plant products, tannins exhibited a strong antioxidant activity and their employment was studied as food or feed additive (Chung *et al.*, 1998). Tannins are a complex group of water-soluble polyphenolic compounds arising from higher plant metabolism and, based on their structure and characteristic, are classified into two main groups: hydrolysable tannins, polyesters of gallic acid

and various individual sugars and condensed tannins, polymers of flavonoids (Mueller-Harvey, 2001; Schofield *et al.*, 2001).

Consumption of tannin high doses can have several negative effects including hepatotoxicity, toxic nephrosis, feed intake depression and growth reduction, due to the reduction of protein digestibility and digestive enzymes activity and the damage of intestinal mucosa (Mueller-Harvey, 2006). On the other hand, tannins in various plant extracts act preventing the colonization of intestinal bacteria, protozoa and viruses (Min and Hart, 2003; Biagi *et al.*, 2010, Fraquelli *et al.*, 2015) and for this reason are widely used in traditional medicine to counter the incidence of diarrhoea and dysentery (Lewis, 2003).

Consequently, tannins are also used as feed supplementation in animal diet for their health-enhancing properties. One of the most commonly available commercial products containing hydrolysable tannins is an extract from sweet chestnut wood (*Castanea sativa*, Mill., 1768), while for condensed ones are quebracho (*Schinopsis* spp.) wood tannins.

In a preliminary study performed in growing rabbits in an enteropathy infected environment, the use of hydrolysable tannins from sweet chestnut wood demonstrated a positive effect on treated subjects with significantly reduced mortality rate and enhanced live weight (Maertens and Štruklec, 2006), but the causes of these positive effects were not investigated.

The aims of our study were to evaluate the effects on growth performance of two dietary doses of a mix of chestnut and quebracho tannins, never been tested before as supplementation in rabbit diet and to investigate the influence of tannins supplementation on intestinal morphology, as well as bacterial loads and *Eimeria* spp. oocyst counts and on the humoral immune response after vaccination. In addition, histopathologic investigations were also performed to assess the potential tannins toxicity.

Materials and Methods

Experimental Design and Feed Preparation

Rabbits of 30 days old were randomly housed in colony cages (3 rabbits/cage, 60×40 cm) made of galvanised wire net and equipped with feeders and automatic drinkers. Cages were randomly allotted into 4 distinct groups (10 cages per diet, 30 rabbits per diet). A basal diet which consisted in a commercial pellet (alfalfa meal, wheat bran, barley, sunflower meal, soya oil, beet pulp; proximate composition and fatty acid profile is reported in Table 1) was used as negative control diet (CN) and as base to formulate the other three diets.

Table 1: Proximate composition and fatty acid profile of control diet.

Chemical composition	g/kg as fed
Dry matter	890
Crude protein	157
Ether extract	43
Ash	86
Crude fiber	154
NDF	340
ADF	190
ADL	46
Fatty acids profile	
g/100g of total fatty acids	
SFA	33.5
MUFA	48.2
PUFA ω 3	10.5
PUFA ω 6	7.8

Two experimental diets were added respectively with 0.3% (diet T0.3) or 0.6% (diet T0.6) of Silvateam NUTRI P powder® (Ledoga S.r.l., San Michele Mondovì, Cuneo, Italy), a commercial mix of chestnut and quebracho tannins (tannin content at minimum 75%, producer declaration). A positive control diet (CP) was formulated adding 1 ppm of diclazuril as coccidiostatic drug. Rabbits were fed *ad libitum* and water was freely available from nipple drinkers. The experimental protocol was designed according to the guidelines of the current European and Italian Laws on the care and use of experimental animals (European directive 2010/63/UE, put into law in Italy with DL 26/2014). The trial was performed in a local farm under conventional rearing system.

Animals, Mortality and Morbidity Rate, Growth Performance and Sampling

One hundred and twenty 30 days old hybrid rabbits, with no gender performance were used in the study. During the whole experimental period (60 days) body weights and feed intake were registered weekly as well as any subject death and morbidity episode. After sixty days of trial (90 days of age) ten rabbits from each experimental diet group were electro-stunned and slaughtered by cutting carotid and jugular veins, in a local slaughter-house. Immediately, after slaughtering intestine, mesenteric lymph nodes, thymus, liver, kidney, lung heart and spleen samples were collected and fixed using buffered pH 7.4 formalin solution. Intestinal content of slaughtered rabbits from each group was aseptically collected in a sterile plastic tube for bacteriological examination, while individual rectal faecal samples were collected from all slaughtered rabbits for parasitological analyses.

Bacteriological Analysis

Five g of intestinal content samples were stored at refrigerated conditions until used. Samples were diluted in 45 mL of sterile saline solution (PBSS), homogenized

and processed. For *Clostridium perfringens* enumeration Tryptose Sulphite Cycloserine (TSC) agar added with egg yolk and Perfringens Selective Supplement containing D-cycloserine was employed. Plates were incubated at 37°C for 48 h in anaerobic conditions. For *Escherichia coli* enumeration Tryptone Bile X-Glucuronide (TBX) agar was employed with incubation at 44°C for 48 h. All media were purchased from Thermo Fisher Scientific, Milan, Italy.

Parasitological Investigations

Faecal samples were quali-quantitatively analysed by flotation test using a low density solution (specific gravity 1.2) (Coudert *et al.*, 1995) and by a modified McMaster method with a sensitivity of 20 oocysts/gram of faeces (OPG) (Permin and Hansen, 1998; Papeschi *et al.*, 2013), to assess the presence and number of *Eimeria* oocysts.

Immunological Study

At day 35 of life, all rabbits belonging to the four experimental groups were vaccinated by intradermal route by means of a live attenuated myxomatosis virus vaccine (Dervaximyxo SG33, Merial). A second dose was provided after 6 weeks.

A total of 220 sera were collected individually at three time points (TP): 56th (TP1), 77th before administration of the second vaccination dose (TP2) and 95th day of life (TP3). Sera were analysed by an ELISA kit for diagnosis of myxomatosis following manufacturer's instructions (IZS della Lombardia e dell'Emilia, Brescia, Italy). All sera were analysed to 5 dilution points (titre from 1:10 to 1:5120).

Histopathological and Morphological Investigations

All the slaughtered rabbits were submitted to anatomopathological investigations. Intestinal segment samples (about 5 cm in length) of duodenum, jejunum and ileum were excised and flushed with PBSS to remove all the contents. The segments from the duodenum were obtained 1 cm down the pylorus, from jejunum 5 cm distal to the ligament of Treitz and ileum, 5 cm to the end of ileum. Samples from liver, mesenteric lymph nodes, spleen, thymus, kidney, lung and heart were also collected. All tissue samples were fixed in buffered formalin solution pH 7.4 and routinely embedded in paraffin wax blocks, sectioned at 5 µm thickness, mounted on glass slides and stained with haematoxylin and eosin (HE). Intestinal histopathologic alterations were evaluated using a semi-quantitative scoring system as previously assessed by Biasato *et al.* (2016): absent/minimal (score = 0), mild (score = 1) and severe (score = 2). Four bright field images for each intestinal segment, were acquired at x10 magnification with a Leica Microsystem DFC490 digital camera mounted on Leica DMR microscope. Morphometrical

analyses were performed on 10 well-oriented and intact villi and 10 crypts chosen from each image of the three collected intestinal segments (Qaisrani *et al.*, 2014).

Statistical Analysis

Statistical analysis was performed using the statistical package SPSS Advanced Statistics 21.0 (SPSS Inc., Chicago, IL, USA). Chi square test was used to compare non parametric data, while ANOVA test was used to compare bacterial loads, *Eimeria* spp. oocyst excretion, immunological response after vaccination and data of morphometric analysis. Post hoc analysis was made by Bonferroni Test. Statistical significance was based on a 5% (0.05) significance level.

Results

Tannins Effect on Morbidity and Mortality Rates and Growth Performance

Rabbits morbidity was mainly caused by enteritis episodes which, in some cases, resulted in subject death. In the CN and CP groups the morbidity rate was 20% while in tannins treated rabbits (T0.3 and T0.6 groups) was 16.7% ($p > 0.05$). Consequently, the mortality rate was also higher (16.7%) in CN and CP groups than in T0.3 and T0.6 rabbit groups (10%; $p > 0.05$). Growth performance data, including feed intake, daily gain and feed conversion ratio are reported in Table 2.

No statistical significant variations were highlighted in growth performances of the four groups examined, particularly regarding feed intake, daily gain and feed conversion ratio.

Tannins Effect on Bacteriological Loads

All samples examined were below the detection limit for *C. perfringens*, while *E. coli* load was similar in CN, CP groups and in rabbits fed with the diet supplemented with 0.3% (T0.3) of tannin mix (3.6 ± 0.1 ; 4.31 ± 1.9 ; 3.71 ± 0.6 CFU g⁻¹, respectively). Interestingly, all samples from the T0.6 group presented an *E. coli* load lower than the detection limit, even if these differences were not statistically significant.

Tannins Effect on *Eimeria* spp. Oocyst Excretion

The results of quali-quantitative evaluation of coprological analysis are presented in Fig. 1.

After 60 days treatment, in the control group the oocyst load was 1080 ± 1701 OPG, while a drastic reduction of oocyst load was observed both in rabbits fed with the commercial pellet added with the coccidiostat (mean 375 ± 460 OPG) both in rabbits fed with the pellet supplemented with 0.3% (154 ± 158 OPG) and 0.6% (351 ± 378 OPG) of the tannins mix, even if these reductions were not statistically significant.

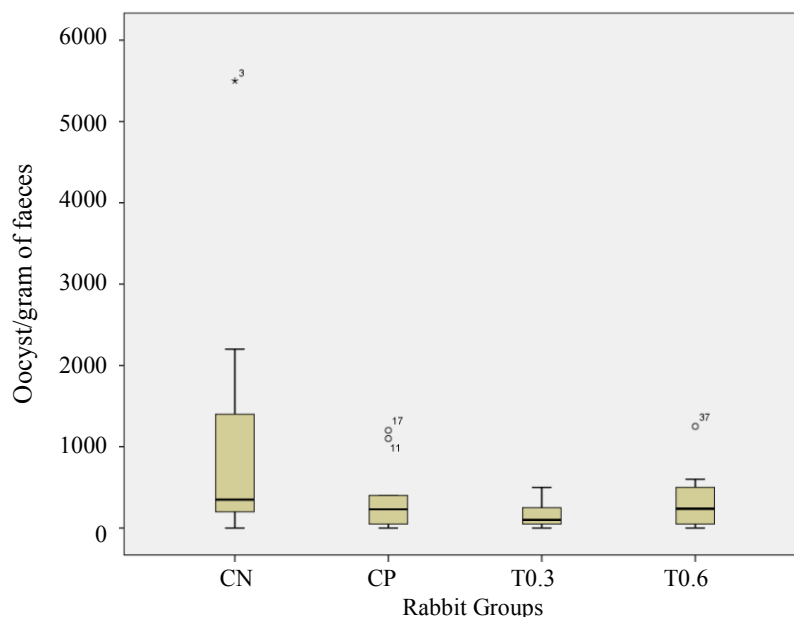


Fig. 1: *Eimeria* spp. oocyst excretion in control groups (CN= negative controls and CP= positive controls) and in rabbits fed diet added with 0.3% (T0.3) and 0.6% (T0.6) of chestnut and quebracho tannin mix.

Table 2: Growth performance in negative control rabbit group (CN), positive control rabbit group (CP) and in subjects fed diet added with 0.3% (T0.3) and 0.6% (T0.6) of chestnut e quebracho tannins during the trial.

	Diet				P-value
	CN	CP	T0.3	T0.6	
Initial BW (g)	826±89.3	826±88.3	829±85.2	822±82.8	0.9936
Final RW (g)	2785±221.7	2776±229.4	2773±239.6	2804±244.8	0.9629
ADG (g/head d)	31.9±3.57	31.5±4.08	30.8±3.25	31.6±3.87	0.7126
ADFI (g/head d)	89.8±4.58	88.41±4.64	92.85±7.32	89.80±1.63	0.2507
FCR	2.96±0.21	2.93±0.24	3.07±0.26	2.93±0.16	0.4715

BW: Body Weight, ADG: Average Daily Weight Gain, ADFI: Average Daily Feed Intake, FCR: Feed Conversion Ratio (kg feed ingested/kg of body weight gain). Data are reported as mean ± standard deviation.

Table 3: Anti-myxovirus antibody response after vaccination in negative control rabbit group (CN), positive control rabbit group (CP) and in subjects fed diet added with 0.3% (T0.3) and 0.6% (T0.6) of chestnut e quebracho tannins during the trial.

Time	Diet				RMSE	P-value
	CN	CP	T0.3	T0.6		
T1	1/2048	1/1577	1/1688	1/1333B	1/3.8	0.8809
T2	1/2550	1/1280	1/2215	1/1171B	1/3.1	0.2286
T3	1/800b	1/1220b	1/1938ab	1/3107a, A	1/3.0	0.001
RMSE	1/3.7	1/4.0	1/3.1	1/2.8		
P-value	0.0644	0.8805	0.7669	0.0054		

Values with different lowercase superscript in the row are significantly different. Values with different uppercase superscript in the column are significantly different. RMSE: Root Mean Square Error.

Tannins Effect on Immune Response after Vaccination

The results of serologic investigation are reported in Table 3.

Analysed sera showed specific anti-myxomatosis virus antibodies in 97.3% of ones tested. Both groups fed with tannin supplemented diet showed at T3 an increase of anti-myxomatosis virus antibodies in comparison to

non-supplemented tannin diets. A significative p-value was reported in 0.6% group (p<0.001).

Tannins Effect on Histopathological Features and Intestinal Morphology

Pathological investigation revealed histopathological changes in intestinal and lymphoid compartments in rabbits fed diet supplemented with the two concentrations of

tannins mix (Fig. 2), while no effects were detected in the other organs examined, particularly liver and kidney, which could represent possible target organs for these compounds.

Tannin mix supplementation demonstrated a marked anti-inflammatory activity on intestinal compartment, confirmed by the use of a semi-quantitative evaluation scoring system as reported in Table 4.

In relation with CN subjects, the dietary supplementation of 0.3% of tannin mix (T0.3 group) significantly affected the severity of histopathologic findings in the different segments of small intestine (duodenum $p<0.001$, jejunum $p<0.01$ and ileum $p<0.01$). Moreover, in T0.6 group rabbits a significant reduction of histopathological scores was detected at duodenum ($p<0.01$), jejunum ($p<0.01$) and ileum ($p<0.01$) level. Histopathological changes were also observed in lymphoid organs of subjects fed with the diet with tannin mix supplementation. In particular, a

marked hyperplasia of lymphatic follicles was evident in the spleen and lymph nodes.

The morphometric analysis allowed the quantification of morphologic changes revealed in the intestinal compartments and lymphoid organs (Fig. 3).

The traits affected by tannin supplementation were mainly the duodenum and ileum, while reduced effects were observed in the jejunum. In the duodenum, tannin supplementation was associated with a marked decrease of villus height both in subjects fed with the supplementation of the 0.3% of tannin mix compared with the CN group (T0.3 group mean = 649 ± 142 μm vs CN group mean = 842 ± 172 μm ; $p<0.0001$) both in rabbits fed with the supplementation of 0.6% (T0.6 group mean = 539 ± 124 μm vs CN group mean = 842 ± 172 μm ; $p<0.0001$). In addition, in the ileum tract the villus height was reduced in both groups (T0.3 group mean = 531 ± 194 μm and T0.6 group mean = 455 ± 123 μm vs CN group mean = 684 ± 135 μm ; $p<0.0001$).

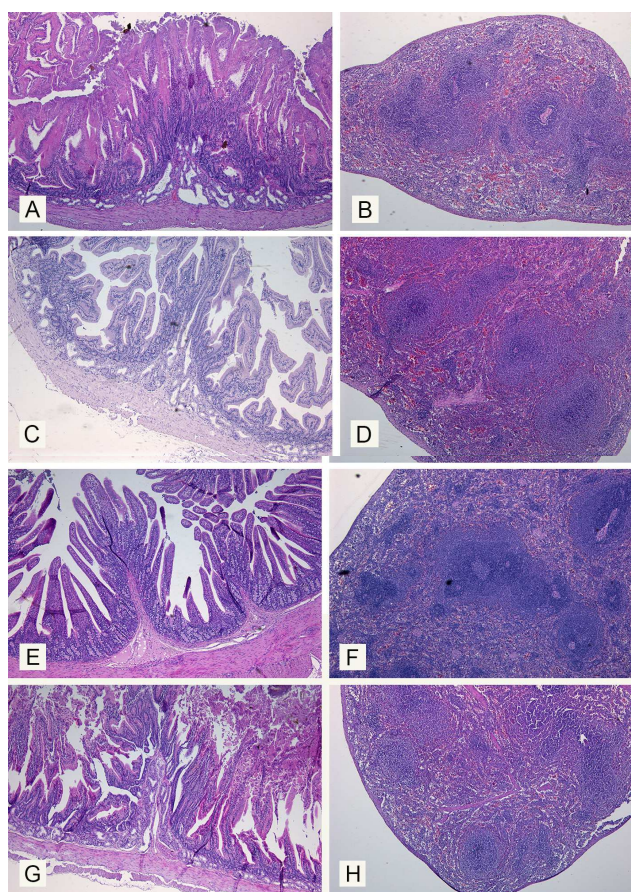


Fig. 2: Morphological changes in duodenum (A, C, E and G) and spleen (B, D, F and H) of rabbits fed control diets (negative controls, A and B; and positive controls, C and D) and with diet added with 0.3% (T0.3) and 0.6% (T0.6) of chestnut and quebracho tannin mix (E-H). A and B, CN group rabbit. Presence of a dense inflammatory infiltration of duodenum mucosa and submucosa. C and D, CP group rabbit. Reduced inflammatory infiltrates in the duodenum (C) and enlarged lymphoid follicles in the spleen (D). E and F, T0.3 group rabbit. Absence of inflammatory infiltration in the duodenum (E) and enlarged lymphoid follicles in the spleen (F). G and H, T0.6 group rabbit. reduced inflammatory infiltrates in the duodenum mucosa and submucosa (E) and lymphoid follicles in the spleen marked enlarged (H)

Table 4: Effect of dietary tannin supplementation on histopathological scores of intestinal tract in negative control rabbit group (CN), positive control rabbit group (CP) and in subjects fed diet added with 0.3% (T0.3) and 0.6% (T0.6) of chestnut e quebracho tannins during the trial.

Groups	Duodenum Scoring system			Jejunum Scoring system			Ileum Scoring system		
	0	1	2	0	1	2	0	1	2
CN	0	7	3	0	1	2	0	10	0
CP	6	3	1	0	4	6	0	5	5
0.3	9	1	0	4	6	0	6	4	0
0.6	7	2	1	4	5	1	4	5	1

Histological score system: 0 = absent/minimal lesions; 1 = mild lesions; 2 = severe lesions

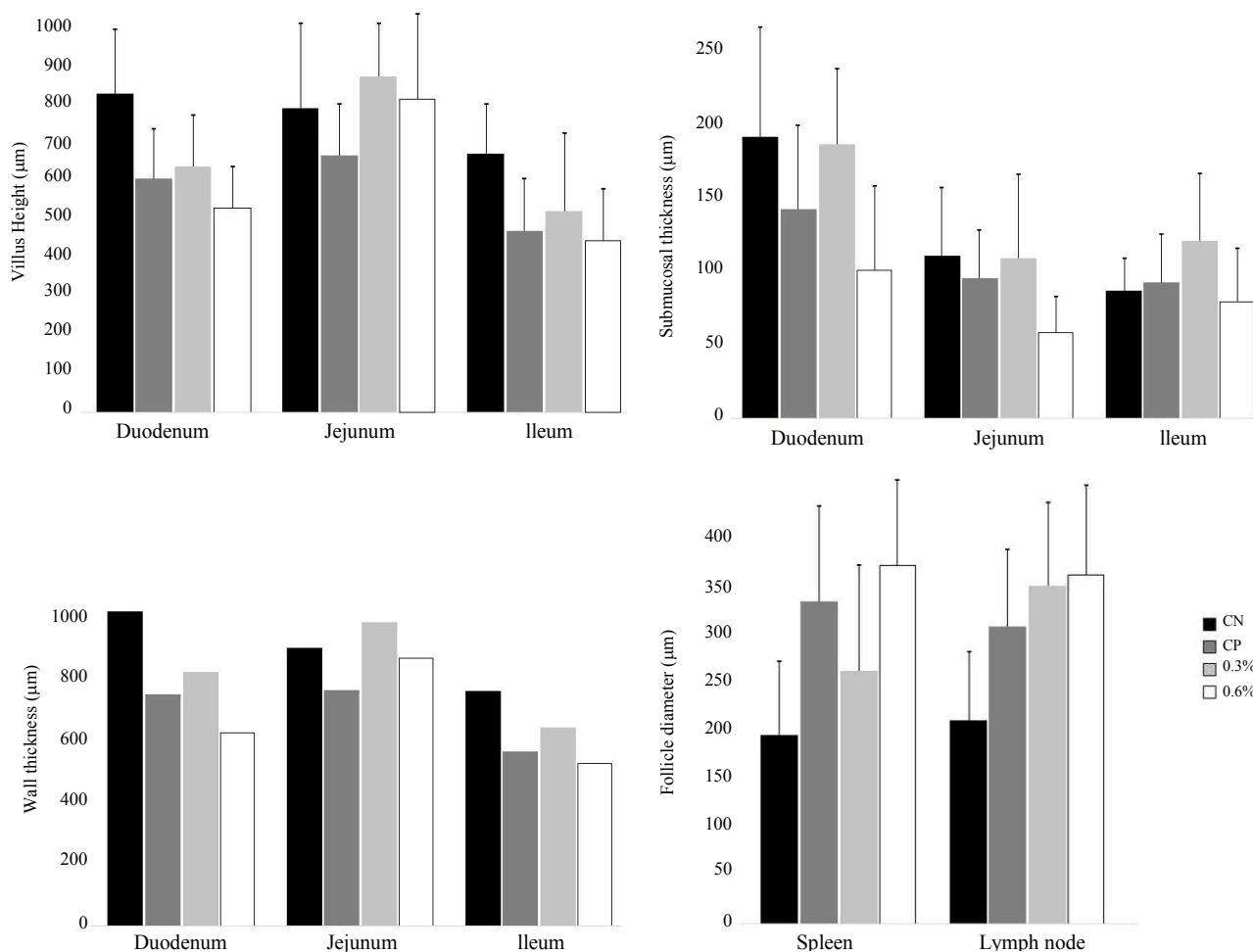


Fig. 3: Morphology of segments of small intestine and splenic and lymph nodal lymphoid follicles in rabbits fed control diets (CN= negative controls and CP= positive controls) and with diet added with 0.3% (T0.3) and 0.6% (T0.6) of chestnut and quebracho tannin mix.

In the T0.6 group the submucosal thickness was also reduced in the duodenum (T0.6 group mean = $101 \pm 40 \mu\text{m}$ vs CN group mean = $192 \pm 95 \mu\text{m}$; $p < 0.0001$), in the jejunum (T0.6 group mean = $59 \pm 43 \mu\text{m}$ vs CN group mean = $111 \pm 37 \mu\text{m}$; $p < 0.0001$) and ileum (T0.6 group mean = $80 \pm 32 \mu\text{m}$ vs CN group mean = $87 \pm 19 \mu\text{m}$; $p < 0.0001$). Consequently, the total thickness of the intestinal wall was reduced in duodenum and ileum (Fig. 3).

Morphological analysis allowed to quantify also the changes induced by tannins supplementation on lymphoid organs (Fig. 3). In particular, tannins supplementation increased the lymphoid follicle size in both spleen (T0.3 group mean = $265 \pm 104 \mu\text{m}$ and T0.6 group mean = $375 \pm 70 \mu\text{m}$ vs CN group mean = $198 \pm 75 \mu\text{m}$; $p < 0.001$ and $p < 0.0001$, respectively) and in the and lymph nodes (T0.3

group mean = $354 \pm 83 \mu\text{m}$ and T0.6 group mean = $364 \pm 82 \mu\text{m}$ vs CN group mean = $213 \pm 64 \mu\text{m}$; $p < 0.0001$).

Discussion

In contrast with the effect on ruminant animals, where tannins in the diet may have nutritional benefits (McSweeney *et al.*, 2001), tannins have been traditionally considered as anti-nutritional factors in monogastric farm animals, due to their ability to form stable complexes with dietary proteins and thereby reducing protein and amino acid digestibility (Smulikowska *et al.*, 2001). Recently, it has been recognized that these substances can be beneficial to farm animals and poultry (Bilić-Šobot *et al.*, 2016; Redondo *et al.*, 2014).

Our study confirmed that the adding of a tannin mix to diet of growing rabbits induced no significant differences in growth performance, feed intake, daily gain and feed conversion ratio of treated subjects. Similar results on live weight, productive traits, hot carcass weight and dressing percentage were observed in rabbits fed with a diet added with 0.5% and 1% of a similar natural extract of chestnut wood (Liu *et al.*, 2009). Previous studies indicated that hydrolysable tannins can improve growth performance, particularly when stress conditions were present. In fact, the use of tannins in rabbits fed a low protein amino acid supplemented diet (Zoccarato *et al.*, 2008), or the presence of an enteropathy infected environment (Maertens and Štruklec, 2006), or the presence of an adverse effect of high ambient temperature above evaporative critical temperature (Liu *et al.*, 2012) demonstrated to be able to improve the growth performance.

Another important property demonstrated by tannins diet supplementation is the ability to act as health enhancing compounds. The dietary role of tannins as food supplementation is recently receiving increasing interest as they may reduce the number of gastrointestinal parasites in mammals (Butter *et al.*, 2002; Min *et al.*, 2005; Fraquelli *et al.* 2015; Barone *et al.*, 2018) and birds (Marzoni *et al.*, 2005). Condensed tannins from green tea or quebracho have proven to have antimicrobial activity (Sakanaka *et al.*, 2000; Elizondo *et al.*, 2010) and to reduce gastrointestinal bacterial colonization in both pigs and chickens (Hara *et al.*, 1995; Hara, 1997) and *Eimeria* spp. oocyst counts in goat kids (Fraquelli *et al.*, 2015). Our results indicated that a mix of chestnut and quebracho tannins diet supplementation have a positive effect on the reduction on intestinal bacterial loads and *Eimeria* spp. oocyst counts in rabbits. The reduction of *Eimeria* spp. oocysts excretion was similar to that induced by the use of a coccidiostatic diet supplementation. The antimicrobial activity of these compounds was also demonstrated by the lower number of gastro-intestinal infections with bacterial aetiology observed in subjects

submitted to tannins treatment than in control groups. These antimicrobial activities have been indirectly demonstrated also by the study performed by Maertens and Štruklec (2006) who observed a reduced incidence of enteropathy and mortality in rabbits fed tannin-enriched diet.

Different works report the antiviral activity of some tannin against animal viruses, but the mechanisms responsible for this positive aspect remain still to be clarified. Although, hydrolysable and condensed tannins from different sources demonstrated an unspecific neutralizing effect on enveloped virus (Ueda *et al.*, 2013) and Fukuchi *et al.* (1989) and Cheng *et al.* (2002) demonstrated that tannic acid is able to inhibit the virus adsorption and penetration to the cells. On a different aspect, our study demonstrated that the tannin mix used in this study had a clear immunomodulatory effect, inducing an increased humoral immune response after vaccination in treated subjects. This immunomodulatory activity of the addition of chestnut tannin to the diet has been hypothesized in rabbits under high temperature stress (Liu *et al.*, 2012), evaluating the serum T3 and T4 levels, hormones involved in the maintenance of immune function response to environmental stimuli and stress mediated immunosuppression (Dorshkind and Horseman, 2001).

To our knowledge, this is the first study examining in details the histopathological effects of a mix of hydrolysable and condensed tannins used as supplementary diet in growing rabbits. The use of morphometric analysis of intestinal wall has been previously used to investigate the biomechanical properties of intestinal tissue remodelling in rabbits fed a low-residue diet (Liu *et al.*, 2017) and to evaluate the effect of tannin supplementation on intestine morphology in swine (Bilić-Šobot *et al.*, 2016) and demonstrated to be able to characterize the changes induced on the intestinal wall.

Although the intestinal compartment was the main target of our study, histopathological exam of tissue samples collected from rabbits fed tannin mix supplemented diet allowed to evaluate possible morphological changes in other target organs such as liver and kidney. A previous study performed in new born calves fed a chestnut extract in an amount of 0.02% of body mass or in combination with glycerol monolaurate revealed a toxic effect on liver function (Wieland *et al.*, 2015). Even if, in our study a careful investigation of liver and renal functions has not been performed, the lack of degenerative and necrotic changes in hepatocytes, glomeruli and renal tubular epithelium demonstrated the lack of toxicity of the tannin compound at the used doses.

Our investigations performed on intestinal compartment and particularly on small intestine demonstrated that supplementation of the diet with the tannin mix showed a drastic anti-inflammatory effect

which modified the morphology of the different intestinal segments. These changes involved mainly duodenum and ileum. In both segments the tannins mix supplementation induced a significant decrease in villus height and submucosal thickness, with a reduction of the all wall thickness. These results confirmed a previous study performed in fattening boars fed a diet supplemented with hydrolysable tannin in which the tannin diet supplementation had no unfavourable effects on intestinal morphology (Bilić-Šobot *et al.*, 2016). In this study, in contrast with our study, the tannin supplementation had a positive effect on intestinal morphology of treated pigs, with an increased villus height, villus perimeter and mucosal thickness. The different results obtained in our study could be explained with the strong anti-inflammatory activity of the tannin mix supplementation that in our rabbits drastically reduced the inflammatory infiltrates within the intestinal villi and submucosa and therefore induced a drastic reduction of their sizes.

Although tannins can show a positive anti-oxidant effect in rabbits (Liu *et al.*, 2009), the diet supplementation with hydrolysable and condensed tannins have a strong health-enhancing activity demonstrated by anti-coccidial and immunomodulatory activity, reduction of incidence of parasitic and bacterial diarrhoea and overall by a strong anti-inflammatory effect on small intestine and particularly on the duodenum and ileum. All these positive activities have been demonstrated in growing rabbits without altering the growth performances of treated subjects.

Conclusion

The use of these plant extracts appears as an alternative to the use of anti-microbial and anti-parasitic drugs, especially because they do not leave residues in derived products and would have fewer chances to induce resistance in microorganisms.

Acknowledgment

Authors thank Silvateam (Ledoga S.r.l.) for supplying tannins mix.

Funding Information

The research was funded by PRA (Progetti di Ricerca di Ateneo) number PRA_2017_43.

Author Contributions

Mazzei, Paci, Perrucci, Poli, Turchi: Conceiving and designed the study.

Mancini, Paci: Nutritional aspects and growth performance of rabbits.

Turchi: Bacteriological investigations.

Perrucci: Parasitological investigations.

Mazzei, Forzan: Virological and immunological analyses.

Parisi, Poli: Histopathological and morphometrical investigations.

Forzan, Mancini, Parisi, Perrucci, Turchi: Drafted the manuscript.

Mazzei, Paci, Perrucci, Poli: Revised the manuscript. All Authors read and approved the final version of the manuscript.

Conflict of Interest

The authors have no conflicting interests to declare.

References

- Barone, C.D., A.M. Zajac, L.A. Manzi-Smith, A.B. Howell and J.D. Reed *et al.*, 2018. Anthelmintic efficacy of cranberry vine extracts on ovine *Haemonchus contortus*. *Vet. Parasitol.*, 253: 122-129. DOI: 10.1016/j.vetpar.2018.02.016
- Biagi, G., I. Cipollini, B.R. Paulicks and F.X. Roth 2010. Effect of tannins on growth performance and intestinal ecosystem in weaned piglets. *Arch. Anim. Nutr.*, 64: 121-135. DOI: 10.1080/17450390903461584
- Biasato, I., M. De Marco, L. Rotolo, M. Renna and C. Lussiana *et al.*, 2016. Effects of dietary *Tenebrio molitor* meal inclusion in free-range chickens. *J. Anim. Physiol. Anim. Nutr.*, 100: 1104-1112. DOI: 10.1111/jpn.12487
- Bilić-Šobot, D., V. Kubale, M. Škrlep, M. Čandek-Potokar and M. Prevolnik Povše *et al.*, 2016. Effect of hydrolysable tannins on intestinal morphology, proliferation and apoptosis in entire male pigs. *Arch. Anim. Nutr.*, 70: 378-88. DOI: 10.1080/1745039X.2016.1206735
- Butter, N.L., J.M. Dawson, D. Wakelin and P.J. Butter, 2002. Effect of dietary condensed tannins on gastrointestinal nematodes. *J. Agric. Sci.*, 137: 461-469. DOI: 10.1017/S0021859601001605
- Cheng, H.Y., C.C. Lin and T.C. Lin, 2002. Antiviral properties of prodelphinidin B-2 3'-O-gallate from green tea leaf. *Antivir. Chem. Chemother.*, 13: 223-9.
- Chung, K.T., T.Y. Wong, Wei CI, Y.W. Huang and Y. Lin, 1998. Tannins and human health: A review. *Critical Reviews Food Sci. Nutr.* DOI: 10.1080/10408699891274273
- Coudert, P., D. Licois and F. Drouet-Viard, 1995. *Eimeria* and Isospora: *Eimeria* Species and Strains of Rabbits. In: *Biotechnology, Guidelines on Techniques in Coccidiosis Research*, Eckert J., R. Braun, M.W. Shirley and P. Coudert, (Eds.), Official Publications of the European Communities. Luxembourg, pp: 52-73.

- Dalle Zotte, A., 2002. Perception of rabbit meat quality and major factors influencing the rabbit carcass and meat quality. *Livestock Production Sci.*, 75: 11-32. DOI:10.1016/S0301-6226(01)00308-6
- Dorshkind, K. and N.D. Horseman, 2001. Anterior pituitary hormones, stress and immune system homeostasis. *Bioassays*, 23: 288-94.
- Elizondo, A.M., E.C. Mercado, B.C. Rabinovitz and M.E. Fernandez-Miyakawa, 2010. Effect of tannins on the *in vitro* growth of *Clostridium perfringens*. *Vet. Microbiol.*, 145: 308-14. DOI: 10.1016/j.vetmic.2010.04.003
- FAO, 2018. <http://www.fao.org/faostat/en/#data/QL>
- Fraquelli, C., S.A. Zanzani, A.L. Gazzonis, R. Rizzi and M.T. Manfredi, 2015. Effects of condensed tannin on natural coccidian infection in goat kids. *Small Ruminant Res.*, 126: 19-24.
- Fukuchi, K., H. Sakagami, T. Okuda, T. Hatano and S. Tanuma *et al.*, 1989. Inhibition of herpes simplex virus infection by tannins and related compounds. *Antiviral Res.*, 11: 285-97. DOI: 10.1016/0166-3542(89)90038-7
- Hara, H., N. Orita, S. Hatano, H. Ichikawa and Y. Hara *et al.*, 1995. Effect of tea polyphenols on fecal flora and fecal metabolic products of pigs. *J. Vet. Med. Sci.*, 57: 45-9.
- Hara, Y., 1997. Influence of tea catechins on the digestive tract. *J. Cell. Biochem. Suppl.*, 27: 52-8.
- Lewis, W.H., 2003. *Medical Botany: Plants Affecting Human Health*. 2nd Edn., John Wiley and Sons, Hoboken, pp: 459-485.
- Liu, H., D. Zhou, J. Tong and V. Vaddella, 2012. Influence of chestnut tannins on welfare, carcass characteristics, meat quality and lipid oxidation in rabbits under high ambient temperature. *Meat. Sci.*, 90: 164-9. DOI: 10.1016/j.meatsci.2011.06.019
- Liu, H., F. Gai, L. Gasco, A. Brugiapaglia and C. Lussiana *et al.*, 2009. Effects of chestnut tannins on carcass characteristics, meat quality, lipid oxidation and fatty acid composition of rabbits. *Meat. Sci.*, 83: 678-683. DOI: 10.1016/j.meatsci.2009.08.003
- Liu, Y., J. Zhao, D. Liao, L. Bao and H. Gregersen, 2017. Low-residue diet fed to rabbits induces histomorphological and biomechanical remodeling of small intestine. *Neurogastroenterol. Motil.* DOI: 10.1111/nmo.12983
- Maertens, L. and M. Štruklec, 2006. Technical note: preliminary results with a tannin extract on the performance and mortality of geowing rabbits in an enteropathy infected environment. *World Rabbit Sci.*, 14: 189-192.
- Marzoni, M., A. Castillo and I. Romboli, 2005. Effect of dietary inclusion of quebracho (*Schinopsis lorentzii*) tannins of productive performances of growing pheasant females. *Ital. J. Anim. Sci.*, 4: 507-509. DOI: 10.4081/ijas.2005.2s.507
- McSweeney, C., S. Palmer, B. McNeill and D.M. Krause, 2001. Microbial interactions with tannins: Nutritional consequences for ruminants. *Animal Feed Sci. Technol.*, 91: 83-93. DOI: 10.1016/S0377-8401(01)00232-2
- Min, B.R. and S.P. Hart, 2003. Tannins for suppression of internal parasites. *J. Anim. Sci.*, 81: E102-E109.
- Min, B.R., S.P. Hart, D. Miller, G.M. Tomita and E. Loetz *et al.*, 2005. The effect of grazing forage containing condensed tannins on gastro-intestinal parasite infection and milk composition in Angora does. *Vet. Parasitol.*, 130: 105-13. DOI: 10.1016/j.vetpar.2005.03.011
- Mueller-Harvey, I., 2001. Analysis of hydrolysable tannins. *Anim. Feed Sci. Technol.*, 91: 3-20. DOI: 10.1016/S0377-8401(01)00227-9
- Mueller-Harvey, I., 2006. Unravelling the conundrum of tannins in animal nutrition and health. *J. Sci. Food Agr.*, 86: 2010-2037. DOI: 10.1002/jsfa.2577
- Papeschi, C., G. Fichi and S. Perrucci, 2013. Oocyst excretion pattern of three intestinal *Eimeria* species in female rabbits. *World Rabbit Sci.*, 21: 77-83. DOI: 10.4995/wrs.2013.1235
- Permin, A. and J. Hansen, 1998. The epidemiology, diagnosis and control of poultry parasites. In: *FAO Animal Health Manual*. FAO, Rome, Italy.
- Qaisrani, S.N., P.C. Moquet, M.M. van Krimpen, R.P. Kwakkel and M.W. Verstegen *et al.*, 2014. Protein source and dietary structure influence growth performance, gut morphology and hindgut fermentation characteristics in broilers. *Poult. Sci.*, 12: 3053-64. DOI: 10.3382/ps.2014-04091
- Redondo, L.M., P.A. Chacana, J.E. Dominguez and M.E. Fernandez Miyakawa, 2014. Perspectives in the use of tannins as alternative to antimicrobial growth promoter factors in poultry. *Front Microbiol.*, 5: 118-118. DOI: 10.3389/fmicb.2014.00118. eCollection 2014
- Sakanaka, S., L.R. Juneja and M. Taniguchi, 2000. Antimicrobial effects of green tea polyphenols on thermophilic spore-forming bacteria. *J. Biosci. Bioeng.*, 90: 81-5. DOI: 10.1016/S1389-1723(00)80038-9
- Schofield, P., D.M. Mbugua and A.N. Pell, 2001. Analysis of condensed tannins: A review. *Anim. Feed Sci. Technol.*, 91: 21-40. DOI: 10.1016/S0377-8401(01)00228-0
- Smulikowska, S., B. Patuszewska, B. Swiech, A. Ochtabinska and A. Mieczkowska *et al.*, 2001. Tannin content affects negatively nutritive value of pea for monogastics. *J. Anim. Feed Sci.*, 10: 511-521. DOI: 10.22358/jafs/68004/2001
- Ueda, K., R. Kawabata, T. Irie, Y. Nakai and Y. Tohya *et al.*, 2013. Inactivation of pathogenic viruses by plant-derived tannins: Strong effects of extracts from persimmon (*Diospyros kaki*) on a broad range of viruses. *Send PLoS One*, 8: e55343. DOI: 10.1371/journal.pone.0055343

- Wieland, M., B.K. Weber, A. Hafner-Marx, C. Sauter-Louis and J. Bauer *et al.*, 2015. A controlled trial on the effect of feeding dietary chestnut extract and glycerol monolaurate on liver function in newborn calves. *J. Anim. Physiol. Anim. Nutr.*, 99: 190-200. DOI: 10.1111/jpn.12179
- Zoccarato, I., L. Gasco, A. Schiavone, K. Guo and P. Barge *et al.*, 2008. Effect of extract of chestnut wood inclusion (ENC) in normal and low protein amino acid supplemented diets on heavy broiler rabbits. *Proceeding of the 9th World Rabbit Congress*, June 10-13, Verona (Italy), pp: 873-874.

Highlights

- Hydrolysable and condensed tannins mix was tested as dietary supplementation in rabbits.
- Histopathologic studies demonstrated the absence of toxic effect of tannin mix used.
- The dietary tannins induced morphologic changes of duodenum tract and had an important anti-inflammatory effect.
- The tannins mix demonstrated also anti-bacterial and anti-coccidial activities and a positive immunomodulatory effect.