

Atlas occipitalisation associated with other anomalies in a 16th century skeleton from Sardinia (Italy)

V. Giuffra^{1, 2}, A. Montella², M. Milanese³, E. Tognotti², D. Caramella⁴, P. Bandiera²

¹Division of Paleopathology, Department of Translational Research and New Technologies in Medicine and Surgery, University of Pisa, Italy

²Centre for Anthropological, Palaeopathological and Historical Studies of the Sardinian and Mediterranean Populations, Department of Biomedical Sciences, University of Sassari, Italy

³Department of History, Human Sciences and Education, University of Sassari, Italy

⁴Division of Diagnostic and Interventional Radiology, Department of Translational Research and New Technologies in Medicine and Surgery, University of Pisa, Italy

[Received: 9 March 2016; Accepted: 7 May 2016]

Archaeological excavations carried out in the plague cemetery of 16th century Alghero (Sardinia) brought to light the skeleton of a male aged 35–45 years, showing anomalies of the atlas. A macroscopic and radiological study has been carried out. The first cervical vertebra is fused with the skull base, resulting in an occipitalisation of the atlas. Absence of the costal element of the left foramen transversarium, resulting in an open anterior foramen transversarium, and posterior arch defect are also observed. The atlanto-occipital junction is a complex structure, susceptible to develop different patterns of congenital defects. These anatomical variations of atlas should be considered in modern clinical practice in order to formulate a correct diagnosis and to conceive an appropriate treatment. Osteoarchaeological cases are important as, beside to ascertain the presence of congenital defects in past populations, allow an in-depth study in dry bones, which can help modern medicine in interpreting anatomical variations. We present an association of congenital anomalies of the atlanto-occipital junction, a condition rarely documented in ancient and modern human skeletal remains. (Folia Morphol 2017; 76, 1: 123–127)

Key words: atlas occipitalisation, absence of the costal element of the left foramen transversarium, posterior arch defect, Sardinia, modern age

INTRODUCTION

The transitional regions of the spine are privileged sites of anatomic variations, including the craniovertebral junction.

The atlas is the first cervical vertebra and is a ring-like structure, consisting of anterior and posterior arches and two lateral masses along with the transverse processes. The chief peculiarity of the atlas is

that it has no body. The atlas cranially connects the skull with spine, forming the atlanto-occipital joint, whereas caudally it articulates with axis, forming the atlanto-axial joint. The atlas transmits the weight from the skull to the spine, thus facilitating complex biomechanical movements of the neck. In addition, the first cervical vertebra paves the way for spinomedullary junction through vertebral foramen, and serves for

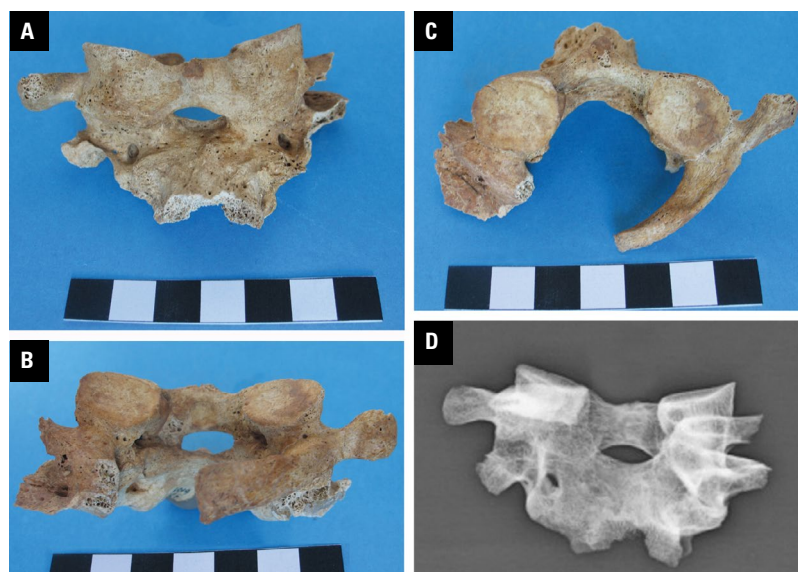


Figure 1. Anterior view of the occipitalised atlas (A); posterior view of the occipitalised atlas; posterior arch defect is evident (B); superior view of the occipitalised atlas (C); frontal projection (D).

the transmission of the vertebral artery and the first spinal nerve over superior surface of posterior arch.

The complexity of atlar structure makes it the most favourable for anatomical variations of all the vertebrae; therefore, it represents a highly vulnerable skeletal tract, being susceptible to develop different patterns of congenital defects. These anatomical variations of atlas should be considered in modern clinical practice in order to formulate a correct diagnosis and to conceive an appropriate treatment [14].

We present an association of anomalies observed in the atlas of a skeleton from 16th century Sardinia.

MATERIALS AND METHODS

Archaeological excavations carried out in the courtyard of the former College of the Jesuits in San Michele — Lo Quarter in Alghero (Sardinia) brought to light the skeletal remains of 200 individuals [12]. In particular, 16 trenches containing the remains of 10 to 30 individuals, and 10 multiple burials with an average number of 6 skeletons, were discovered. Arrangement of the corpses demonstrated that the individuals died in a short lapse of time and were buried simultaneously. Both archaeological dating and burial modalities strongly suggest that the skeletal remains belong to the victims of the plague that hit Alghero in 1582–1583.

A skeleton (code number: 5125) exhumed from trench 13, which contained 16 individuals, showed anomalies of the atlas. The cranium and post-cranial skeleton were well preserved.

Determination of sex, age at death and stature was performed on the basis of standard methods used in physical anthropology [3].

Paleopathological study included both macroscopic and radiological examination. For conventional X-rays a FCR Velocity (Fujifilm) computed radiography system was used, with the following parameters: 10–12 mAs with 54–60 keV, distance focus film 110 cm. Computed tomography (CT) was carried out with a CT Aquilion 16 scanner (Toshiba), 100 kVp, 100 mA, rotation time 0.5 s, slice thickness 1 mm, field of view 16 × 16 cm.

RESULTS

The skeletal remains belong to a male aged 35–45 years old, 167 cm tall.

The first cervical vertebra is fused with the skull base, resulting in an occipitalisation of the atlas.

The atlas and occipital bone had been damaged postmortem, and the remaining fragment exhibited complete fusion of the superior articular facets with the occipital condyles, and of the anterior arch with the anterior rim of the foramen magnum; however, a small slit-like opening was found above the anterior tubercle. In anterior view a slight inclination of the atlas toward the right side, resulting in an asymmetry, could be appreciated (Fig. 1A). The posterior surface of the anterior arch presented a normal circular facet for articulation with the odontoid process of the axis vertebra (Fig. 1B). Absence of the costal element of

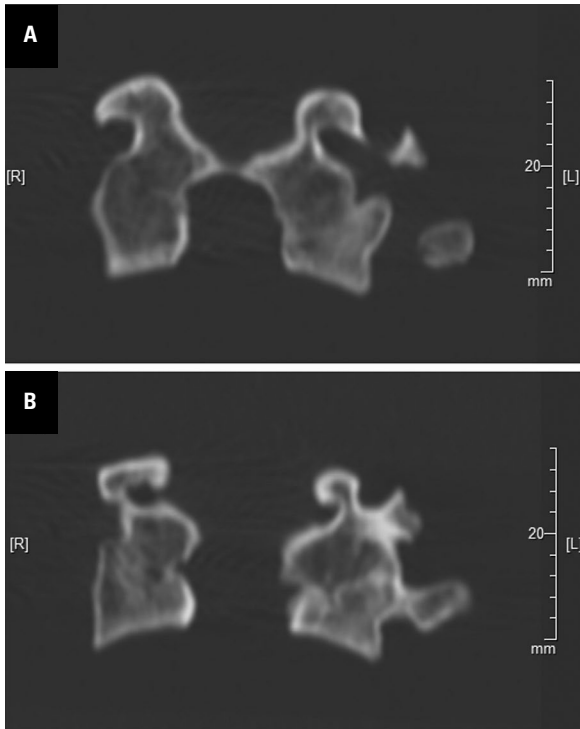


Figure 2. A, B. Coronal reformatted computed tomography images of the occipitalised atlas on two parallel planes.

the left foramen transversarium is observed, resulting in an open anterior foramen transversarium; the anterior hypoglossal canal was intact and normal in appearance (Fig. 1C). On the right side the postmortal breakage prevented to ascertain if the foramen transversarium is open. The right transverse process and right posterior arch had broken off postmortem. Nevertheless, the left posterior arch presented no evidence of fusion with the posterior margin of the foramen magnum. On the right side the postmortal breakage allowed to suspect a fusion of the posterior arch with the margin of foramen magnum, at least in its initial portion. Another anomaly associated with occipitalisation consisted in posterior spondyloschisis of the atlas: although the right posterior arch was missing, the left posterior arch showed an unfused end (Fig. 1B–C). X-ray (Fig. 1D) and coronal CT (Fig. 2A, B) confirm the fusion.

In the axis a slight inclination of the odontoid process toward the right side was visible (Fig. 3A). No other congenital alterations were observed in the axis and the other preserved vertebrae.

The temporo-mandibular joint showed alterations: the mandibular fossa of the right temporal bone was flattened (Fig. 3B) and the right condyle was

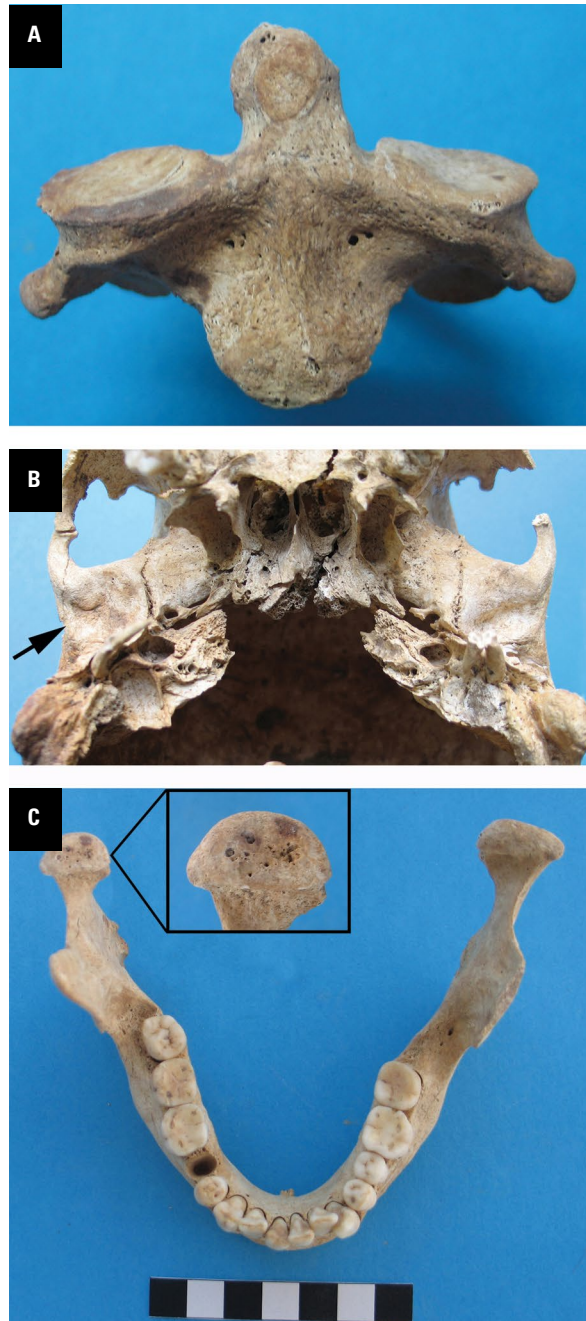


Figure 3. Anterior view of the axis (A); inferior view of the skull evidencing flattening of the right glenoid fossa (B); superior view of the mandible, evidencing porosis and osteoarthritic changes of the right condyle (C).

deformed and presented porosities as a result of osteoarthritic changes (Fig. 3C).

DISCUSSION

Congenital bony fusion of the first cervical vertebra with the occipital bone is referred to as occipitalisation of the atlas, as well as assimilation of the

atlas, atlanto-occipital fusion, and occipito-cervical synostosis [1]. The fusion can be partial or complete, unilateral or bilateral. Partial fusion involving the anterior arch of the atlas and the anterior rim of the foramen magnum is the less frequent variant and is associated with other skeletal malformations such as basilar invagination, occipital vertebra, spina bifida of the atlas, Klippel-Feil syndrome, and Arnold Chiari I malformation [16].

The congenital anomaly has a current incidence of 0.67% to 3.63% in Asian populations, without a sex predilection [13]; in Caucasians the incidence is lower, being 0.5% to 1% [6]. In modern clinical practice this condition is usually an incidental or autptic finding [1].

Assimilation of the atlas to the occipital bone has a clinical relevance due to its proximity to the spinomedullary region. This anomaly generally results in the immobility of the craniovertebral joint and is generally associated with restricted head and neck movements and torticollis. Atlar occipitalisation is responsible for possible neurological disturbances, ranging from transitory headaches to true neurological syndromes, such as numbness and pain in the limbs, weakness and disturbances in balance [19]. In particular, a complete occipitalisation can result in compression of the vertebral artery, which may cause dizziness, seizures, and fainting, as a consequence of reduced blood flow to the brain [9]. The symptoms very seldom appear at an early age and manifestation usually begins from the second decade onwards [15]. For these reasons the knowledge of this condition is of relevance for neurologists, neurosurgeons and radiologists.

Congenital causes of atlar occipitalisation are due to disorders in the development of occipital and cervical sclerotomes in the third and fourth weeks of foetal life; in particular, a failure of segmentation and separation of the most caudal occipital sclerotome and the first cervical sclerotomes takes place; in this anomaly the caudal part of the fourth occipital sclerotome fuses with the entire first cervical sclerotome and the cranial part of the second one [2, 16].

The individual from Alghero presents a partial assimilation, involving the anterior arch of the atlas and the anterior rim of the foramen magnum. The inclination of the atlas is very small and therefore it could have caused only slight tilting of the head to the left side and possibly torticollis; the presence of anomalies also in the axis and at the level of tem-

poro-mandibular joint strengthens this hypothesis. In fact, the slight inclination of the atlas toward the right could have caused both the deformity of the dens of the axis and of the right mandibular fossa flattening.

The probable unfusion between the posterior arch and the posterior margin of the foramen magnum allows ruling out an impairment of the vertebral arteries or of the first cervical spinal nerves, which pass over the most anterior part of the posterior arch of the atlas; therefore, the individual had probably not experienced any neurological disturbances.

The assimilation of the atlas can also be responsible for other neurological symptoms, if there is a significant reduction in the size of the foramen magnum; this feature results in a possible compression of the spinal cord or brain stem. In particular, a reduced sagittal diameter is considered associated with symptoms [20], and measurements less than 30 mm are abnormal [8]. In our case the postmortal breakage prevented measuring the sagittal diameter and therefore it was not possible to argue whether the individual was symptomatic.

In the skeleton from Alghero occipitalisation of the atlas is associated with absence of the costal element of the left foramen transversarium and with posterior arch defect.

Foramina transversaria of the cervical vertebrae permit the passage of the vertebral artery and consist of anterior and posterior parts; anterior portion is homologue of the rib in thoracic region, and therefore named as costal process or element. Recent studies demonstrated an incidence of absence of the costal element ranging from 2% [4] to 10% [18]; in unilateral defects there is a prevalence for the right side. This variation is attributed to a developmental defect or to variations in the course of the vertebral artery and should be considered in modern clinical practice as it may expose the vertebral vessels to the risk of being damaged [4].

Posterior arch defects are classified by Currarino et al. [5] in five types (A–E), depending on the extent of absence of the posterior arch and the presence or absence of the posterior tubercle. According to this classification the anomaly observed in the skeleton from Alghero is a type A arch defect, consisting in a failure of midline fusion of the two hemiarches, with a small gap remaining. In modern clinical studies type A defect was seen with an incidence of 2.6% [17] to 3.2% [7]. Posterior arch defects are attrib-

uted to the defective or absent development of the cartilaginous preformation of the arch rather than a disturbance of the ossification [11]. Congenital posterior arch defects are generally asymptomatic and are considered benign anatomical variations; however, as in asymptomatic individuals they may become dangerous in the context of trauma, it is important to distinguish between a bony injury and a congenital anomaly [10].

CONCLUSIONS

We present an association of congenital anomalies of the atlanto-occipital junction, a condition rarely documented in ancient human skeletal remains. The small number of published archaeological cases of congenital anomalies of the atlas makes any report important. Osteoarchaeological cases are important as, beside to ascertain the presence of congenital defects in past populations, allow an in-depth study in dry bones, which can help modern medicine in interpreting anatomical variations.

Acknowledgments

We would like to thank Prof. Gino Fornaciari (Department of Translational Research and New Technologies in Medicine and Surgery, University of Pisa) for revising the manuscript and Davide Giustini (Division of Diagnostic and Interventional Radiology, University of Pisa) for help in the radiological study.

The research was funded by RAS Legge regionale 7 agosto 2007, n. 7, bando 2010.

REFERENCES

- Al-Motabagani MA, Surendra M. Total occipitalization of the atlas. *Anat Sci Int.* 2006; 81(3): 173–180, doi: [10.1111/j.1447-073X.2006.00129.x](https://doi.org/10.1111/j.1447-073X.2006.00129.x), indexed in Pubmed: [16955668](https://pubmed.ncbi.nlm.nih.gov/16955668/).
- Black S, Scheuer L. Occipitalization of the atlas with reference to its embryological development. *Int J Osteoarchaeol.* 1996; 6: 189–194.
- Buikstra J, Ubelaker D. Standards for Data Collection from Human Skeletal Remains. *Arkansas Archaeological Survey Research Series No. 44*, Fayetteville, 1994.
- Chauhan R, Khanna J. Absence of costal element of the foramen transversarium of atlas vertebrae. *Int J Res Med Sci.* 2013; 1(2): 66–68, doi: [10.5455/2320-6012.ijrms20130505](https://doi.org/10.5455/2320-6012.ijrms20130505).
- Currarino G, Rollins N, Diehl JT. Congenital defects of the posterior arch of the atlas: a report of seven cases including an affected mother and son. *AJNR Am J Neuro-radiol.* 1994; 15(2): 249–254, doi: [10.7439/ijbr.v4i12.438](https://doi.org/10.7439/ijbr.v4i12.438), indexed in Pubmed: [8192068](https://pubmed.ncbi.nlm.nih.gov/8192068/).
- Esses SI. *Textbook of spinal disorders*. JB Lippincott, Philadelphia, 1995.
- Guenkel S, Schlaepfer S, Gordic S, et al. Incidence and variants of posterior arch defects of the atlas vertebra. *Radiol Res Pract.* 2013; 2013: 957280, doi: [10.1155/2013/957280](https://doi.org/10.1155/2013/957280), indexed in Pubmed: [24109510](https://pubmed.ncbi.nlm.nih.gov/24109510/).
- Hayes M, Parker G, Ell J, et al. Basilar impression complicating osteogenesis imperfecta type IV: the clinical and neuroradiological findings in four cases. *J Neurol Neurosurg Psychiatr.* 1999; 66(3): 357–364, doi: [10.1136/jnnp.66.3.357](https://doi.org/10.1136/jnnp.66.3.357), indexed in Pubmed: [10084535](https://pubmed.ncbi.nlm.nih.gov/10084535/).
- Kassim NM, Latiff AA, Das S, et al. Atlanto-occipital fusion: an osteological study with clinical implications. *Bratisl Lek Listy.* 2010; 111(10): 562–565, indexed in Pubmed: [21125803](https://pubmed.ncbi.nlm.nih.gov/21125803/).
- Klimo P, Blumenthal DT, Couldwell WT. Congenital partial aplasia of the posterior arch of the atlas causing myelopathy: case report and review of the literature. *Spine.* 2003; 28(12): E224–E228, doi: [10.1097/01.BRS.0000065492.85852.A9](https://doi.org/10.1097/01.BRS.0000065492.85852.A9), indexed in Pubmed: [12811285](https://pubmed.ncbi.nlm.nih.gov/12811285/).
- Kwon JK, Kim MS, Lee GJ. The incidence and clinical implications of congenital defects of atlantal arch. *J Korean Neurosurg Soc.* 2009; 46(6): 522–527, doi: [10.3340/jkns.2009.46.6.522](https://doi.org/10.3340/jkns.2009.46.6.522), indexed in Pubmed: [20062566](https://pubmed.ncbi.nlm.nih.gov/20062566/).
- Milanese M ed. *Lo scavo del cimitero di San Michele ad Alghero (fine XIII – inizi XVII secolo)*. Felici Editore, Pisa, 2010.
- Mudaliar RP, Shetty S, Nanjundaiah K, et al. An osteological study of occipitocervical synostosis: its embryological and clinical significance. *J Clin Diagn Res.* 2013; 7(9): 1835–1837, doi: [10.7860/JCDR/2013/6611.3327](https://doi.org/10.7860/JCDR/2013/6611.3327), indexed in Pubmed: [24179875](https://pubmed.ncbi.nlm.nih.gov/24179875/).
- Rajani S. Is variant anatomy of atlas clinically important? A review. *Basic Sci Med.* 2014; 3: 1–7.
- Ranade AV, Rai R, Prabhu LV, et al. Atlas assimilation: a case report. *Neuroanatomy.* 2007; 6: 32–33.
- Saini V, Singh R, Bandopadhyay M, et al. Occipitalization of the atlas: Its occurrence and embryological basis. *Int J Anat Variat.* 2009; 2: 65–68.
- Senoglu M, Safavi-Abbasi S, Theodore N, et al. The frequency and clinical significance of congenital defects of the posterior and anterior arch of the atlas. *J Neurosurg Spine.* 2007; 7(4): 399–402, doi: [10.3171/SPI-07/10/399](https://doi.org/10.3171/SPI-07/10/399), indexed in Pubmed: [17933313](https://pubmed.ncbi.nlm.nih.gov/17933313/).
- Sethi M, Vasudeva N, Mishra S. Study of foramen transversaria of first cervical vertebrae and its variations. *OA Anatomy.* 2014; 2: 25.
- Sharma M, Singh B, Abhaya A, et al. Occipitalization of atlas with other associated anomalies of skull. *Eur J Anat.* 2008; 12: 159–167.
- Tun K, Okutan O, Kaptanoglu G, et al. Inverted hypertrophy of occipital condyles associated with atlantooccipital fusion and basilar invagination: a case report. *Neuroanatomy.* 2004; 3: 43–45.