


Accepted Manuscript

Neospora caninum oocyst shedding in a naturally infected dog from Italy

Stefania Perrucci, Alessandra Gavazza, Guido Rocchigiani, Simona Nardoni, Alina Zbriger, George Lubas, Francesca Mancianti



PII: S2405-9390(16)30148-4
DOI: doi: [10.1016/j.vprsr.2017.01.005](https://doi.org/10.1016/j.vprsr.2017.01.005)
Reference: VPRSR 62

To appear in: *Veterinary Parasitology: Regional Studies and Reports*

Received date: 29 July 2016
Accepted date: 17 January 2017

Please cite this article as: Stefania Perrucci, Alessandra Gavazza, Guido Rocchigiani, Simona Nardoni, Alina Zbriger, George Lubas, Francesca Mancianti, Neospora caninum oocyst shedding in a naturally infected dog from Italy. The address for the corresponding author was captured as affiliation for all authors. Please check if appropriate. *Vprsr*(2017), doi: [10.1016/j.vprsr.2017.01.005](https://doi.org/10.1016/j.vprsr.2017.01.005)

This is a PDF file of an unedited manuscript that has been accepted for publication. As a service to our customers we are providing this early version of the manuscript. The manuscript will undergo copyediting, typesetting, and review of the resulting proof before it is published in its final form. Please note that during the production process errors may be discovered which could affect the content, and all legal disclaimers that apply to the journal pertain.

**NEOSPORA CANINUM OOCYST SHEDDING IN A NATURALLY INFECTED DOG
FROM ITALY**

**Stefania Perrucci*, Alessandra Gavazza, Guido Rocchigiani, Simona Nardoni, Alina Zbriger,
George Lubas, Francesca Mancianti**

Dipartimento di Scienze Veterinarie, Università di Pisa. Viale delle Piagge n. 2, 56124 Pisa (Italy)

***Corresponding author:** Stefania Perrucci, Dipartimento di Scienze Veterinarie, Università di
Pisa. Viale delle Piagge n. 2, 56124 Pisa (Italy). Tel. +39 050 2216949; Fax +39 050 0502210654;
Email: stefania.perrucci@unipi.it

Short Title: *Neospora caninum* oocysts in a dog from Italy

Author email addresses

Stefania Perrucci: stefania.perrucci@unipi.it

Alessandra Gavazza: alessandra.gavazza@vet.unipi.it

Guido Rocchigiani: guido.rocchigiani.g@gmail.com

Simona Nardoni: simona.nardoni@unipi.it

Alina Zbriger: miew_catz@hotmail.com

George Lubas: george.lubas@unipi.it

Francesca Mancianti: francesca.mancianti@unipi.it

Abstract

Although the seroprevalence of *Neospora caninum* infection in dogs can be relatively high, there are few reports of dogs naturally shedding *N. caninum* oocysts. Worldwide, the prevalence of *Neospora* excretion in canine faeces ranges from 0.03% to 4.9%.

A mixed-breed male household dog of about 8 years in age living in the district of Pisa (Tuscany, Central Italy) was referred for dysorexia, weakness and general lymph node enlargement. Clinical pathology demonstrated mild normocytic and normochromic anaemia, thrombocytopenia and hypoproteinemia with hypoalbuminemia. Serology for *Leishmania*, *Ehrlichia canis* and *Anaplasma phagocytophilum* was negative. From lymph node and bone marrow analysis, T cell lymphoma, high grade, pleomorphic type, clinical stage V, was diagnosed. The dog was treated with a chemotherapy induction protocol with vincristine, cyclophosphamide, and prednisone for 8 weeks. A faecal sample collected from the dog 7 days after the beginning of the treatment and analysed by flotation test and a McMaster method, revealed the presence of 300 OPG *N. caninum*-like unsporulated oocysts of about 10-11 μm in diameter. An aliquot of the same faecal sample analysed by PCR with species-specific primer pairs Np6+/Np21+ was positive for *N. caninum* DNA, while specific serology performed on sera collected at the first visit and a month later by IFAT, were positive with a titer of 1: 50 and 1:400, respectively. Soon after the dog died.

Naturally occurring systemic illness or iatrogenic immunosuppression may predispose dogs to proliferation of the parasite. The dog was receiving chemo-immunosuppressive treatment for T cell lymphoma. For this reason it is possible to suppose that emission of *Neospora* oocysts in this dog was caused by reactivation of a latent infection.

Keywords: *Neospora caninum*; dog; oocyst shedding; serology; PCR analysis; Italy.

INTRODUCTION

Neospora caninum (Apicomplexa: Sarcocystidae) is an intracellular protozoan parasite that can infect a wide range of animals, worldwide (Dubey et al., 2007; Mineo et al., 2011). Dog and some wild canid species are the recognised definitive hosts of *N. caninum* (Gondim et al., 2004; Dubey et al., 2011), while several animal species have been described as intermediate hosts (Dubey and Schares, 2011; Mineo et al., 2011; Darwich et al., 2012). Neosporosis is considered primarily a disease of cattle and responsible for great economic losses in cattle farms (Dubey et al., 2007), being one of the important agents that contribute to bovine abortions worldwide (Dubey and Schares, 2011). Infected dogs are frequently asymptomatic (Mitrea et al., 2013). However, neosporosis has been reported as a cause of canine neuromuscular disease (Dubey and Schares, 2011), pneumonia, myocarditis, hepatitis and dermatitis in dogs of all ages (Nazir et al., 2014). Although the seroprevalence of the infection in dogs can be relatively high, up to 36.4% in Europe (Robbe et al., 2016), the occurrence of natural *N. caninum* oocysts shedding has been reported to a lesser extent worldwide. Reported prevalence of dogs naturally shedding fecal oocysts varies between about 0.02-0.03% and 4.9% (Schares et al., 2005; Mitrea et al., 2013; Asmare et al., 2014). The number of oocysts shed by these dogs is usually low (Schares et al., 2005; Qian et al., 2016).

Materials and Methods

A mixed-breed male household dog aged about 8 years born and living in a rural environment of the district of Pisa (Tuscany, Central Italy), was referred for dysorexia, weakness and general lymph node enlargement. The dog was fed with pellets and canned foods. Clinical pathology evidenced mild normocytic and normochromic anemia, thrombocytopenia and hypoproteinemia with hypoalbuminemia. The blood serum of the dog was routinely checked by Immunofluorescent antibody test (IFAT) for antibodies against *Leishmania* spp., as reported elsewhere (Mancianti and Meciani, 1988) and for *Ehrlichia canis* and *Anaplasma phagocytophilum*, by using different

commercial agent-specific IFAT slides (Fuller Laboratories Fullerton, California, USA), following the manufacturer's instructions.

From lymph node and bone marrow analysis, T cell lymphoma, high grade, pleomorphic type, clinical stage V, was diagnosed. The dog was treated with a chemotherapy induction protocol with vincristine (0.75 mg/m² IV once a week), cyclophosphamide (50mg/m² orally 3–4 days/week), and prednisone (40mg/m² orally daily for the first week, then tapered to 5 mg/m² orally daily in the further weeks) for 8 weeks.

A faecal sample (4 g) collected 7 days after the beginning of the treatment was analysed by both flotation test and a McMaster method with a sensitivity of 50 EPG using a low density solution (saturated NaCl solution, sg 1.2) as reported by Riggio et al. (2013).

An aliquot (200 microliters) of the same faecal sample was extracted using the ZR fecal DNA miniprep (Zymoresearch, USA) and was analysed by PCR with species-specific primer pairs Np6+/Np21+ that amplify a 337 bp fragment of the Nc 5 region (Muller et al., 1996).

Serological examination was performed by IFAT on serum samples collected at the first visit and about a month later. Specific *N. caninum* antibodies were determined using 12-well slides (Fullerton Lab, Fullerton CA., USA). The serum samples were screened with a threshold dilution of 1:50 and positive dilutions were then end-titrated using 2-fold dilution (Bartova et al., 2007). Positive and negative reference sera were used.

Soon after the dog died for the exacerbation of this particularly aggressive lymphoma (T) that had become resistant to the treatment. The owner denied the consent to perform necropsy.

RESULTS

At coprological analysis, the examined faecal sample was found positive for 300 OPG of *N. caninum*-like unsporulated oocysts of 10-11 um in diameter. More precisely, in saturated NaCl

solution, the unsporulated oocysts (n. 10) measured 10.60 μm (± 0.51 μm , range 10-11 μm) in length and 10.50 μm (± 0.53 μm , range 10-11 μm) in width (Fig. 1).

PCR analysis confirmed the positivity of this same faecal sample for *N. caninum* DNA.

The serum sample collected about a month later scored positive for *N. caninum* with a titer of 1:400. In the light of these findings, the serum previously collected to determine antibodies against *Leishmania*, *E. canis* and *A. phagocytophilum* was checked for antibodies against *N. caninum*, and a titer of 1:50 was determined.

DISCUSSION

This study reports the first isolation of *N. caninum* oocysts from the faeces of a dog from Italy. Previous detections of *N. caninum* oocysts in naturally infected dogs have been reported in Germany (Schaes et al., 2005; Basso et al., 2009a), Portugal (Basso et al., 2009b), Argentina (Basso et al., 2001), United Kingdom (McGarry et al., 2003), Czech Republic (Slapeta et al., 2002), Australia (King et al., 2012), Ethiopia (Asmare et al., 2014) and China (Qian, 2016).

The dog investigated was receiving chemo-immunosuppressive treatment. In previous studies, immunosuppressive treatment has been shown to lead dogs to the parasite proliferation and overt clinical disease. A wide range of clinical signs have been reported in dogs on immunosuppressive therapy (Dubey and Schares, 2011). Indeed, some cases of cutaneous neosporosis in dogs treated with immunosuppressive therapy (Legnani et al., 2016) as well as fatal hepatitis associated with cyclosporine treatment (Fry et al., 2009) and fatal meningoencephalitis in a dog treated with prednisone and cyclosporine (Galgut et al., 2010), were reported. Naturally, occurring systemic illness as the primary, high grade T cell Lymphoma diagnosed in the case here reported, might have been a further immunosuppressive factor.

In the present case, the dog died after about one month from the first visit without showing specific clinical signs of neosporosis. IFAT indicated a specific humoral response and the dog was shedding *N. caninum* oocysts. Furthermore, the serum examined before the start of the therapy indicated a low antibody titer corroborating the hypothesis of a preexisting infection. The present results would seem not in agreement with data from literature and discussed by Cavalcante et al. (2011). The Authors report no seroconversion to *N. caninum* in dogs fed on different tissues from naturally infected cattle, although most of them shed oocysts, and refer the same findings as reported from several other Authors. On the other hand the case reported in this study was proven to be seropositive prior to chemo-immunosuppressive treatment, suggesting a possible resemblance with the strictly related parasitic protozoan *Toxoplasma gondii*. Cats chronically infected by *T. gondii* in fact are able to re-excrete oocysts after cortisonic treatments (Malmasi et al., 2009), so a similar outcome could be supposed in chronically *N. caninum* affected dogs.

This report indicates that *N. caninum* screening should always be considered in dogs suffering from immunosuppressive diseases or before the initiation of any long term immunosuppressive therapy.

Conflict of interest

None of the authors has any financial or personal relationships that could inappropriately influence or bias the content of the paper.

Funding

This research did not receive any specific grant from funding agencies in the public, commercial, or not-for-profit sectors.

Authorship

Stefania Perrucci conceived and designed the study. Stefania Perrucci, Alessandra Gavazza, Guido Rocchigiani, Simona Nardoni and Alina Zbriger contributed to the acquisition of data. Stefania Perrucci and Francesca Mancianti analysed and interpreted the results. Stefania Perrucci, George Lubas and Francesca Mancianti drafted the article. All authors revised it critically and approved the submitted final version of the manuscript.

ACCEPTED MANUSCRIPT

REFERENCES

- Asmare, K., Skjerve, E., Bekele, J., Sheferaw, D., Stachurska-Hagen, T., Robertson, L.J. 2014. Molecular identification of *Neospora caninum* from calf/foetal brain tissue and among oocysts recovered from faeces of naturally infected dogs in southern Ethiopia. *Acta Trop.* 130, 88–93.
- Bartova, E., Sedlak, K., Pavlik, I., Literak I. 2007. Prevalence of *Neospora caninum* and *Toxoplasma gondii* antibodies in wild ruminants from the countryside or captivity in the Czech Republic. *J. Parasitol.* 93, 1216– 1218.
- Basso, W., Venturini, L., Venturini, M.C., Hill, D.E., Kwok, O.C., Shen, S.K., Dubey, J.P. 2001. First isolation of *Neospora caninum* from the feces of a naturally infected dog. *J. Parasitol.* 87, 612–618.
- Basso, W., Schares, S., Bärwald, A., Herrmann, D.C., Conraths, F.J., Pantchev, N., Vrhovec, M.G., Schares, G. 2009a. Molecular comparison of *Neospora caninum* oocyst isolates from naturally infected dogs with cell culture-derived tachyzoites of the same isolates using nested polymerase chain reaction to amplify microsatellite markers. *Vet. Parasitol.* 160, 43–50.
- Basso, W., Herrmann, D.C., Conraths, F.J., Pantchev, N., Vrhovec, M.G., Schares, G. 2009b. First isolation of *Neospora caninum* from the faeces of a dog from Portugal. *Vet. Parasitol.* 159. 162–166
- Cavalcante GT, Monteiro RM, Soares RM, Nishi SM, Alves Neto AF, Esmerini Pde O, Sercundes MK, Martins J, Gennari SM. Shedding of *Neospora caninum* oocysts by dogs fed different tissues from naturally infected cattle *Vet Parasitol.* 2011 Jun 30;179(1-3):220-3.
- Darwich, L., Cabezón, O., Echeverria, I., Pabón, M., Marco, I., Molina-López, R., Alarcia-Alejos, O., López-Gatius, F., Lavín, S., Almería, S. 2012. Presence of *Toxoplasma gondii* and *Neospora caninum* DNA in the brain of wild birds. *Vet. Parasitol.* 183, 377-81.

- Dubey, J.P., Schares, G., Ortega-Mora, L.M. 2007. Epidemiology and control of neosporosis and *Neospora caninum*. Clin. Microbiol. Rev. 20, 323–367.
- Dubey, J.P., Schares, G. Neosporosis in animals- The last five years. 2011. Vet. Parasitol. 180, 90–108.
- Dubey, J.P., Jenkins, M.C., Rajendran, C., Miska, K., Ferreira, L.R., Martins, J., Kwok, O.C., Choudhary, S. 2011. Gray wolf (*Canis lupus*) is a natural definitive host for *Neospora caninum*. Vet. Parasitol. 181, 382-387.
- Fry, D.R., McSparran, K.D., Ellis, J.T., Harvey, C. 2009. Protozoal hepatitis associated with immunosuppressive therapy in a dog. J. Vet. Intern. Med. 23, 366–368.
- Galgut, B.I., Janardhan, K.S., Grondin, T.M., Harkin, K.R., Wight-Carter, M.T. 2010. Detection of *Neospora caninum* tachyzoites in cerebrospinal fluid of a dog following prednisone and cyclosporine therapy. Vet. Clin. Pathol., 39, 386–390.
- Gondim, L.F., McAllister, M.M., Pitt, W.C., Zemlicka, D.E. 2004. Coyotes (*Canis latrans*) are definitive hosts of *Neospora caninum*. Int. J. Parasitol. 34,159–161.
- King, J.S., Brown, G.K., Jenkins, D.J., Ellis, J.T., Fleming, P.J., Windsor, P.A., Slapeta, J. 2012. Oocysts and high seroprevalence of *Neospora caninum* in dogs living in remote Aboriginal communities and wild dogs in Australia. Vet. Parasitol. 187, 85–92.
- Legnani, S., Pantechev, N., Forlani, A., Zini, E., Schares, G., Balzer, J., Roccabianca, P., Ferri, F., Zanna, G. 2016. Emergence of cutaneous neosporosis in a dog receiving immunosuppressive therapy: molecular identification and management. Vet. Dermatol. 27, 49–e14. Doi: 10.1111/vde.12273.
- Malmasi, A., Mosallanejad, B., Mohebbali, M., Sharifian Fard, M., Taheri, M. 2009. Prevention of shedding and re-shedding of *Toxoplasma gondii* oocysts in experimentally infected cats treated with

oral Clindamycin: a preliminary study. *Zoonoses Public Health* 56,102-4. Doi:10.1111/j.1863-2378.2008.01174.x.

Mancianti, F., Meciani, N. 1988. Specific serodiagnosis of canine leishmaniasis by indirect immunofluorescence, indirect hemagglutination, and counterimmunoelectrophoresis. *Am J Vet Res.* 49, 1409-11.

McGarry, J.W., Stockton, C.M., Williams, D.J., Trees, A.J. Protracted shedding of oocysts of *Neospora caninum* by a naturally infected foxhound. 2003. *J. Parasitol.* 89, 628–630.

Mineo, T.W., Carrasco, A.O., Raso, T.F., Werther, K., Pinto, A.A., Machado, R.Z. 2011. Survey for natural *Neospora caninum* infection in wild and captive birds. *Vet. Parasitol.* 182, 352–355.

Mitrea, I.L., Enachescu, V., Ionita, M. 2013. *Neospora caninum* infection in dogs from Southern Romania: coproparasitological study and serological follow-up. *J. Parasitol.* 99, 365–367.

Müller, N., Zimmermann, V., Hentrich, B., Gottstein, B. 1996. Diagnosis of *Neospora caninum* and *Toxoplasma gondii* infection by PCR and DNA hybridization immunoassay. *J. Clin. Microbiol.* 34, 2850–2852.

Nazir, M.M., Maqbool, A., Akhtar, M., Ayaz, M., Ahmad, A.N., Ashraf, K., Ali, A., Alam, M.A., Ali, M.A., Khalid, A.R., Lindsay, D.S. 2014. *Neospora caninum* prevalence in dogs raised under different living conditions. *Vet. Parasitol.* 204, 364–368.

Qian, W., Wang, T., Yan, W., Han, L., Zhai, K., Duan, B., Lv, C. 2016. Occurrence and first multilocus microsatellite genotyping of *Neospora caninum* from naturally infected dogs in dairy farms in Henan, Central China. *Parasitol. Res.* 115, 3267–3273. DOI 10.1007/s00436-016-5142-y

Riggio, F., Mannella, R., Ariti, G., Perrucci, S., 2013. Intestinal and lung parasites in owned dogs and cats from central Italy. *Vet. Parasitol.* 193: 78-84.

Robbe, D., Passarelli, A., Gloria, A., Di Cesare, A., Capelli, G., Iorio, R., Traversa, D. 2016. *Neospora caninum* seropositivity and reproductive risk factors in dogs. *Exp. Parasitol.* 164, 31-35.

Schares, G., Pantchev, N., Barutzki, D., Heydorn, A.O., Bauer, C., Conraths, F.J. 2005. Oocysts of *Neospora caninum*, *Hammondia heydorni*, *Toxoplasma gondii* and *Hammondia hammondi* in faeces collected from dogs in Germany. *Int. J. Parasitol.* 35, 1525–1537.

Slapeta, J.R., Modrý, D., Kyselová, I., Horejs, R., Lukes, J., Koudela, B. 2002. Dog shedding oocysts of *Neospora caninum*: PCR diagnosis and molecular phylogenetic approach. *Vet. Parasitol.* 109, 157–167.

ACCEPTED MANUSCRIPT

Figure legend

Figure 1. *Neospora caninum* oocysts isolated from a mixed-breed male household dog of about 8 years in age born and living in the district of Pisa (Tuscany, Central Italy). a), b), d), x400; c), x250.

Scale bar 10 μ m.

ACCEPTED MANUSCRIPT

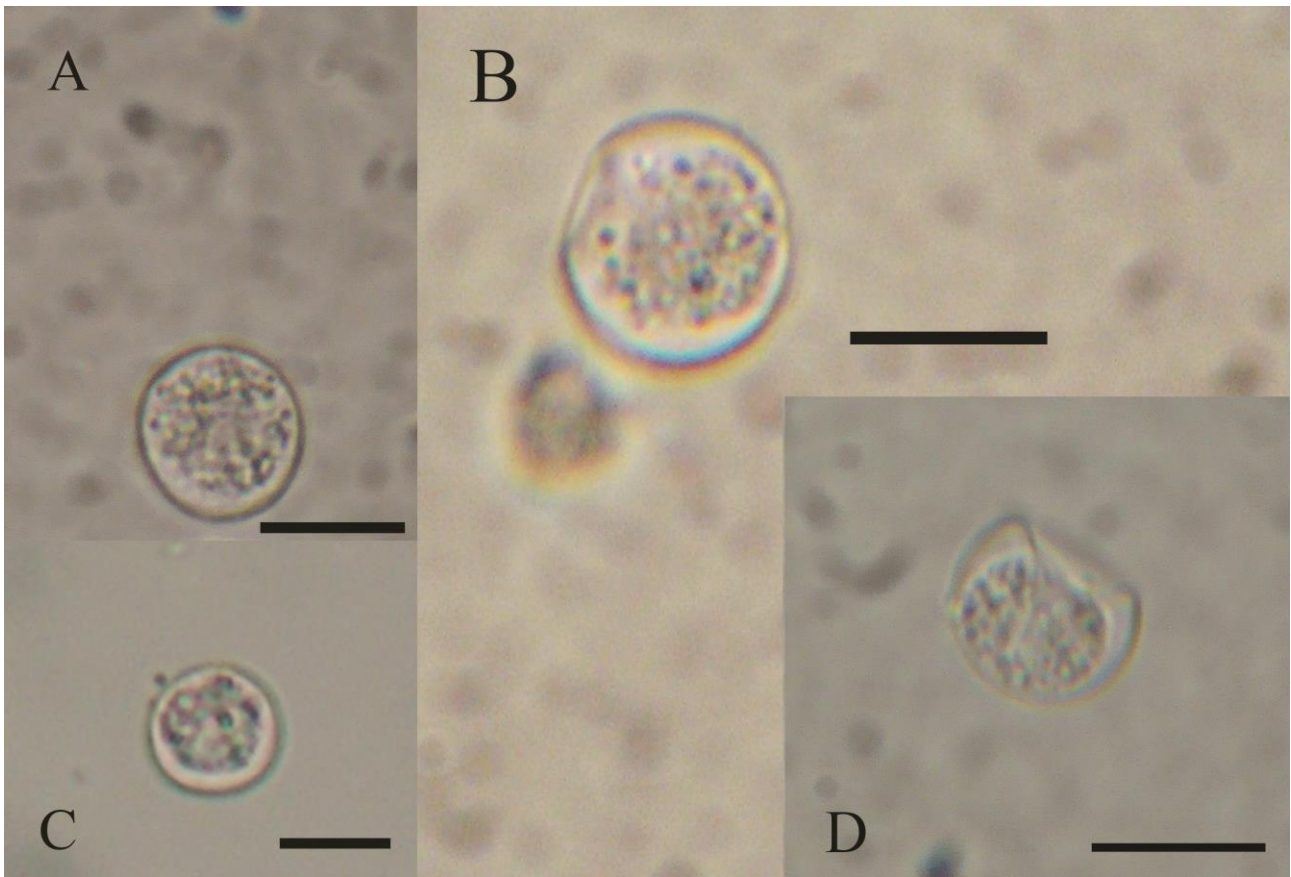


Fig. 1

ACCEPTED MANUSCRIPT

Highlights

1. A faecal sample from an Italian dog was found positive for *N. caninum*-like oocysts.
2. The dog was found positive for *N. caninum* at faecal PCR analysis and at serology.
3. This is the first isolation of *N. caninum* oocysts from the faeces of a dog from Italy.
4. The dog was diagnosed a high-grade T cell lymphoma and was treated with chemotherapy.
5. Results show the need of *N. caninum* screening in potentially immunosuppressed dogs.

ACCEPTED MANUSCRIPT