



Review

International therapeutic guidelines for patients with HCV-related extrahepatic disorders. A multidisciplinary expert statement[☆]



Anna Linda Zignego^{a,*}, Manuel Ramos-Casals^b, Clodoveo Ferri^c, David Saadoun^{n,o,p,q}, Luca Arcaini^d, Dario Roccatello^{e,f}, Alessandro Antonelli^g, Anne Claire Desbois^{n,o,p,q}, Cloe Comarmond^{n,o,p,q}, Laura Gragnani^a, Milvia Casato^h, Peter Lamprechtⁱ, Alessandra Mangia^j, Athanasios G Tzioufas^k, Zobair M Younossi^{l,m}, Patrice Cacoub^{n,o,p,q}, on behalf of the ISG-EHCV:

^a Interdepartmental Center for Systemic Manifestations of Hepatitis Viruses (MaSVE), Department of Experimental and Clinical Medicine, University of Florence, Florence, Italy

^b Department of Autoimmune Diseases, ICMIID Josep Font Autoimmune Lab, CELLEX-IDIBAPS, Hospital Clinic, Barcelona, Spain

^c Chair and Rheumatology Unit, Medical School, University of Modena and Reggio Emilia, Azienda Ospedaliero-Universitaria, Policlinico di Modena, 41124 Modena, Italy

^d Department of Molecular Medicine, University of Pavia, Pavia, Italy

^e Department of Hematology Oncology, Fondazione IRCCS Policlinico San Matteo, Pavia, Italy

^f Center of Research of Immunopathology and Rare Diseases, and Nephrology and Dialysis Unit, San G. Bosco Hospital and University of Turin, Italy

^g Department of Clinical and Experimental Medicine, University of Pisa, Via Savi 10, Pisa 56126, Italy

^h Department of Clinical Medicine, Sapienza University of Rome, Viale dell'Università 37, 00185 Rome, Italy

ⁱ Klinik für Rheumatologie Oberarzt, Ratzeburger Allee 160 (Haus 40), 23538 Lübeck, Germany

^j Liver Unit, IRCCS "Casa Sollievo della Sofferenza", San Giovanni Rotondo, Italy

^k Department of Pathophysiology, School of Medicine, University of Athens, 75 M. Asias st, Building 16, Room, 32 11527 Athens, Greece

^l Center for Liver Diseases, Department of Medicine, Inova Fairfax Hospital, Falls Church, VA, USA

^m Beatty Liver and Obesity Program, Betty and Guy Beatty Center for Integrated Research, Inova Health System, Falls Church, VA, USA

ⁿ Sorbonne University, UPMC Univ Paris 06, UMR 7211, and Inflammation-Immunopathology-Biotherapy Department (DHU i2B), Paris, France

^o INSERM, UMR S 959, Paris, France

^p CNRS, FRE3632, Paris, France

^q AP-HP, Groupe Hospitalier Pitié-Salpêtrière, Department of Internal Medicine and Clinical Immunology, Paris, France

ARTICLE INFO

Article history:

Received 19 February 2017

Accepted 26 February 2017

Available online 7 March 2017

Keywords:

Hepatitis C virus (HCV)

Extrahepatic manifestations of HCV

Anti-HCV therapy

Non-etiological therapy

ABSTRACT

Hepatitis C virus (HCV) is both hepatotropic and lymphotropic virus that causes liver as well extrahepatic manifestations including cryoglobulinemic vasculitis, the most frequent and studied condition, lymphoma, and neurologic, cardiovascular, endocrine-metabolic or renal diseases.

HCV-extrahepatic manifestations (HCV-EHMs) may severely affect the overall prognosis, while viral eradication significantly reduces non-liver related deaths.

Different clinical manifestations may coexist in the same patient. Due to the variety of HCV clinical manifestations, a multidisciplinary approach along with appropriate therapeutic strategies are required. In the era of interferon-free anti-HCV treatments, international recommendations for the therapeutic management of HCV-EHMs are needed. This implies the need to define the best criteria to use antivirals and/or other therapeutic approaches.

Abbreviations: HCV, hepatitis C virus; HCV-EHMs, HCV-extrahepatic manifestations; IFN, interferon; CV, cryoglobulinemic vasculitis; AVT, antiviral therapy; Peg-IFN, pegylated interferon; RBV, ribavirin; DAAs, direct-acting antiviral agents; FDA, food and drug administration; ISG-EHCV, International Study Group of Extrahepatic Manifestations Related to Hepatitis C Virus Infection; LPD, lymphoproliferative disease; CGs, Cryoglobulins; RF, rheumatoid factor; MC, mixed cryoglobulinemia; CNS, central nervous system; SVR, sustained virological response; NHL, non-Hodgkin lymphoma; CTX, cyclophosphamide; RTX, rituximab; NSAIDs, non-steroidal anti-inflammatory drugs; GN, Glomerulonephritis; MZL, marginal zone lymphoma; DLBCL, diffuse large B cell lymphoma; WM, Waldenström's macroglobulinemia; ESMO, European Society for Medical Oncology; NCCN, National Comprehensive Cancer Network; EASL, European Association for the Study of the Liver; R-CHOP, rituximab cyclophosphamide doxorubicin(hydroxydaunomycin) vincristine (oncovin) prednisone; CKD, chronic kidney disease; MPGN, membrano-proliferative glomerulonephritis; GBM, glomerular basement membrane; KDIGO, Kidney Disease Improving Global Outcomes; HRQOL, health-related quality of life; TNF, tumor necrosis factor; IL, interleukin; MRI, magnetic resonance imaging; SF-36, Short Form 36; PROs, patient-reported outcomes; PCT, porphyria cutanea tarda; URO-D, uroporphyrinogen decarboxylase; LP, lichen planus; HLA-DR, human leukocyte antigen - antigen D related; LFTs, liver function tests; T2DM, type 2 diabetes mellitus; AbTG, anti-thyroglobulin antibody; AbTPO, anti-thyroid peroxidase antibody; ATMA, anti-thyroid microsomal antibody; MMI, methimazole; TSH, thyroid-stimulating hormone; CXCL10, C-X-C motif ligand 10; L-T4, levo-thyroxine 4; IR, insulin resistance; HCC, hepatocellular carcinoma; NAFLD, non-alcoholic fatty liver disease; DM, diabetes mellitus; PPAR, peroxisome proliferator-activated receptor; RA, rheumatoid arthritis.

[☆] Funding: This research did not receive any specific grant from funding agencies in the public, commercial, or not-for-profit sectors.

* Corresponding author at: Interdepartmental Center for Systemic Manifestations of Hepatitis Viruses (MaSVE), Department of Experimental and Clinical Medicine, University of Florence, Azienda Ospedaliero-Universitaria Careggi, Largo Brambilla 3, 50134 Florence, Italy.

E-mail addresses: annalinda.zignego@unifi.it (A.L. Zignego), milvia.casato@uniroma1.it (M. Casato), peter.lamprecht@uksh.de (P. Lamprecht), a.mangia@tin.it (A. Mangia), agtzi@med.uoa.gr (A.G. Tzioufas).

The present recommendations, based on qualified expert experience and specific literature, will focus on etiological (antiviral) therapies and/or traditional pathogenetic treatments that still maintain their therapeutic utility.
 © 2017 The Authors. Published by Elsevier B.V. This is an open access article under the CC BY-NC-ND license (<http://creativecommons.org/licenses/by-nc-nd/4.0/>).

Contents

1.	Introduction	524
1.1.	Extrahepatic manifestations of HCV	524
1.2.	Anti-HCV therapy: old and new	524
2.	Methods	525
3.	Results: therapeutic approach to the single HCV-EHMs	525
3.1.	Cryoglobulinemic vasculitis (CV)	525
3.1.1.	Etiologic treatment	525
3.1.2.	Non-etiological treatment	528
3.2.	Lymphoma	530
3.2.1.	Etiologic treatment and its place with respect to non-viral treatment	530
3.3.	HCV-associated kidney diseases	531
3.3.1.	Etiologic treatment	531
3.3.2.	Non-etiological treatment	531
3.4.	Neuropsychiatric disorders and health-related quality of life (HRQOL)	532
3.4.1.	Neuropsychiatric disorders	532
3.4.2.	Health related quality of life (HRQoL)	532
3.4.3.	Etiologic treatment	532
3.5.	Porphyria cutanea tarda (PCT)	532
3.5.1.	Etiologic treatment	532
3.5.2.	Non-etiological treatment	532
3.6.	Lichen planus	532
3.6.1.	Etiologic treatment	533
3.6.2.	Non-etiological treatment	533
3.7.	HCV-associated endocrine disorders	533
3.7.1.	Thyroid disorders	533
3.7.2.	Type 2 diabetes mellitus	533
3.8.	Sicca syndrome/Sjögren's syndrome	534
3.8.1.	Etiologic treatment	534
3.8.2.	Non-etiological therapy	534
3.9.	Arthritis	534
3.9.1.	Etiologic treatment	534
3.9.2.	Non-etiological treatment	534
3.10.	Miscellanea	534
4.	Discussion	534
	Appendix A	535
	References	537

1. Introduction

1.1. Extrahepatic manifestations of HCV

HCV is a world-wide diffused linear, single-stranded RNA virus which displays both hepatotropism and lymphotropism and may cause hepatic and extrahepatic manifestations (HCV-EHMs). HCV-EHMs include many diseases with B-lymphoproliferative and/or autoimmune the most documented and frequent [1]. The recent availability of mortality rates in large cohorts of subjects confirmed the association of HCV infection with many extrahepatic pathological conditions including cardiovascular, neurologic, metabolic or renal diseases and extra-hepatic tumors [2–9]. The comparison between patients with persisting HCV infection and those who cleared the virus, showed that viral eradication significantly reduced the rate of extra-hepatic deaths [2,5,10,11].

HCV-EHMs can be classified according to the number and strength of supporting scientific data, as well as the underlying etio-pathogenic process [12].

The correct approach to patients with HCV-EHMs requires a multidisciplinary management. Specialists of different medical areas challenging with specific HCV-EHMs should take into account the pathogenetic role of HCV in different underlying pathological processes.

This arises the need to define the best criteria to use antivirals and/or other therapeutic approaches previously standardized for virus-unrelated disease variants with comparable pathogenetic process. International, multidisciplinary recommendations for the therapeutic management of HCV-EHMs in the era of Interferon (IFN)-free anti-HCV treatment are needed. Therefore, this paper will mainly focus on the effects of new (IFN-free) and old (IFN-based) anti-HCV treatments as well as non-viral therapies on the different HCV-EHMs.

Different manifestations, being caused by the same etiologic agent, often coexist in the same subject. Most of available information is derived from studies carried out in patients suffering from cryoglobulinemic vasculitis, CV, the prototype of systemic HCV-EHMs that will be considered for first. Then, the main organ-specific disorders (detectable or not in patients with CV) for which enough data are available will be better detailed, in order to give, for each condition, a picture based on different and complementary focuses and the most appropriate therapeutic approach.

1.2. Anti-HCV therapy: old and new

The introduction of the first, IFN-based, antiviral therapy (AVT), led to positive effects on several HCV EHMs, improving survival rates [13–

17]. However, this treatment, even in its most effective combination (Pegylated (Peg)-IFN plus ribavirin (RBV)), had limited efficacy. AVT options have been recently expanded with the introduction of direct-acting antiviral agents (DAAs), that directly target non-structural proteins with a key role in HCV replication.

In 2011, the US Food and Drug Administration (FDA) approved the first generation of HCV NS3 protease inhibitors - also known as “-previrs”. These molecules block the catalytic site of NS3, preventing the poly-protein cleavage and thus HCV replication. Currently approved “-previrs” include telaprevir and boceprevir (first wave), and simeprevir, paritaprevir and grazoprevir (second wave).

Two different classes of second wave DAAs have been introduced, the NS5A and the NS5B inhibitors. The NS5A inhibitors block the stage of membranous genesis; they are also known as “-asvirs” (daclatasvir, ledipasvir, ombitasvir, elbasvir, velpatasvir). The NS5B polymerase inhibitors or “-buvirs”, include nucleos(t)ide analogs (sofosbuvir) acting as chain terminators within the polymerase catalytic site, and non-nucleotide inhibitors (dasabuvir), causing conformational changes and making the polymerase ineffective. The first generation of DAAs needed the combination of Peg-IFN and RBV and prolonged treatments, while the currently available therapeutic schedules are based on different IFN-free (sometimes RBV free) DAA combinations, with shorter therapy duration (generally 12 to 24 weeks), minimal side-effects (Table 1) [18], and efficacy approaching 100% [18]. The correct choice of these regimens takes into account virus-related features (i.e., HCV genotype/subtype) and/or host-related features (i.e., presence/absence of severe liver disease, low creatinine clearance, drug-drug-interactions). These new drugs are providing the opportunity for a dramatic change in the anti-HCV therapeutic approach, eradicating HCV with high efficacy without IFN related side effects. Main international guidelines are in agreement on the opportunity to recommend AVT to all HCV infected patients without a short lifetime expectancy (i.e., <http://www.hcvguidelines.org/full-report-view>). However, universal treatment may not be scaled up in many countries for lack of financial resources and/or of health care infrastructure and indications to prioritization concerning some HCV-EHMs, essentially based on increased risk of mortality and morbidity have been defined (<http://www.easl.eu/research/our-contributions/clinical-practice-guidelines/detail/easl-recommendations-on-treatment-of-hepatitis-c-2016> and <http://www.who.int/hiv/pub/hepatitis/hepatitis-c-guidelines/en/>; Table 2).

Table 1
Main adverse event of second-wave DAAs

Protease inhibitors	
Simeprevir	-Photosensitivity -Contraindicated in cirrhosis (Child-Pugh B or C) -Hyperbilirubinaemia -Drug-drug interactions (due to ritonavir)
Paritaprevir (boosted with ritonavir)	-Contraindicated in cirrhosis (Child-Pugh B or C) -Hyperbilirubinaemia -Hypertransaminasemia
Grazoprevir	-Well tolerated
NS5A inhibitors	
Ledipasvir	-Well tolerated -Some drug-drug interactions (with acid suppressants)
Ombitasvir	-Well tolerated
Daclatasvir	-Well tolerated
Elbasvir	-Well tolerated
NS5B inhibitors	
Sofosbuvir	-Contraindicated in severe renal impairment (estimated GFR less than 30 ml/min) -Some drug-drug interactions (with amiodarone)
Dasabuvir	-Well tolerated

2. Methods

The production of therapeutic guidelines for HCV-EHMs was conceived and organized by the International Study Group of Extrahepatic Manifestations Related to Hepatitis C Virus Infection (ISG-EHCV), which is a multidisciplinary international network of recognized experts in this field. In order to provide an homogeneous therapeutic approach to patients with HCV-EHMs, the ISG-EHCV convenor and co-convenors invited other ISG-EHCV members on the basis of their well-known expertise in the field of each HCV-related manifestation. This task force initially gathered via e-mail and successively via teleconference meetings for the discussion of different issues. A systematic review of the literature specifically correlated to the different HCV-EHMs was done, representing the backbone of the paper [19].

3. Results: therapeutic approach to the single HCV-EHMs

The first, essential step for a correct therapeutic approach to HCV EHMs is represented by an accurate general assessment of patients and diagnosis of single HCV-EHMs, as previously described [19].

The therapeutic approach to the main HCV-EHMs are described in the following paragraphs by starting with the CV; since the majority of the studies are focused on patients with CV, this systemic disorder represents a precious model for the analysis of the effects of etiologic therapy on HCV EHMs.

3.1. Cryoglobulinemic vasculitis (CV)

CV is the most frequent and largely investigated HCV-EHM [1,12,20, 21]. A detailed and complete description of this complex disease, in its different aspects, will be the object of a dedicated paper by our study group (see Saadoun et al., manuscript in preparation). In the present paper, the essential aspects justifying the most opportune therapeutic approach will be considered.

CV is a both autoimmune and lymphoproliferative disease (LPD), clinically benign (although sometimes with a severe presentation), but possibly evolving into lymphoma [20,22–24]. The pathological substrate of CV is the HCV-driven B-cell lymphoproliferation and the consequent production of cryo- and non-cryoprecipitable immune complexes, in turn responsible for vasculitic manifestations. Mixed cryoglobulins (CGs) are immune complexes that reversibly precipitate when the temperature is lower than 37 °C [12,22,25,26] and that consist of Ig (usually IgM) with rheumatoid factor (RF) activity [mono- or oligoclonal in type II mixed cryoglobulinemia (MC), or polyclonal in type III MC] and polyclonal IgGs [27]. Most CV patients are HCV positive (70–90%) and conversely 40–60% of HCV infected patients produce CGs of whom 5–30% with symptomatic CV [12,22,25,26]. Since HCV infects about 170 million individuals worldwide, the number of patients at risk for developing CV is substantial. The syndrome is characterized by the typical clinical triad - purpura, weakness, and arthralgias, low complement C4 fraction serum level and various visceral organ involvement, including renal, neurological, cardiac or digestive disease. According to the vasculitis severity, patients may manifest mild/moderate disease (i.e., purpura, articular involvement, mild sensory neuropathy), severe disease (i.e., extensive/ulcerative skin disease, severe sensory-motor neuropathy, glomerulonephritis with impaired renal function, gastrointestinal involvement) or life-threatening conditions (i.e., rapidly progressive glomerulonephritis, CNS involvement, intestinal ischemia, alveolar hemorrhage).

3.1.1. Etiologic treatment

3.1.1.1. IFN-based AVT. After the first, pioneering studies using recombinant IFN α in 1993 [13,28–30], AVT followed the evolution of hepatitis C treatment with some differences (i.e., in the drug doses/duration, combination with non-viral therapies) (Table 3), essentially due to the

Table 2
Individual health criteria for prioritization in case of HCV extrahepatic manifestations

	EASL ^a	WHO ^b	AASLD/IDSA ^c
Metabolic syndrome	No specific indications	Prioritized	No specific indications
Cryoglobulinemia vasculitis	Prioritized	Prioritized	No specific indications
Lymphoproliferative disorders	Prioritized	Prioritized	No specific indications
Renal disease	Prioritized	Prioritized	No specific indications
Debilitating fatigue	Prioritized	Prioritized	No specific indications
Significant psychosocial morbidity	No specific indications	Prioritized	No specific indications

^a European Association for the Study of the Liver (EASL) Recommendations, 2016; <http://www.easl.eu/research/our-contributions/clinical-practice-guidelines/detail/easl-recommendations-on-treatment-of-hepatitis-c-2016>

^b WHO: World Health Organization: <http://www.who.int/hiv/pub/hepatitis/hepatitis-c-guidelines/en/>

^c AASLD/IDSA: American Association for the Study of Liver Disease (AASLD)/ Infectious Diseases Society of America (IDSA): No specific indications: "Treatment is recommended for all patients with chronic HCV infection, except those with short life expectancies that cannot be remediated by treating HCV, by transplantation, or by other directed therapy" <http://www.hcvguidelines.org/full-report-view>

possible side-effects of IFN and/or RBV therapy (i.e. IFN neurotoxicity and myelo-inhibitory action and RBV hemolytic effects). The main steps in IFN-based AVT were represented by IFN monotherapy, its combination with RBV, and the combination of pegylated-IFN (PegIFN) and RBV that represented the standard of care for about fifteen years. The virological and clinical results progressively improved, but not the type or rates of side-effects. Clinical remission was clearly correlated with virological response (sustained virological response (SVR): prolonged negative viremia), although with some discordant data [31–36], including the persistence of CV in rare patients with SVR. However, this rare situation was generally transient or related to severe sequela of CV or the presence of a B-cell NHL. Possible explanations included the evolution to a late stage when the B-cell proliferation became independent from

the etiologic agent, with persistence of the pathogenetic B-cell clone expansion and the evolution to overt lymphoma (see Fig. 1). Also, a too advanced tissue damage could affect a full functional restoration, for example for a severe sensory-motor peripheral neuropathy. Therefore, a prompt and early HCV eradication was reputed essential. The complexity of such autoimmune/lymphoproliferative disorder suggested a sufficiently long follow up after HCV eradication to evaluate its real effects on CV symptoms. In a prospective and controlled study including more than 400 HCV infected patients with/without CG and with/without CV, after a mean follow-up of 8 years, all CV symptoms persistently disappeared in 57% of SVR patients; some signs and/or symptoms persisted in the remaining patients, although improved. All virological non-responders were also clinical non-responders, despite of a

Table 3
Interferon-related treatment of cryoglobulinemic vasculitis

Refer. no.	Author	Year	No. patients	Treatment	CS	Treatment duration (months)	Virological response		Clinical response ^e	
							EOT	Sustained	EOT	Sustained
[2]	Ferri	1993	26	2 MIU IFN/d (1m) → 2 MIU IFN _{x3} /w (5m)	Yes	6	13%	n.a.	1	n.a.
[13]	Ferri	1993	15	2 MIU IFN/d (1m) → 2 MIU IFN _{x3} /w (4m)	Yes	5	8%	n.a.	93%	n.a.
[29]	Marcellin	1993	2	3 MIU IFN _{x3} /w	n.a.	6	0%	n.a.	50%	0%
[30]	Johnson	1993	4	1–10 MIU IFN	No	2–12	100%	75%	75%	n.a.
[235]	Zimmermann	1993	1	3 MIU IFN _{x3} /w	No	3	n.a.	n.a.	Worsening	n.a.
[236]	Bojic	1994	1	3 MIU IFN _{x2} /w (4w) → 3 MIU IFN _{x3} /w (2w)	No	6 w	n.a.	n.a.	Worsening	n.a.
[14]	Misiani	1994	27	1.5 MIU IFN _{x3} /w (1w) → 3 MIU IFN _{x3} /w (23w)	No	6	60%	0%	6/7	0%
[51]	Dammacco	1994	15	3 MIU IFN _{x3} /w	No	12	42%	17%	53%	13%
[237]	Johnson	1994	17	3 MIU IFN _{x3} /w	Yes	12	50%	14%	53%	18%
[237]	Johnson	1994	8	3 MIU IFN _{x3} /w	No	6–12	n.a.	n.a.	75%	n.a.
[238]	Mazzaro	1994	18 (5 NHL)	3 MIU IFN _{x3} /w	No	12	44%	22%	28% complete 50% partial	Clinical resp CGs pos
[239]	Gilli	1996	1	3 MIU hIFN- α x3/w	No	10	1 (100%)	1 (100%)	1 (100%)	1 (100%)
[240]	Harle	1995	1	3 MIU IFN _{x3} /w	No	2 w (5 injections)	n.a.	n.a.	Worsening	n.a.
[241]	Mazzaro	1995	18	3 MIU IFN _{x3} /w	No	6	44%	11%	28%	11%
[241]	Mazzaro	1995	18 (8 NHL)	3 MIU IFN _{x3} /w	No	12	50%	22%	39%	22%
[242]	Migliaresi	1995	18	3 MIU IFN _{x3} /w	No	12	n.a.	n.a.	72%	28%
[243]	Yamabe	1996	1	10 MIU IFN/d (2 w) → 10 MIU IFN _{x3} /w (6 w)	No	2	1 (100%)	1 (100%)	Clinical resp CGs pos	Clinical resp CGs pos
[244]	Casari	1996	36	6 MIU IFN _{x3} /w	No	6	n.a.	n.a.	31%	19%
[245]	Cohen	1996	16	3 MIU IFN _{x3} /w	Variable	6	n.a.	n.a.	56%	0%
[15]	Adinolfi	1997	50	3 MIU IFN _{x3} /w	No	12	n.a.	n.a.	44%	12%
[246]	Sarac	1997	1	3 MIU IFN _{x3} /w (6 m) → 10 MIU IFN/d (2 w) → 10 MIU IFN _{x3} /w (6 w)	No	8	1 (100%)	1 (100%)	1 (100%)	CGs pos
[247]	Zuber	1997	2	Pt. 1: 3 MIU IFN _{x3} /w Pt. 2: 3 MIU IFN _{x3} /w (3 m) → 6 MIU IFN _{x3} /w (7 m) → 3 MIU IFN _{x2} /w	No No	2.5 n.a.	1 (100%) 0%	n.a. n.a.	1 (100%) (reduced cryocrit)	0% n.a.
[248]	Akriviadis	1997	20	3–5 MIU IFN _{x3} /w	No	6–12	n.a.	n.a.	65%	20%
[249]	Casato	1997	31	3 MIU IFN/d (3m) → 3 MIU IFN _{x3} /w	No	>12	n.a.	11/23	55%	29%

Table 3 (continued)

Refer. no.	Author	Year	No. patients	Treatment	CS	Treatment duration (months)	Virological response		Clinical response ^c	
							EOT	Sustained	EOT	Sustained
[250]	Mazzaro	1997	42 (7 NHL)	(>9m) 3 MIU IFN α 3/w	No	12	n.a.	(48%) 14%	31%	14%
[251]	Donada	1998	13 Rel 4 NR	6 MIU IFN α 3/w (3 m) \rightarrow 3 MIU IFN α 3/w (3 m) + RBV (6 m)	No	6	85% 0%	38% 0%	n.a. ^a	38.5%
[252]	Durand	1998	5 NR	RBV	No	10–36	0%	0%	4 improvement 1 stabilization	n.a.
[253]	Gordon	1998	1	1.5 MIU IFN α 3/w	Yes	1 w (2 injections)	n.a.	n.a.	Worsening	n.a.
[254]	Scelsa	1998	2	Pt 1: 3 MIU IFN α 3/w (1 m) \rightarrow prednisone \rightarrow 1 MIU IFN α 3/w Pt 2: 3 MIU IFN α 3/w 3 MIU IFN α 3/w	Yes Yes	6 3 injections	n.a.	n.a.	Worsening of polyneuropathy	n.a.
[255]	Calleja	1999	18 8 NR 5 Rel	3 MIU IFN α 3/w + RBV (retreatment) 3 MIU IFN α 3/w + RBV (retreatment)	No No	12 12	55% 62%	27% 37.5%	55% 62%	27% 37.5%
[256]	Cid	1999	3	3 MIU IFN α 3/w	Yes	2–4	n.a.	n.a.	Worsening of ischemic lesions	n.a.
[257]	Cresta	1999	43	3 MIU IFN α 3/w	No	6	42%	14%	40%	14%
[258]	Friedman	1999	1	3 MIU IFN α 3/w	No	3 w	n.a.	n.a.	Exitus	n.a.
[259]	Misiani	1999	1	3 MIU IFN α 3/w + RBV (4 m)	No	16	100%	100%	100%	100%
[50]	Mazzaro	2000	7 (2 NHL)	3 MIU IFN α 3/w	No	6	29%	14%	14%	14%
[225]	Zuckerman	2000	9	3 MIU IFN α 3/w + RBV	No	6	22%	22%	78%	56%
[260]	Garini	2001	2	Pt. 1: 3 MIU IFN α 3/w + RBV Pt. 2: 3 MIU IFN α 3/w + RBV	No	6 12	1 (100%) 1 (100%)	1 (100%) n.a.	1 (100%) CGs pos	1 (100%) n.a.
[261]	Naarendorp	2001	10	3 MIU IFN α 3/w 3 MIU IFN α 3/w	No	3–60	n.a.	n.a.	n.a. ^b	n.a. ^b
[262]	Beddhu	2002	10	4 pts.NR retreated with: 10 MIU/d (2 w) \rightarrow 10 MIU α 3/w (6 w)	No	12 2	n.a. n.a.	10% 25%	10% 50%	10% 50%
[35]	Cacoub	2002	14	Variable IFN + RBV	Variable	6–56	n.a.	64%	n.a.	10/14
[263]	Casato	2002	1	3 MIU IFN/d \rightarrow 3 MIU IFN α 3/w \rightarrow 3 MIU IFN/d	No	18	0%	0%	Remission	n.a.
[264]	Loustaud-Ratti	2002	2	Pt. 1: 3 MIU IFN α 3/w 3 MIU IFN α 3/w + RBV (retreatment) Pt. 2: 3 MIU IFN α 3/w \rightarrow plus RBV	No No Yes	12 12 12	1 (100%) 1 (100%) 1 (100%)	0% 1 (100%) 1 (100%)	1 (100%) 1 (100%) 1 (100%)	0% 1 (100%) 1 (100%)
[265]	Sikaneta	2002	1 OLT	2 MIU IFN α 2/w + RBV \rightarrow Peg-IFN + RBV	Yes	10	n.a. (neg in treatment)	-	n.a. (neg in treatment)	n.a.
[266]	Bruchfeld	2003	2	Pt. 1: 3 MIU IFN α 3/w + RBV Pt. 2: Peg-IFN + RBV	Yes No	6 6	1 (100%) 1 (100%)	0% 1 (100%)	1 (100%) 1 (100%)	vasculitis flare 1 (100%)
[36]	Mazzaro	2003	27 (3NHL) NR or Rel.	3 MIU α 3/w + RBV	No	12	5/24 (21%)	5/24 (21%)	15 immunol. resp 19 clinical resp (transient)	5/24 (21%)
[267]	Rossi	2003	3	RBV (4 w) \rightarrow 3 MIU IFN α 3/w + RBV	No	13	3 (100%)	3 (100%)	3 (100%)	3 (100%)
[268]	Alric	2004	18	3 MIU α 3/w + RBV (n = 14) or Peg-IFN + RBV (n = 4)	Variable	6–24	72%	66.6%	n.a.	n.a.
[269]	Batisse	2004	1	Peg-IFN	No	1	0%	0%	worsening	n.a.
[270]	Cacoub	2005	9	Peg-IFN 1.5 μ g/kg/w + RBV	Variable	10–26	89%	78%	100%	88% ^d –56% ^e
[271]	Levine	2005	4	Pt. 1: Peg-IFN + RBV Pt. 2: IFN Pt. 3: Peg-IFN + RBV Pt. 4: IFN α 3/w + RBV	No No No No	6 18 12 12	1 (100%) 1 (100%) 1 (100%) 1 (100%)	1 (100%) 1 (100%) 1 (100%) 1 (100%)	CGs increase CGs increase CGs pos	n.a.
[272]	Mazzaro	2005	18	Peg-IFN 1 μ g/kg/w + RBV	No	12	83%	44%	89% complete 11% partial	44%
[273]	Vigani	2005	1	3 MIU IFN α 3/w + RBV	No	48	1 (100%)	1 (100%)	MCS resp CGs pos	n.a.
[274]	Saadoun	2006	72 (9 NHL)	3 MIU IFN α 3/w + RBV (32 pts) Peg-IFN + RBV (40 pts) Pt. 1: 3 MIU IFN α 3/w + RBV Pt. 2: 3 MIU IFN α 3/w + RBV Pt. 3: Peg-IFN + RBV Pt. 4: Peg-IFN + RBV	Variable No No No No	\geq 6 6 12 12 12	63% 75% 1 (100%) 1 (100%) 1 (100%) 0%	53% 63% 1 (100%) n.a. 1 (100%) -	47% ^d –28% ^e 73% ^d –60% ^e 1 (100%) CGs pos Partial resp CGs pos	56% ^d –31% ^e 68% ^d –58% ^e 1 (100%) n.a. Rel n.a.
[34]	Garini	2007	4	Pt. 1: Peg-IFN + RBV Pt. 2: Peg-IFN + RBV Pt. 3: Peg-IFN + RBV Pt. 4: Peg-IFN + RBV	Prior No No No	12 12 12 12	1 (100%) 1 (100%) 1 (100%) 0%	1 (100%) 1 (100%) 1 (100%) -	1 (100%) 1 (100%) 1 (100%) Partial resp	1 (100%) 1 (100%) 1 (100%) Rel
[33]	Montalbano	2007	1	Peg-IFN + RBV	No	12	1 (100%)	1 (100%)	CGs pos	n.a.
[275]	Parise	2007	31	3 MIU IFN α 3/w + RBV - IFN (8) - Peg-IFN (5) - Consensus IFN (2) - IFN + RBV (18) - Peg-IFN + RBV (14)	n.a.	6–12	n.a.	29% 25% 0% 17% 71%	32% 0% n.a.	n.a. 62.5% 40% 50% 71%

(continued on next page)

Table 3 (continued)

Refer. no.	Author	Year	No. patients	Treatment	CS	Treatment duration (months)	Virological response		Clinical response ^e	
							EOT	Sustained	EOT	Sustained
[276]	Koziolek	2007	1	(Peg-IFN + RBV → Peg-IFN) + cryoprecipitate apheresis	Yes	>6	1 (100%)	n.a.	1 (100%)	n.a.
[277]	Trebst	2007	1	Peg-IFN + RBV (14 m) → Peg-IFN (4 m)	No	18	0%	n.a.	100%	n.a.
[278]	De Blasi	2008	1	Peg-IFN + amantadine	No	4	1 (100%)	1 (100%)	CGs increase MCS symptoms	n.a.
[279]	Landau	2008	49 (9 NHL)	Peg-IFN + RBV	n.a.	>6	n.a.	59.2%	n.a.	69.4%
[32]	Landau	2008	8 (3 NHL)	IFN + RBV or Peg-IFN + RBV	n.a.	12–25	n.a.	100%	100%	0%
[16]	Mazzaro	2011	86	Peg-IFN + RBV	n.a.	6–12	72%	50%	n.a.	88.5%
[280]	Donato	2013	1 OLT	Peg-IFN + RBV (8 m) → IFN + RBV (4 m)	Yes	12	1 (100%)	1 (100%)	1 (100%)	1 (100%)
[281]	Saadoun	2014	23	Peg-IFN + RBV + BOC (8) Peg-IFN + RBV + TPV (15)	Variable	12	69.6%	n.a.	56.5%	n.a.
[282]	De Nicola	2014	1	Peg-IFN + RBV + TPV	n.a.	12	1 (100%)	1 (100%)	1 (100%)	1 (100%)
[39]	Gragnani	2014	22	Peg-IFN + RBV + BOC	No	12	n.a.	23.8%	n.a.	0%
[40]	Stine	2014	3	Peg-IFN + RBV + SOF	n.a.	3	100%	n.a.	n.a.	n.a.
[61]	Urraro	2015	1	RTX → Peg-IFN + RBV + BOC	No	10	1 (100%)	1 (100%)	n.a.	1 (100%)
[38]	Saadoun	2015	30	Peg-IFN + RBV + BOC (13) Peg-IFN + RBV + TPV (17)	Variable	12	n.a.	20 (66.7%)	n.a.	66.7% ^d –33.3% ^f
[17]	Gragnani	2015	121	Peg-IFN + RBV Pt. 1: Peg-IFN + RBV + BOC Pt. 2: RTX → Peg-IFN + RBV + TPV → Peg-IFN + RBV + SOF Pt. 3: Peg-IFN + RBV + TPV Pt. 4: RTX → Peg-IFN → Peg-IFN + RBV → Peg-IFN + RBV + SOF Pt. 5: RTX → Peg-IFN + RBV + SOF → RTX (maintenance regimen for low grade lymphoma)	No	6–12	n.a.	52%	n.a.	50.4% ^d
[41]	Cornella	2015	5		No	7	1 (100%)	1 (100%)	Partial response	Partial response
					No	1 → 3 → 15 weeks	1 (100%)	1 (100%)	Clearance of CGs	Clinical NR
					No	11	1 (100%)	1 (100%)	NR	NR
					Yes	n.a.	1 (100%)	1 (100%)	NR	NR
					No	3	1 (100%)	1 (100%)	CGs clearance	CGs clearance

IFN: interferon; Peg-IFN: pegylated-interferon; RBV: ribavirin; BOC: boceprevir; TPV: telaprevir; SOF: sofosbuvir; MIU: millions of international units; d: day; m: months; w: weeks; n.a.: not available; pt: patient; CS: corticosteroids; EOT: end of treatment; NR: non responder/s; Rel: relapser/s; CGs: cryoglobulins; MCS: Mixed Cryoglobulinemia Syndrome; NHL: Non-Hodgkin's Lymphoma; immunol: immunological; resp: response; pos: positive; neg: negative.

^a Significant reduction of cryocrit values (transient in relapsers and persistent in sustained virological responders).

^b Coincidence between sustained virological and clinical response.

^c The clinical response was variably classified in different studies: data are only partially comparable.

^d Complete clinical response.

^e Complete immunological response.

^f Partial clinical response.

transient improvement in some cases. Furthermore, the CG was a negative prognostic factor of virological response [17]. In consideration of all available data, the IFN-based AVT was recommended as the first-line option in mild to moderate CV [37].

The introduction of first-generation DAAs that were associated to Peg-IFN and RBV increased SVR rates, but also the side-effects. Saadoun et al described their safety and efficacy in 30 CV patients [38], where 67% of patients were complete clinical and virological responders while severe side effects occurred in 47%. Another study confirmed the good efficacy of such combination in 22 cryoglobulinemic subjects, with a CG disappearance in 86% but a lower SVR rate in cryoglobulinemic patients than in patients without mixed cryoglobulinemia (23.8% vs 70%, $p = 0.01$) [39]. Stine et al. in small case series of CV patients treated with triple AVT (Peg-IFN plus RBV plus sofosbuvir or first generation DAAs) suggested a longer treatment for cirrhotic patients, apparently more refractory to clear CGs [40,41].

3.1.1.2. Interferon-free AVT (Table 4). Limited, but essentially concordant data, are available regarding patients with CV. The first study reported the effects of a sofosbuvir/RBV combination for 24 weeks in 24 CV patients [42]; SVR was scored in 74% patients, with high rate of clinical response (87%) and low rates of serious adverse events [42]. The rate of SVR was that expected from used AVT protocols. Sise et al., using sofosbuvir-based combinations in 12 CV subjects, obtained an

improvement in renal function with or without immunosuppressant and SVR12 in 83% [43]. An interim analysis, mostly based on the combination of paritaprevir/ritonavir, ombitasvir, plus dasabuvir, showed a cryocrit decrease and a clinical response even during treatment [44]. The clinical improvement rate gradually increased from the inhibition of viral replication, end of treatment and SVR12 [45]. A very recent prospective study assessed efficacy and safety of sofosbuvir-based individually tailored therapy, in a cohort of 44 consecutive CV patients (median after treatment follow-up: 42 weeks, range 27–53) [46]. All patients obtained viral eradication and an overall 100% rate of clinical (complete or partial) response at week 24 post-treatment. Interestingly, a progressive increase of complete response rate over time, confirmed previous, preliminary observations. This is also suggested by another recent study conducted on 64 patients with circulating CGs (35/64 with CV) mostly treated in IFN-free regimens [47]. Recently, Hegazy et al. described a cohort of Egyptian and Italian CV subjects [48] and Kondili et al. reported results of a nationwide Italian study, showing the disappearance or improvement of more than 50% of CV symptoms in 31/37 (84%) patients after DAA [49]. Available data suggest that IFN-free AVT is safe, generally well tolerated and effective in CV patients.

3.1.2. Non-etiological treatment

The non-etiological therapy of CV remains useful for severe patients before and during AVT, and sometimes after AVT for patients with

persistent symptoms. However, it is not recommended as maintenance therapy after complete symptom remission, even when cryocrit, abnormal RF and/or complement levels are still altered.

This approach is usually based on anti-inflammatory drugs [i.e., glucocorticosteroids (GCs)], immune-suppressants [i.e., cyclophosphamide (CTX)], azathioprine, biological drugs [rituximab (RTX)], and analgesics, including non-steroidal anti-inflammatory drugs (NSAIDs). Furthermore, low-antigenic diet and apheresis can be helpful to decrease serum CGs levels, particularly in case of renal involvement.

These measures should be used considering the potential effects on viral replication and liver damage; the administration during DAA therapy, requires a mandatory evaluation of the drug-drug interactions.

GCs are commonly used to control inflammation and pain [50–55]. Low-medium doses of GCs (0.1–0.5 mg/kg/day) usually control mild to moderate symptoms, whereas high-dose pulse therapy (1–10 mg/kg) is commonly indicated to manage severe and acute conditions, specifically renal failure, neurologic manifestations or hyperviscosity syndrome [37,50,51,56]. The risk of multiple side-effects should be considered in case of GCs long-term administration [51–53,57]. In particular, in case of severe liver damage, the effects on viral replication, electrolyte balance (ascitic decompensation) and lipid metabolism (liver steatosis), have to be evaluated. The prolonged treatment with GCs, although common in clinical practice, has preferably to be avoided or at least reduced. *Colchicine* has been used as steroid-sparing agent to reduce Ig secretion [58,59]. It could have favorable transient effects on purpura, weakness, and leg ulcers when administered at dose of 1 mg/day for 6–48 months. The use is limited by the risk of gastrointestinal side-effects [58]. The *low-antigen-content diet* was reputed to

restore phagocyte activity and modify the composition of circulating immune-complexes. In mild to moderate CV, this diet was shown to reduce symptoms and laboratory signs [37,60]. Although it is still matter of debate, its use has been proposed as a supportive treatment for all symptomatic patients [55]. *Analgesic drugs* and *NSAIDs* are used to obtain a relief and reduce the GCs administration, especially in patients with peripheral neuropathy. Acetaminophen, gabapentin or pregabalin, opioids, and amitriptyline are the most used. The analgesics and NSAIDs administration is tailored on specific CV symptoms and on liver disease degree (especially for NSAIDs and benzodiazepines).

Other approaches have been shown to be very effective in severe CV; among them, Rituximab (monoclonal antibody against the B-cell specific CD20 antigen) has a prominent role [41,61]. RTX binding to CD20 causes a B-lymphocytes depletion thus justifying the extensive use in B-lymphoproliferative disorders and severe autoimmune diseases. The safety and efficacy of RTX monotherapy in CV were clearly shown [62–81]. RTX is especially recommended in case of HCV related CV with severe clinical manifestations, preferring it to more conventional treatments. RTX can improve various manifestations of CV, including skin symptoms (purpura and ulcers) [62,63,65], fatigue, arthralgias/arthritis, glomerulonephritis (GN) and, peripheral neuropathy in a relevant number of cases (75–90%) [62,63,65–67,75], including some life-threatening complications such as hyper-viscosity syndrome [37,62–81] or gastrointestinal vasculitis [69–71]. It has been reported that RTX is able to restore some CV-related immune abnormalities; it can decrease cryocrit, improve RF and C4 levels [82], and induce the disappearance of bone marrow B cell clonal expansion. Furthermore, RTX has a steroid-sparing effect [62,66,83]. Most studies used the standard

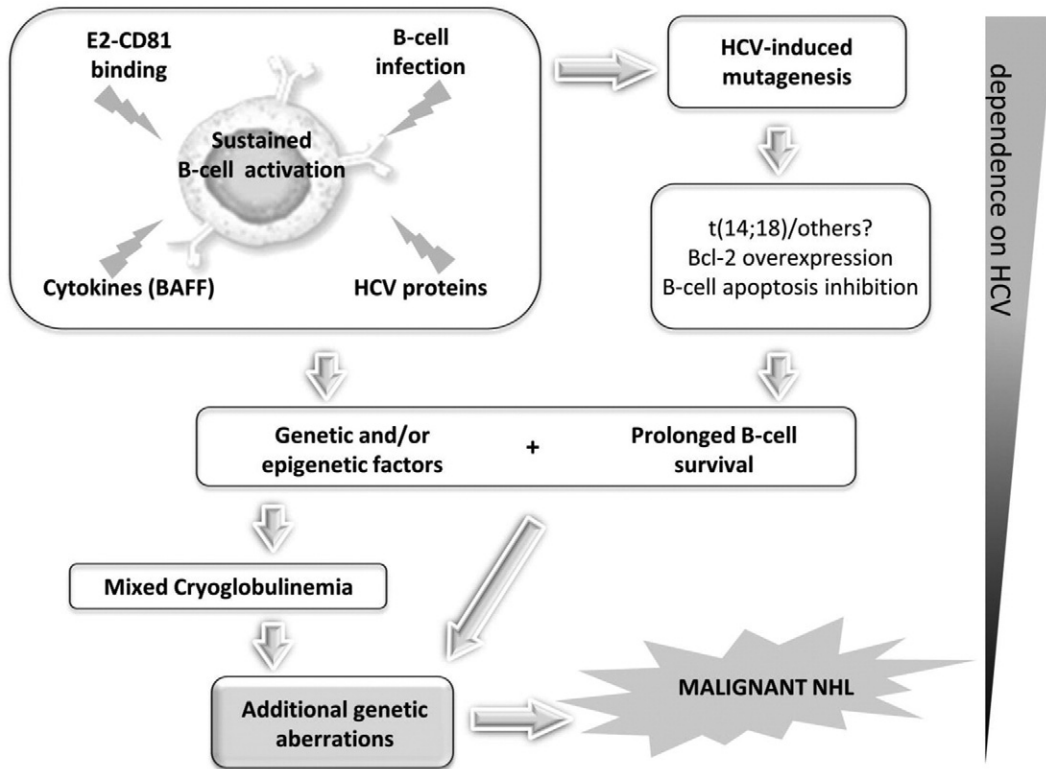


Fig. 1. Hypothetical pathogenetic process of lymphoproliferative disorders. During HCV chronic infection HCV-related LPDs arise from a cascade of mechanisms and events that progressively lead such lymphoproliferation to lose the dependence from the etiologic viral agent (no-return points). The prolonged and abnormal B-cell stimulation is sustained by different factors: the HCV ability to infect these cells; the E2-CD81 binding, that lowers the activation threshold of lymphocytes; a direct action of HCV proteins; the effect of several cytokines, first of all the B-cell Activating Factor (BAFF). The apoptosis inhibition and the consequent prolonged B-cell survival, could be caused by different events, particularly the t(14;18) translocation leading to overexpression of the anti-apoptotic protein Bcl-2 together with other genetic mutations. It is conceivable that all these mechanisms work on a particular host genetic pattern, preparing a favorable background for the onset of HCV-related LPDs. A contribution of epigenetic modifications could also take part to this complex pathogenesis. The addition of other unknown genetic aberrations, would lead to a frank malignancy that can progressively become independent from the viral etiologic agent. LPDs: lymphoproliferative disorders; E2: HCV E2 protein; BAFF: B-cell Activating Factor; t(14;18): chromosomal translocation (14;18) or Bcl2 gene rearrangement; Bcl-2 (B-cell lymphoma 2) gene and protein; NHL: non-Hodgkin's lymphoma.

Table 4
Interferon-free treatment of cryoglobulinemic vasculitis

Refer. no.	Author	Year	No. patients	Treatment	CS	Treatment duration (months)	Virological response		Clinical response ^a	
							EOT	Sustained	EOT	Sustained
[283]	Sultanik	2015	1	SOF + RBV until week 4 then SOF + DAC	No	3	1 (100%)	1 (100%)	n.a.	n.a.
[42]	Saadoun	2015	24	SOF + RBV	No	6	91.7%	74%	87.5% complete 12.5% partial	86.9% 33.3% complete 33.3% partial
[43]	Sise	2016	12	4 SOF + RBV, 8 SOF + SIM	No	3–6	100%	83%	n.a.	n.a.
[284]	Flemming	2016	1	SOF + LEDIPASVIR + RBV • Ombitasvir/paritaprevir/ritonavir + dasabuvir	No	3	100%	100%	n.a.	n.a.
[285]	Sollima	2016	7	• SOF + RBV • SOF + DCL • SOF + SIM	No	3–6	100%	100%	n.a.	14.3%
[46]	Gragnani	2016	44	• 18 SOF + RBV • 12 SOF + SIM (6 + RBV) • 4 SOF + DCL (1 + RBV) • 10 SOF + LED (3 + RBV)	No	3–6	100%	100%	25% full complete 34% complete 25% partial 16% non responder	35% full complete 41% complete 24% partial
[47]	Bonacci	2016	30	• 10 Ombitasvir/paritaprevir/ritonavir + dasabuvir • 10 SOF + LED • 2 SOF + SIM • 3 SIM + DCL • 2 SOF + DCL • 3 other	n.a. ^b	3–6	n.a. ^b	n.a. ^b	n.a. ^b	66.6% complete 16.7% partial

n.a.: not available

^a The clinical response was variably classified in different studies: data are only partially comparable.

^b It is not possible to complete this field since the analysis reported in the paper includes IFN-based treated patients.

hematological treatment schedule (375 mg/m² in four consecutive weekly infusions). Lower doses and/or shorter treatment have been also reported, i.e., 1g every two weeks for two infusions or 250 mg/m² in two administrations [81].

Since RTX is not active on B-cell progenitors, the effect is transitory with variable duration of the clinical effect (from 3–4 months to more than 12 months); long-term responses usually prevail. Before IFN-free AVTs, repeated treatments [62,65,66,69] and maintenance regimens were necessary, especially in patients with nephritis or severe abdominal vasculitis [66,68,69], because RTX has only a transitory effect and the viral trigger (HCV) was still present. The relationship between etiologic treatment and RTX is of interest. In the IFN era, most studies on RTX have been performed on patients who had failed or were not eligible for AVT, even if some authors suggested a combined RTX plus AVT in patients with severe manifestations (generally using RTX before AVT) [32, 66,84]. The effect of RTX treatment made eligible to IFN-based AVT some previously excluded patients [78]. In two controlled clinical trials, the combination of RTX with AVT showed a synergistic effect [70,82,84], being more effective in CV manifestations than AVT alone, particularly when a kidney involvement was present [85,86]. The AVT after RTX compared with RTX alone increased the relapse-free survival [87,88]. In most studies the combination was sequential, starting with RTX or AVT depending on the condition of the patient while, in some others, both therapies were administered concomitantly.

Data about combined RTX plus DAA-based therapy are still scarce [41,61]. However, it is conceivable to figure out promising successes of combination with IFN-free schedules. The exact place of RTX in the field of CV has to be more precisely defined. With the approval of recent DAAs IFN-free combination, which proved very highly and rapidly effective on viremia, we will have to define in the next future the remaining place of RTX. For example, as a first-line option for severe and life-threatening conditions needing urgent intervention and a second-line option for those maintaining significant symptoms after SVR.

3.2. Lymphoma

In 1994, a high prevalence of HCV infection in Italian patients with lymphoma was first reported in limited cohort of patients [89,90]. In the last two decades, several evidence proved the association between HCV infection and the occurrence of hematologic malignancies, mostly B-cell non-Hodgkin's lymphoma (B-NHL) [91,92]. A clear gradient of HCV-related lymphoma from North to South was also shown as for HCV infection [1,93]. Dedicated meta-analyses were able to confirm (although with different degrees), an increased risk of lymphoma in HCV infected subjects [92,94–97]. A confirmation derived also from the highly significant reduction in the lymphoma risk found as a result of sustained viral eradication [10,17]. This also suggested that AVT could represent a preventive measure for the development of lymphoma.

The association did not involve a specific histopathological type of B-NHL, although some of them appear more frequently related to HCV infection. HCV was initially linked to indolent NHL, then the association with aggressive subtypes was also shown. Marginal Zone (MZL), Diffuse Large B Cell (DLBCL) and Lymphoplasmacytic lymphomas (Waldenstrom's macroglobulinemia, WM) were the most frequent reported B-NHL in HCV infected patients [92,98,99].

3.2.1. Etiologic treatment and its place with respect to non-viral treatment

Since the first report in 2002 by Hermine et al. in HCV-positive splenic lymphoma with villous lymphocytes [100], a large series of evidence demonstrated that IFN-based AVT is able to induce hematological response along with virological clearance in patients with HCV-associated low grade lymphomas (especially MZL) [101]. A recent meta-analysis on 20 studies evaluated the efficacy of an IFN-based AVT in 254 patients with HCV-associated B-NHL [24]. Lymphoma response rate was 73% in all patients and up to 83% in SVRs. A better lymphoma response was shown in marginal zone compared to non-marginal zone

lymphoma (81% vs. 71%). Recent data with IFN-free regimens in HCV-associated LPDs suggest their anti-lymphoma activity too [102].

On this basis, AVT should be considered the first-line approach in HCV-associated low grade lymphomas if there is no immediate necessity of a conventional treatment (i.e., systemic symptoms, bulky disease or symptomatic splenomegaly), irrespectively of liver damage (generally mild) [103], as also recommended by recently updated hematological (ESMO [104] and NCCN [105]) and hepatology (EASL [106]) guidelines.

Among HCV-associated aggressive lymphomas, DLBCL is the most frequent type [107]. An immediate conventional therapy is required, being the immunochemotherapy scheme R-CHOP (rituximab, cyclophosphamide, doxorubicin, vincristine, prednisone) the standard choice [108]. The observation of a dissociation between HCV-RNA levels and liver injury after immunochemotherapy, suggested that liver impairment is not directly related to an enhanced HCV replication [109].

IFN-based AVT, when administered in combination with immunochemotherapy significantly increased hematologic toxicity [110], whereas, during the post-chemotherapy follow-up was associated to a better outcome [111]. HCV eradication by IFN-free AVT after completion of immunochemotherapy should also be recommended with the aim to eliminate the lymphoma trigger and potentially reduce the risk of lymphoma relapse [107,112]. Recently, it has been also reported that treatment of HCV infection in transplant recipients improves both lymphoma and liver disease outcomes strongly suggesting the use of IFN-free regimens following close monitoring for potential drug-drug interactions [113]. Concurrent administration of DAAs and immunochemotherapy should be tested in prospective trials, although no particular overlapping toxicities can be predicted. No specific recommendation is possible for HCV-positive DLBCL relapsed or refractory to a first-line treatment; however, high-dose chemotherapy with autologous support seems feasible in this setting [114,115].

3.3. HCV-associated kidney diseases

The association between HCV and chronic kidney disease (CKD) is undoubted. Several large surveys based on clinical databases suggested a significant impact of HCV on prevalence and incidence of CKD [116, 117]. A large case-control study [118] showed a significant association between HCV infection and membrano-proliferative glomerulonephritis (MPGN). In addition, HCV positive subjects showed a significantly higher prevalence of renal insufficiency (serum creatinine ≥ 1.5 mg/dl) after adjusting for influencing variables [119–121].

As previously observed, cryoglobulinemic nephropathies represent the most frequent conditions, with type I MPGN the most common form. Membrano-proliferative glomerulonephritis without cryoglobulinaemia, membranous nephropathy, and mesangioproliferative glomerulonephritis are rare pictures. Occasional observations of focal segmental glomerulosclerosis, fibrillary or immunotactoid glomerulopathies, or thrombotic microangiopathy have been also rarely reported [12]. MPGN can be diffuse or focal (more or less than 50% of involved glomeruli), and it is characterized by duplication of glomerular basement membrane (GBM), GBM interposition by mesangial cells (especially monocytes), sub-endothelial and mesangial deposition of immune reactants, mesangial proliferation with leukocyte exudation, endoluminal hyaline pseudo-thrombi (corresponding to cryoglobulin precipitates) and, rarely, extra-capillary proliferation.

A correct therapeutic approach involves the early evaluation of activity/severity of renal damage and its tendency to rapidly evolve, with individual tailoring of treatment. As an example, in case of cryoglobulinemic nephritis, the distinction between a diffuse or focal MPGN and mesangial glomerulonephritis (the main glomerular patterns of cryoglobulinemic nephritis) appears critical [122]. In fact, the main histopathological changes characterizing MPGN may improve with a strong immunomodulating treatment, including GCs and/or immunosuppressive agents and plasma exchange in escalation protocols.

Consequently, these measures should be the first-line therapeutic approach, considering AVT after improvement and stabilization of the condition. GCs should be given only at the onset of the vasculitis process and then rapidly tapered until discontinuation (see below). By contrast, the use of AVT, especially DAA-based, should be recommended as first-line approach in case of mesangial glomerulonephritis, where exudation, endo-capillary and extra-capillary proliferation, and endo-luminal thrombi are almost invariably absent and the lesions are likely to be self-limiting and spontaneously regressing. Significant poor prognostic variables (i.e., age, male gender, creatinine and proteinuria at the time of renal biopsy, number of clinical relapses, and poor blood pressure control) should also be taken into account [122]. Kaplan–Meier survival curves are worsened by creatinine value > 1.5 mg/dL ($133 \mu\text{mol/L}$) at the time of renal biopsy. Cardiovascular disease is the leading cause of death (over 60% of cases).

3.3.1. Etiologic treatment

The large majority of data about AVT have been derived from patients with CV. Several evidences justify the interest for HCV eradication in the setting of kidney disease. These include, first, the consistent role of the infection in conditioning the disease outcome (especially evident in kidney transplanted patients), as well as the significantly higher prevalence of HCV infection in nephropathic patients in comparison with the general population. Additional data arise from studies showing the positive effect of viral eradication on CKD and related mortality rates. In a recent population-based cohort including patients with diabetes mellitus [5], the 8-year cumulative incidence of end stage renal disease was significantly higher in HCV infected untreated than in the AVT treated and uninfected cohorts ($p < 0.001$). In the past years CV patients showed greater renal response rates when treated with a combination of RTX and PegIFN plus RBV compared with PegIFN and RBV alone [85,86]. The only availability of IFN-based AVT have been a limitation to the etiologic approach. However, the Kidney Disease Improving Global Outcomes (KDIGO) Group recommended in 2008 to treat patients with flares of CV MPGN with AVT, even if IFN-based; RBV dosage should be closely monitored due to the risk of anemia [123]. No doubt such recommendations are today obsolete. Recently, IFN-free AVTs, due to their good tolerance profile (despite some concerns regarding pharmacokinetics and safety in patients with severe renal failure) [124], will probably positively change the epidemiology of HCV-associated nephropathy. Sise et al., observed on a small cohort of 7 patients with CV and glomerulonephritis treated with IFN-free AVT that a SVR12 was correlated to an improvement in serum creatinine and a reduction in proteinuria [43]. In other recent observations the improvement of kidney disease in virological responders was progressively more evident from the inhibition of viral replication to 12 or 24 weeks after therapy [17,44,46].

3.3.2. Non-etiological treatment

Immunosuppression is still regarded as the first-line intervention in CV if renal involvement is severe/rapidly progressive. In these cases, AVT is usually insufficient to rapidly control renal disease and has also been shown to be detrimental in case of IFN and/or RBV. The conventional high-dose GCs, plasmapheresis, and, in more severe cases, cytotoxic therapy, have been commonly administered in patients with cryoglobulinemic nephritis [125]. Patients usually require multiple courses because of recurrent flares even after a prolonged remission. The combination of CTX (1.5–2 mg/kg/day given orally for 3 months, or 0.5–1 g administered intravenously every 2–4 weeks) in association with oral GCs (0.5–1 mg/kg/day for 1 month with subsequent tapering by 2.5–5 mg/week), often preceded by 3 pulses of 10–15 mg/kg methylprednisolone, represents a common therapy in the severe forms of cryoglobulinemic nephritis. The less toxic mycophenolate mofetil, given for 6 months, can be an alternative option to CTX. Plasma exchange, especially double-filtration plasmapheresis, continues to be successfully used in escalation protocols for rapidly progressive

glomerulonephritis. RTX has been successfully used alone, in combination with GCs and also with AVT in several studies. Detailed renal outcomes can be achieved on over 200 patients; renal response (complete plus partial) was 70–90%. Glomerulonephritis usually improves within 3 months; complete healing takes longer. No substantial adverse effects of RTX on HCV viremia were observed. However, a flare of CV has been reported in patients with high CG level receiving high doses RTX (1000 mg), suggesting that in such patients the protocol should start with plasmapheresis and then use the classical schedule (375 mg/m² per infusion) [126]. In a study on a large cohort of biopsy-proven severe cryoglobulinemic nephritis followed for 6 years after the administration of the 4 + 2 × 375 mg/m² protocol, the survival rate was 75% at 6 years and the probability of remaining symptom-free for 10 years was of about 60% [127].

3.4. Neuropsychiatric disorders and health-related quality of life (HRQoL)

3.4.1. Neuropsychiatric disorders

HCV is associated with various neuropsychiatric disorders [128]. The prevalence of depression is higher in HCV infected patients than in the general population (59% versus 21%) [129]. Approximately 60% of HCV infected patients suffer of sleep disorders [130], fatigue (prevalence: 50–67%) [131] and mood disorders that, in turn, negatively and independently affect the quality of life [132,133]. Cognitive impairment was also described [134,135]. These morbidities did not completely correlate with liver disease severity, suggesting a direct association with HCV [136,137]. It has been hypothesized that the virus enters the Central Nervous System (CNS) infecting CD68 + peripheral cells, microglia precursors [138]. Therefore, viral proteins could exert a neurotoxic effect [139,140]. The increased expression of cytokines, such as TNF- α and IL-8, could also play a role at local and systemic level [141, 142]. Furthermore, HCV may directly affect the serotonergic and dopaminergic neurotransmission with resultant depressive symptoms [143]. Rarely, neuropsychiatric manifestations are secondary to HCV-induced CV with abnormal brain MRI [144].

3.4.2. Health related quality of life (HRQoL)

Naive HCV-positive patients are characterized by poor HRQoL compared to the general population [145–147]. Based on the Short Form 36 (SF-36) Health Survey questionnaire, they consistently show deficits in several domains, particularly those involving physical role, general health and vitality [148–150]. In turn, poor HRQoL can lead to difficulties with interpersonal relations, decreased feelings of self-value and utility, and depression, with a decreased ability both at work and at home, and obvious cost implications.

3.4.3. Etiologic treatment

The relationship between mood disorders and IFN-based AVT has been widely discussed. IFN side-effects increased with higher doses and longer therapies [151]; the onset of depression has been observed in 30%–70% of treated patients [152,153]. IFN was also associated with sleep disturbances, anxiety, cognitive disorders (up to 50%), while manic and psychotic symptoms were less frequent (3% of patients). Irritability is also an important side-effect, involving approximately 75% of patients during therapy.

The HRQoL records during IFN and RBV therapy are usually low and the average scores of the SF-36 worsen rapidly, in particular, in the physical role, emotional role, vitality and social functioning [154]. Consequently, before to initiate an IFN-based treatment, a psychiatric counseling, should be recommended [151]. In some cases, the management of symptoms requires a therapy including pharmacological support with antidepressants (particularly selective serotonin reuptake inhibitors) or with benzodiazepines [155]. The possible co-morbidity with substance abuse limits the use of these drugs, for the risk of rebound effect, tolerance and dependence. In most instances the

neuropsychiatric symptoms are resolved after IFN discontinuation. After SVR, the HRQoL scores improve compared to baseline values [156].

The effect on HRQoL of IFN-free treatment has been studied by Younossi and colleagues in patients treated with sofosbuvir-based combinations with or without RBV [154,157,158]. Compared to placebo, these treatments were not associated with HRQoL impairment and the SVR correlated with HRQoL improvement [154]. Nevertheless, the presence of RBV still seems to poorly influence HRQoL, partly due to hemoglobin reduction; patient-reported outcomes (PRO's) are higher in RBV-free regimens [158].

In conclusion, compared to IFN-based, IFN-free AVTs, cause minimal reduction in PROs during therapy and improvement of vitality and fatigue at SVR12 [158]. Although few specific drug-drug interactions have been described between psychotropic molecules and DAAs (i.e. between Ritonavir and Carbamazepine, Nefazodone and Triazolam) [159] a cautious approach is needed since pharmacokinetic interactions can induce increase or reduction of one or both drugs, with toxicity or under-dosing risks.

3.5. Porphyria cutanea tarda (PCT)

PCT is characterized by low activity of uroporphyrinogen decarboxylase (URO-D) involved in heme synthesis. It can be classified as familial or sporadic. In the acquired, sporadic form (type I PCT) a 50% deficient activity of URO-D in the liver leads to an overt manifestation; this can be the consequence of a trigger such as HCV, alcohol and liver toxins [160–162]. Iron overload (hepatic siderosis) is a critical pathogenetic event, disrupting the enzymatic activity of URO-D by inducing the formation of an intracellular inhibitor [163]. The relationship with HCV infection is supported by epidemiological associations, especially in some geographical areas [164]. However, the absence of altered porphyrin metabolism in HCV-positive patients without PCT, argues against a direct role of HCV. PCT manifestations include typical cutaneous lesions in sun-exposed areas, photosensitivity, skin fragility, facial hypertrichosis and late-stage sclerodermoid plaques.

3.5.1. Etiologic treatment

The indirect role played by HCV infection and the sensitivity to the iron deposits due to the hemolytic effect of RBV, may explain the controversial results reported with IFN/RBV AVT. On one hand, an effective AVT may potentially improve clinical and laboratory manifestations of PCT, especially when preceded by therapeutic phlebotomy [162]. On the other hand, a worsening and a new-onset PCT have been reported in some cases [165], possibly due to the RBV-induced hemolytic anemia, further increasing liver iron excess. It is expected that the management of this condition could benefit from a viral eradication with both IFN- and RBV-free regimens, but no data are available today. It is also conceivable that DAAs already known to cause photosensitivity have to be avoided.

3.5.2. Non-etiological treatment

The standard of care for PCT includes photo-protection, anti-malarial drugs (chloroquine) and phlebotomy, the latter to reduce hepatic iron stores [163].

3.6. Lichen planus

Lichen planus (LP) is an inflammatory disorder involving the skin and the oro-genital mucous membranes. Oral LP is the most studied phenotype in the setting of HCV infection [166]. The association with HCV has been widely described [167] and it has been suggested that HCV-LP is the result of a T-cell mediated autoimmune reaction [168, 169]. Conflicting data may depend on geographical and/or methodological factors, with genetics (HLA-DR-associations), age and IFN-based AVT also playing a role [163].

3.6.1. Etiologic treatment

IFN-based AVT should be avoided. In fact, type-1 IFNs are a major driver of lichenoid inflammation [170] and IFN-based AVT may negatively influence established LP or induce the onset of lichenoid lesions. This increases the interest for studies on IFN-free AVT, although no data are available at present.

3.6.2. Non-etiological treatment

Treatment of LP is based on a step-wise approach with the use of topical and/or systemic immune-modulating agents, tailored on disease's characteristics [171]. Systemic treatment is indicated in severe/advanced disease, and includes retinoids (acitretin), GCs, methotrexate, and cyclosporine [172]. In HCV-positive LP it should be performed considering the severity of liver disease: a strict follow-up of the main liver function tests (LFTs) should be performed as well as an accurate evaluation of the possible drug-drug interactions between DAAs and non-etiological drugs (i.e., cyclosporine).

3.7. HCV-associated endocrine disorders

The main endocrine HCV-EHDs are represented by thyroid diseases and type 2 diabetes mellitus (T2DM) [19,127]. Gonadal dysfunctions are reported in male HCV-infected individuals [19], but data on specific therapies are lacking.

3.7.1. Thyroid disorders

Autoimmune thyroid diseases are among the most frequent endocrine disorders in HCV infected patients [173]. They result from a dysregulation of the immune system leading to T cell-mediated organ-specific autoimmunity. In 80–85% of cases, circulating thyroid autoantibodies are detected; thyroid ultrasonography and cytology can help in the diagnosis. A thyroid dysfunction (mainly hypothyroidism) is present in about 30% of patients [127]. In a recent meta-analysis, the prevalence of anti-thyroglobulin antibody (AbTG), anti-thyroid peroxidase antibody (AbTPO), anti-thyroid microsomal antibody (ATMA) and hypothyroidism were higher in HCV positive patients than in controls [174]. An even higher prevalence of thyroid dysfunction was observed in HCV-CV patients [175,176].

A higher prevalence of papillary thyroid cancer has been found in chronically HCV-infected patients, particularly in those with autoimmune thyroid diseases [173]. In a recent wide cohort study, anti-HCV seropositivity was associated with multivariate-adjusted hazard ratio for thyroid cancer [6].

3.7.1.1. Etiologic treatment. IFN- α therapy is a well-known risk for the development of autoimmune thyroid diseases and thyroid dysfunctions [177]. Thyroid disease developed in up to 25–30% of HCV patients during Peg-IFN/RBV treatment, and about half of these patients need thyroid treatment [178]. Most patients with IFN- α -induced hyperthyroidism present Hashimoto disease and have a transitory hyperthyroidism, while a minority of them develop Graves' disease. In patients with long-term hyperthyroidism and Graves' disease, radioiodine therapy was effective and well-tolerated [179].

A recent study retrospectively analyzed data from Graves' disease patients with or without HCV infection treated with IFN- α or methimazole (MMI), respectively. Results suggested a more favorable course of Graves' disease in HCV patients treated with IFN- α , than in uninfected patients [180].

Assessment of thyroid-stimulating hormone (TSH) and thyroid autoantibodies at baseline and close monitoring of thyroid function during Peg-IFN/RBV therapy are necessary for early detection and management of IFN-induced thyroid disease [181].

High values of the circulating prototype Th1 chemokine (C-X-C motif) ligand 10 (CXCL10), are present in HCV CHC and CV patients with autoimmune thyroid diseases [182]. However, lower pretreatment serum CXCL10 levels were associated with thyroid disease, and thyroid

disease prevalence increases in HCV female patients and patients who are positive for AbTPO at baseline, treated with Peg-IFN α -2a/RBV [183]. In another study, thyroid disease with high TSH levels has been shown to be associated with good response to Peg-IFN/RBV [184].

Currently, scarce data exist about IFN-free AVT. The possibility of interactions of levo-thyroxine (L-T4) (the common treatment for HCV autoimmune thyroid diseases) [185] with DAAs suggest an accurate tailoring of treatment schedules [186].

3.7.1.2. Non-etiological treatment. Treatment of thyroid disease (hypothyroidism/hyperthyroidism) or thyroid cancer should be performed when needed, according to the current specific guidelines [187].

3.7.2. Type 2 diabetes mellitus

Epidemiological data support the association between HCV infection and T2DM [19,188]. In a review of 102 studies, diabetes was one of the most common HCV-EHM (15% of patients) [189] with important implications for outcome, prevention and treatment. It was shown that T2DM, with or without insulin resistance (IR), reduces responsiveness to IFN-based AVT [190,191] and was associated with higher risk of developing cirrhosis and hepatocellular carcinoma (HCC), even after viral eradication [192,193].

HCV may induce IR through multiple mechanisms [194]. In turn, IR plays a crucial role in fibrosis progression, and has a negative impact on AVT responses [195]. Obesity and physical inactivity also cause hyperinsulinemia, and accelerate HCV-induced damage [196]. HCV-induced IR can also lead to arterial hypertension, hyperuricemia, and atherosclerosis, resulting in increased cardiovascular mortality. The interaction of T2DM with CHC and "non-alcoholic fatty liver disease" (NAFLD) may result in a "vicious circle", that can lead to an increased risk of all-cause mortality and liver-related and cardiovascular complications [197,198]. In turn, HCV infection in patients with T2DM may also increase the proportion of DM-related kidney complications [199].

3.7.2.1. Etiologic treatment. Most available data are concerning IFN-based AVT. Clinical trials reported improvement of glucose metabolism [200] and reduction in the T2DM incidence after HCV eradication [201]. Concerning DAAs, a case report showed improved glycemic control after a successful sofosbuvir-based regimen in a patient with poorly controlled T2DM [202], while other analyses showed a marginal impact of IFN-free regimens on hemoglobin A1c [203]. T2DM was also a negative predictor of patient-reported outcomes [204]. Further studies are needed to correctly evaluate the AVT influence on the long-term course of T2DM.

3.7.2.2. Non-etiological treatment. HCV-T2DM requires [205] various measures including: lifestyle changes, regular diabetes screening, analysis of other risk factors accelerating both CHC and DM, such as obesity, dyslipidemia, and alcohol consumption. Early identification and treatment of IR or T2DM reduce liver disease progression [206], incidence of HCC, transplant-related morbidity and mortality, and improve the AVT response [191,207], minimizing side effects [200].

Therapeutic options in HCV-T2DM include diet changes, anti-diabetic drugs, statins. It is not clear whether the best approach is a peroxisome proliferator-activated receptor (PPAR) agonist or a biguanide such as metformin [208–210]. Prospective, randomized controlled trials showed increased SVR using metformin in HCV patients with IR receiving AVT [211]. Different analyses that evaluated metformin use in these patients showed a significant reduction of HCC, liver-related death, and liver transplant with an increased survival rate [211]. Concerning statins, the inhibition of HCV replication was shown *in vitro* [128], but not *in vivo* [212,213].

3.8. Sicca syndrome/Sjögren's syndrome

The frequent association between sicca syndrome and HCV infection has been shown by both experimental and epidemiological studies [160,214,215]. Sicca syndrome related symptoms have been reported in 20% to 30% of HCV patients, whereas less than 5% of patients with a defined Sjögren's syndrome are HCV-positive [216]. Although low titers of antinuclear antibodies and RF are common in patients with HCV-related sicca syndrome, the presence of primary Sjögren's syndrome related autoantibodies (anti-SSA/SSB) is uncommon.

Similarities exist between HCV-related sicca syndrome and “true” primary Sjögren's syndrome. However, HCV-positive sicca syndrome patients are older and more likely to have photosensitivity and CV than patients with primary Sjögren's syndrome [217]. Patients with CV may develop a mild sicca syndrome in the absence of typical histopathological and/or serological alterations. In some cases the differential diagnosis between primary Sjögren's syndrome and CV may be very difficult, mainly in patients with overt sicca syndrome, cryoglobulinemia, and HCV infection [218].

3.8.1. Etiologic treatment

IFN-based AVT generally has scarce clinical efficacy, probably because in many cases, the onset of symptoms is a consequence of gland destruction. There is no available data with IFN free DAAs.

3.8.2. Non-etiological therapy

Besides topical treatments that may partially improve HRQoL, there is no specific systemic treatment for HCV-associated sicca syndrome [219].

3.9. Arthritis

Arthralgia is common in HCV-infected patients [220] while arthritis is rare (4%–5%) [221,222]. Two different subsets of HCV-related arthritis have been identified in some studies on limited groups: the more common symmetrical polyarthritis and the intermittent mono-oligoarthritis [223–226]. The symmetrical polyarthritis subset shares several aspects with rheumatoid arthritis (RA): symmetrical involvement of wrists and hands; positive RF in more than 50% of patients, and increased inflammation markers. However, the course of HCV related symmetrical polyarthritis is less aggressive when compared with RA, typically non-deforming and not associated with articular bone erosions; rheumatoid nodules were never reported [227,228]. Anti-CCP antibodies can be helpful in the differential diagnosis between HCV related symmetrical polyarthritis and RA because they are rarely detected in the former and almost constant in the latter [229,230]. The intermittent mono-oligoarthritis subset typically involves the medium and large joints of the lower limbs, mainly the ankles [227,228]. Its course is usually acute, with frequent relapses. The intermittent mono-oligoarthritis subset is closely related to cutaneous and laboratory manifestations of CV. Intermittent mono-oligoarthritis flares frequently occur simultaneously to skin flares of CV.

3.9.1. Etiologic treatment

It has been suggested that, once the diagnosis of HCV-associated arthritis is made, AVT can be taken into account. PegIFN plus RBV AVT has been successfully used [19,225,231], but it can promote the worsening of arthritis in others [232]. Therefore, it is conceivable that IFN-free regimens will be more useful.

3.9.2. Non-etiological treatment

Anti-TNF agents are safe in patients with concomitant HCV infection and classical RA [233], but their use appears generally excessive. Therapeutic approaches to HCV-related arthritis remains largely empirical, because few studies have been published. Usually, HCV-related arthritis patients may respond to low doses GCs and hydroxychloroquine.

Concerns may be raised regarding the use of immunosuppressive or potentially hepatotoxic drugs, in particular methotrexate and leflunomide, often not necessary or contraindicated. On the contrary, RTX may be successfully employed, mainly in patients with more aggressive disease, and may represent the first-choice treatment in patients with arthritis in the setting of CV [234].

3.10. Miscellanea

For other HCV-EHMs, data about the effect of viral eradication (representing the most important argument in favor of a true etiopathogenetic association) are, at present, too scarce or absent. Some of these can represent either EHMs or side-effects of AVT or consequences of advanced liver damage, making frequently difficult their exact attribution. These latter include pruritus, psoriasis and other skin disorders. Other cases, like urticaria, have been only suspected to be associated with HCV, due to the existence of both limited and discordant data.

4. Discussion

We recently formed an International Study Group of Extrahepatic Manifestations related to HCV (ISG-EHCV) with the aim to provide a homogeneous clinico-diagnostic [19] and therapeutic approach to HCV patients presenting with HCV-EHMs through the development of a multidisciplinary international network of experts.

This paper summarizes recommendations about a new hot and discussed topic in the managing of HCV infection: the therapeutic approach to various extrahepatic diseases more or less directly linked to this infection. HCV-EHMs have been shown to be responsible for significantly higher mortality/morbidity rates when compared with non-infected (or no more infected) subjects [6], with important consequences in terms of social costs.

The present recommendations are based only on scientific criteria and do not take into account the debated issue related to the cost/benefit ratio, which is also a concern, especially in some regions of the world.

In each HCV-EHM, the actual pathogenic role played by the virus was evaluated in order to better understand the opportunity and urgency to use AVT. In turn, the possibility to completely eradicate the infection, appears crucial to better evaluate such a role (“ex adjuvantibus criterium”). For disorders, like the HCV-related LPDs, the effect of viral eradication represents the stronger proof of the etiopathogenetic involvement of HCV. In this light, however, the former IFN-based etiologic therapy frequently provided an uncertain “ex adjuvantibus” picture, due to indirect immunomodulatory effects of IFN, especially in studies with a short follow-up. The availability of drugs directly acting on the virus in IFN-free combinations led to minimize or abolish (in both IFN- and RBV-free regimens) such immunomodulatory effects. Furthermore, their safety promises to allow the HCV eradication also in patients previously intolerant with severe HCV-EHMs. On the other hand, it is conceivable that, in some cases, the positive effects on HCV-EHMs (improvement or resolution) at the end of treatment and in the early post treatment period, will be less evident compared to IFN-based AVT. Available, although limited data, obtained in HCV LPDs like CV and NHL [46] seem to be in agreement with this hypothesis, suggesting the opportunity for a longer follow-up. A long-term post-treatment follow-up appears of interest also in other HCV- EHMs, in order to evaluate the real impact of DAA-based therapy.

Another confirmation arises from the observation of a paradoxical improvement of some HCV-EHMs despite of HCV persistence (virologic non-response), observed after IFN-based regimens and usually transient [17]. The availability of drugs without immune-modulatory properties, makes also easier the decision to treat patients with autoimmune disorders and uncertain viral etiopathogenesis, thus at risk of worsening after an IFN-based therapy. The availability of IFN-free AVT support the

recommendation to eradicate, as soon as possible, a virus known to strongly sustain B-cell activation and with lymphomagenetic potential. In other words, IFN-free AVT should be a priority in HCV-positive autoimmune and/or lymphoproliferative disorders, even if the liver damage is not severe.

The urgent need of clear and easy-to-use therapeutic guidelines, comes from this specific aspect in managing a patient with EHMs. The hepatologist has to be advised that a counseling with a specialist may be not sufficient, because both physicians should recognize a new systemic pathological entity generated by the infection, the so-called HCV-disease [19]. In more details, the therapeutic approach could not be referred to specialist guidelines for each specific manifestation/symptom, but should take into account the strong impact on all the aspects of HCV infection. This should happen not only when the probability is high that HCV is the causal agent of an EHM (as it is for HCV-CV), but also when the virus is only a trigger (as for HCV-PCT).

The exchange of information between different specialists has to aim at evaluating the pros and contras of different interventions and their timelines. An exemplary case is represented by situations requiring a non-etiological priority approach (i.e. rapidly evolving HCV-EHMs or, conversely, in absence of national health care reimbursement as presently in some countries. Another example is given by difficult-to-treat cases for patient's characteristics (i.e. advanced cirrhosis in an experienced patient previously not responsive to AVT) and/or for the virus (i.e. HCV genotype 3). Usually, in these conditions, RBV is indicated to increase the chances of viral eradication, but it is contraindicated or should be used cautiously for some EHMs (i.e. in presence of ischemic damage, significant renal damage, PCT).

Table 5

Take-home messages

Antiviral (etiological) treatment of HCV-EHMs
<ul style="list-style-type: none"> • IFN-free, DAA-based antiviral therapy should be considered a first line therapeutic measure for HCV-EHMs that does not need urgent/life threatening measures • All patients with HCV-EHMs without short life expectancy due to non HCV-related comorbidities should be considered for treatment • When universal treatment may not be scaled up, HCV-EHMs should be considered a prioritization criterion • The first target of etiologic therapy is the HCV eradication and consequent HCV-EHM improvement • The degree of HCV-EHM clinical improvement depends on the degree of reversibility of the HCV-induced damage and/or the underlying pathogenic process : early viral eradication is recommended • IFN-free DAA treatment of HCV-EHMs, should follow general criteria standardized for the treatment of HCV infection, accurately taking into account the HCV-EHMs characteristics • Both IFN- and RBV-free DAA therapy should be preferred in patients with kidney disease, PCT, ischemic tissue lesions (i.e., skin ulcers, ischemic heart disease), anemia (i.e., in LPDs) • Therapy of kidney disease imply a careful approach, including accurate evaluation of the kidney damage and choice of DAA treatment and follow-up schedule • Using IFN-free DAA therapy, the possible "rebound effect" of abrupt withdrawn of non-etiological therapy should not be interpreted as DAAs side effect
Non antiviral (non etiologic) treatment of HCV-EHMs
<ul style="list-style-type: none"> • Non-etiological therapy is the first line treatment in case of HCV-EHMs needing urgent/life threatening measures, but should be useful also in less severe cases before, during or after antiviral therapy in patients with persistent disease • The combination of IFN-free DAA and non-etiological therapy can be allowed, especially in severe cases • Persistence after antiviral therapy of immunological/laboratory abnormalities (i.e., cryoglobulinemia) in the absence of any clinically evident disease, does not justify therapy • The choice of non-etiological therapy should always take into account the degree of HCV-related liver damage and, in case of DAAs co-administration, the possible drug-drug interactions • In clinically moderate-severe autoimmune/lymphoproliferative HCV-EHMs (especially cryoglobulinemic vasculitis) with failure or contraindication to antiviral treatment, Rituximab should be considered a first line therapeutic measure. Combined treatment can be indicated.

Non etiologic therapies also need a close collaboration between specialists of different medical areas: i.e. to manage patients with co-morbidities requiring a chronic administration of drugs potentially interacting with some DAAs. This means that it is important to agree on tailoring both the AVT and the other therapies possibly rescheduling one and/or making appropriate changes with non-interfering alternative drugs. Dedicated websites could support and help the health care providers in this kind of decision.

The critical point is therefore a wider and multidisciplinary spreading of the knowledge about HCV-EHMs, in order to provide a more conscious and aware approach. The present recommendations are designed to address this need. They mean to briefly recall to non-specialists, the essential features of the different manifestations of the HCV disease in order to provide the best intervention in terms of etiologic and/or non-etiological (pathogenetic-symptomatic) treatments.. This would be the necessary basis for future modifications according to available new data. A Delphi survey provided by the same expert group recently scored the principal statements (Ramos-Casals M et al. J. Hepatology, in press).

Overall, the main take home messages we can highlight from the available data are briefly summarized in Table 5.

In conclusion, although the hope for a definitive cure for the HCV EHMs seems to be closer than ever, the complexity of these patients in whom different etiopathogenic scenarios are coexisting (autoimmune, metabolic, neoplastic) anticipate a more difficult therapeutic scenario than that is now reported in the standard HCV infected patients' population.

In other words, with this work we would like to provide patients, health care practitioners and specialists of the referral centers proper information on the structured and comprehensive management of patients with a complex pathological entity, the HCV disease.

Appendix A

International Study Group of Extrahepatic Manifestations Related to Hepatitis C Virus Infection (ISG-EHCV):

Convenors of the ISG-EHCV:

Patrice Cacoub, MD (COORDINATOR)

Department of Internal Medicine and Clinical Immunology

Hopital La Pitié Salpêtrière

83 Boulevard de l'hôpital 75013 Paris, France

Departement Hospitalo-Universitaire I2B

UMR 7211 (UPMC/CNRS), UMR S-959 (INSERM)

Université Pierre Marie Curie, Paris 6.

tel. + 33 1 42 17 80 27; fax + 33 1 42 17 80 33

E-mail: patrice.cacoub@psh.aphp.fr

Milvia Casato

Department of Clinical Immunology,

Sapienza University of Rome, Viale dell'Università 37,

00185 Rome, Italy

E-mail: milvia.casato@uniroma1.it

Clodoveo Ferri

Chair and Rheumatology Unit,

Medical School, University of Modena and Reggio Emilia,

zienda Ospedaliero-Universitaria, Policlinico di Modena,

41124 Modena, Italy

E-mail: clferri@unimore.it

Peter Lamprecht

Department of Rheumatology & Vasculitis Center, University of Lübeck, Ratzeburger

Allée 160, 23538 Lübeck, Germany, Tel.: ++49 (0)451500 2368,

Fax: ++49 (0)451500

3650, E-mail: peter.lamprecht@uksh.de

Alessandra Mangia

Liver Unit, IRCCS "Casa Sollievo della Sofferenza",

San Giovanni Rotondo, Italy.

a.mangia@tin.it

Manuel Ramos-Casals
Department of Autoimmune Diseases
Josep Font Laboratory of Autoimmune Diseases
Hospital Clinic CELLEX-IDIBAPS
08036 Barcelona, Spain
Tel: + 34-932275774; Fax: + 34-932271707
E-mail: mramos@clinic.ub.es

David Saadoun
Department of Internal Medicine and Clinical Immunology
Hopital La Pitié Salpêtrière
83 Boulevard de l'hopital
75013 Paris, FRANCE
UMR 7211 (UPMC/CNRS), UMR S-959 (INSERM)
Université Pierre Marie Curie, Paris 6.
tel. + 33 1 42 17 80 27; fax + 33 1 42 17 80 33
E-mail: david.saadoun@psl.aphp.fr

Athanasios G Tzioufas
Director Department of Pathophysiology
School of Medicine University of Athens
75 M. Asias st, Building 16, Room 32
11527 Athens, Greece
E-mail: agtzi@med.uoa.gr
Zobair M Younossi
Chairman, Department of Medicine, Inova Fairfax Medical Campus
Vice President for Research, Inova Health System
Professor of Medicine, VCU-Inova Campus
The Claude Moore Health Education and Research Center
Beatty Center for Integrated Research
3300 Gallows Road, Falls Church, VA 22042, USA
Telephone 703-776-2540; Fax 703-776-4388
E-mail: Zobair.Younossi@inova.org

Anna Linda Zignego; MD, Ph.D
Professor of Medicine, Interdepartmental Center MaSVE
Department of Experimental and Clinical Medicine
Medical School, University of Florence
Largo Brambilla, 3 50134 Firenze, Italy.
Tel: + 39055 2758086; Fax: + 39055 7947335
E-mail: annalinda.zignego@unifi.it

Multidisciplinary International Working Group of the ISG-EHCV
Advisory Working Group:

Dr. Anne Claire Desbois, MD, Research fellow, Université Pierre et Marie Curie, Paris (anneclairedesbois@yahoo.fr)

Dr. Cloe Comarmond, MD, Research fellow, Université Pierre et Marie Curie, Paris (clocomarmond2015@gmail.com)

Prof Oliver Hermine, Hematologist, Université Paris Descartes, Paris (olivier.hermine@nck.aphp.fr)

Dr. Pilar Brito-Zeón, Research Fellow, Hospital Clinic, Barcelona (mbrito@clinic.ub.es)

Prof. Xavier Fornas, Hepatologist, Hospital Clinic, Barcelona (xfornas@clinic.ub.es)

Prof. Armando Lopez-Guillermo, Hematologist, Hospital Clinic, Barcelona (alopezg@clinic.ub.es)

Dr. Laura Gragnani, Research Fellow Interdepartmental Center MaSVE Department of Experimental and Clinical Medicine, University of Florence, Florence, Italy (laura.gragnani@unifi.it)

Prof. Alberto Bosi, Hematologist, University of Florence (alberto.bosi@unifi.it)

Prof. Marco Matucci Cerinic, Rheumatologist, University of Florence (marco.matuccicerinic@unifi.it)

Prof. Luca Arcaini, Department of Molecular Medicine, University of Pavia & Department of Hematology Oncology, Fondazione IRCCS Policlinico San Matteo, Pavia, Italy luca.arcaini@unipv.it

Prof. Dario Roccatello, Center of Research of Immunopathology and Rare Diseases, and Nephrology and Dialysis Unit. San G. Bosco Hospital and University of Turin, Italy dario.roccatello@unito.it

Dr. Marcella Visentini, Research fellow, Sapienza University of Rome (marcella.visentini@uniroma1.it)

Dr. Alessandro Pulsoni, Hematologist, Sapienza University of Rome (pulsoni@bce.uniroma1.it)

Dr. Adriano De Santis, Hepatologist, Sapienza University of Rome (adsdmc@tin.it)

Dr. Theodoros Androutsakos, Research fellow, University of Athens
Prof. Gregory Hatzis, Hepatologist, University of Athens

Dr. Anja Kerstein, Research fellow, University of Lübeck (anja.kerstein@uksh.de)

Dr. Susanne Schinke, Rheumatologist, University of Lübeck (s.schinke@uksh.de)

Prof. Klaus Fellermann, Gastroenterologist & Hepatologist, University of Lübeck (klaus.fellermann@uksh.de)

Dr. Sandra Muñoz, Rheumatologist, Centro Médico Nacional 20 de Noviembre, ISSSTE, México DF (ssanml@yahoo.com.mx)

Dr. Francisco Medina, Rheumatologist, Hospital de Especialidades, Centro Médico Nacional Siglo XXI, Mexico DF (fmedina_99@yahoo.com)

Dr. Luis-Javier Jara, Rheumatologist, Centro Médico Nacional La Raza, Mexico DF (luis_jara_quezada@hotmail.com)

Dr. Mario García-Carrasco, Rheumatologist, Systemic Autoimmune Diseases Research Unit, IMSS, Puebla, México Department of Rheumatology and Immunology, Benemérita Universidad Autónoma de Puebla, Puebla, México (mgc30591@yahoo.com)

Prof. Munther Khamashta, Internist & Rheumatologist, Dubai Hospital, Dubai, United Arab Emirates (munther.khamashta@kcl.ac.uk)

Prof. Yehuda Shoenfeld, Head Zabudowicz Center for Autoimmune Diseases, Sheba Medical Center, Tel-Hashomer, Israel (Yehuda.Shoenfeld@sheba.health.gov.il)

Prof. John H. Stone, Harvard Medical School, Boston, MA, US (jhstone@partners.org)

Dr. Soledad Retamozo, Hospital Privado, Centro Médico de Córdoba, Córdoba, Argentina (soleretamozo@hotmail.com)

Prof. Chien-Jen Chen, National Taiwan University, Nankang, Taipei 11529, Taiwan (cjchen@ntu.edu.tw)

Prof. Margit Zeher, University of Debrecen, Debrecen, Hungary (zeher@iibel.dote.hu)

Prof. Elke Theander and Thomas Mandl, Skåne University Hospital, Malmö, Sweden (elke.theander@med.lu.se) (thomas.mandl@med.lu.se)

Prof. Gaafar Ragab, MD, Dr. Mohamed Tharwat Hegazy, MSc Internal Medicine, Faculty of Medicine, Cairo University Department of Internal Medicine Clinical Immunology and Rheumatology Unit Internal Medicine Hospital, Kasr Al-Ainy, 8 Kasr Al-Ainy st., Cairo, P.O. 11562. Tel: + 201005190006; Fax: + 20 233380345, Mailing address: P.O. Box: 152 Orman, Giza, Egypt, 12612 E-mail: gragab@kasralainy.edu.eg or gaafarr@gmail.com

Dr. Alexandre Da Sousa, rheumatologist, Rua Loefgren, 1587. Apt 82. Vila Clementino. Sao Paulo 04040-032, Brazil, alexandrewagner@uol.com.br

Prof. Alessandro Antonelli, Dr. Poupak Fallahi MD, Department of Clinical and Experimental Medicine, University of Pisa, Via Savi 10, Pisa 56126, Italy. alessandro.antonelli@med.unipi.it

Dr. Teresa Urraro, Dr. Elena Gianni, Dr. Monica Monti, Elisa Fognani, Interdepartmental Center MaSVE, Department of Experimental and Clinical Medicine, University of Florence, Largo Brambilla, 3, 50134 Firenze, Italy. (teresa.urraro@yahoo.it; elegianni@yahoo.it; m.monti@dm.unifi.it; elisa.fognani@gmail.com)

Dr. Silvia Martina Ferrari: Department of Clinical and Experimental Medicine, University of Pisa, Via Savi 10, Pisa 56126, Italy.

Dr. Marco Sebastiani, Dr. Dilia Giuggioli, Dr. Michele Colaci, Chair and Rheumatology Unit, Medical School, University of Modena and Reggio Emilia, Azienda Ospedaliero-Universitaria, Policlinico di Modena, via del Pozzo 71 41124 Modena, Italy (marco.sebastiani@unimore.it - diliagiuggioli@hotmail.com - michelecolaci@virgilio.it)

References

- [1] Zignego AL, Ferri C, Pileri SA, Caimi P, Bianchi FB. Extrahepatic manifestations of Hepatitis C Virus infection: a general overview and guidelines for a clinical approach. *Dig Liver Dis* 2007;39:2–17.
- [2] Backus LI, Boothroyd DB, Phillips BR, Belperio P, Halloran J, Mole LA. A sustained virologic response reduces risk of all-cause mortality in patients with hepatitis C. *Clin Gastroenterol Hepatol* 2011;9:509–16:e1.
- [3] El-Kamary SS, Jhaveri R, Shardell MD. All-cause, liver-related, and non-liver-related mortality among HCV-infected individuals in the general US population. *Clin Infect Dis* 2011;53:150–7.
- [4] Harris HE, Ramsay ME, Andrews NJ. Survival of a national cohort of hepatitis C virus infected patients, 16 years after exposure. *Epidemiol Infect* 2006;134:472–7.
- [5] Hsu YC, Lin JT, Ho HJ, Kao YH, Huang YT, Hsiao NW, et al. Antiviral treatment for hepatitis C virus infection is associated with improved renal and cardiovascular outcomes in diabetic patients. *Hepatology* 2014;59:1293–302.
- [6] Lee MH, Yang HI, Lu SN, Jen CL, You SL, Wang LY, et al. Chronic hepatitis C virus infection increases mortality from hepatic and extrahepatic diseases: a community-based long-term prospective study. *J Infect Dis* 2012;206:469–77.
- [7] Uto H, Stuver SO, Hayashi K, Kumagai K, Sasaki F, Kanmura S, et al. Increased rate of death related to presence of viremia among hepatitis C virus antibody-positive subjects in a community-based cohort study. *Hepatology* 2009;50:393–9.
- [8] Maasoumy B, Wedemeyer H. Natural history of acute and chronic hepatitis C. *Best Pract Res Clin Gastroenterol* 2012;26:401–12.
- [9] Omland LH, Jepsen P, Krarup H, Schonning K, Lind B, Kromann-Andersen H, et al. Increased mortality among persons infected with hepatitis C virus. *Clin Gastroenterol Hepatol* 2011;9:71–8.
- [10] Kawamura Y, Ikeda K, Arase Y, Yatsuji H, Sezaki H, Hosaka T, et al. Viral elimination reduces incidence of malignant lymphoma in patients with hepatitis C. *Am J Med* 2007;120:1034–41.
- [11] Adinolfi LE, Zampino R, Restivo L, Lonardo A, Guerrero B, Marrone A, et al. Chronic hepatitis C virus infection and atherosclerosis: clinical impact and mechanisms. *World J Gastroenterol* 2014;20:3410–7.
- [12] Cacoub P, Gragnani L, Comarmond C, Zignego AL. Extrahepatic manifestations of chronic hepatitis C virus infection. *Dig Liver Dis* 2014;46(Suppl. 5):S165–73.
- [13] Ferri C, Zignego AL, Longombardo G, Monti M, La Civita L, Lombardini F, et al. Effect of alpha-interferon on hepatitis C virus chronic infection in mixed cryoglobulinemia patients. *Infection* 1993;21:93–7.
- [14] Misiani R, Bellavita P, Fenili D, Vicari O, Marchesi D, Sironi PL, et al. Interferon alfa-2a therapy in cryoglobulinemia associated with hepatitis C virus. *N Engl J Med* 1994;330:751–6.
- [15] Adinolfi LE, Uttili R, Zampino R, Ragone E, Mormone G, Ruggiero G. Effects of long-term course of alpha-interferon in patients with chronic hepatitis C associated to mixed cryoglobulinemia. *Eur J Gastroenterol Hepatol* 1997;9:1067–72.
- [16] Mazzaro C, Monti G, Saccardo F, Zignego AL, Ferri C, De Vita S, et al. Efficacy and safety of peginterferon alfa-2b plus ribavirin for HCV-positive mixed cryoglobulinemia: a multicentre open-label study. *Clin Exp Rheumatol* 2011;29:933–41.
- [17] Gragnani L, Fognani E, Piluso A, Boldrini B, Urraro T, Fabbri A, et al. Long-term effect of HCV eradication in patients with mixed cryoglobulinemia: a prospective, controlled, open-label, cohort study. *Hepatology* 2015;61:1145–53.
- [18] Banerjee D, Reddy KR. Review article: safety and tolerability of direct-acting antiviral agents in the new era of hepatitis C therapy. *Aliment Pharmacol Ther* 2016;43:674–96.
- [19] Ferri C, Ramos-Casals M, Zignego AL, Arcaini L, Roccatello D, Antonelli A, et al. International diagnostic guidelines for patients with HCV-related extrahepatic manifestations. A multidisciplinary expert statement. *Autoimmun Rev* 2016;15:1145–60.
- [20] Zignego AL, Ferri C, Giannini C, La Civita L, Carecchia G, Longombardo G, et al. Hepatitis C virus infection in mixed cryoglobulinemia and B-cell non-Hodgkin's lymphoma: evidence for a pathogenetic role. *Arch Virol* 1997;142:545–55.
- [21] Ferri C, La Civita L, Longombardo G, Greco F, Bombardieri S. Hepatitis C virus and mixed cryoglobulinemia. *Eur J Clin Invest* 1993;23:399–405.
- [22] Zignego AL, Gragnani L, Giannini C, Laffi G. The hepatitis C virus infection as a systemic disease. *Intern Emerg Med* 2012;7(Suppl. 3):S201–8.
- [23] Lidar M, Lipschitz N, Agmon-Levin N, Langevitz P, Barzilai O, Ram M, et al. Infectious serologies and autoantibodies in hepatitis C and autoimmune disease-associated mixed cryoglobulinemia. *Clin Rev Allergy Immunol* 2012;42:238–46.
- [24] Peveling-Oberhag J, Arcaini L, Bankov K, Zeuzem S, Herrmann E. The anti-lymphoma activity of antiviral therapy in HCV-associated B-cell non-Hodgkin lymphomas: a meta-analysis. *J Viral Hepat* 2016;23:536–44.
- [25] Zignego AL, Giannini C, Gragnani L. HCV and lymphoproliferation. *Clin Dev Immunol* 2012;2012:980942.
- [26] Zignego AL, Gragnani L, Piluso A, Sebastiani M, Giuggioli D, Fallahi P, et al. Virus-driven autoimmunity and lymphoproliferation: the example of HCV infection. *Expert Rev Clin Immunol* 2015;11:15–31.
- [27] Sene D, Ghillani-Dalbin P, Thibault V, Guis L, Musset L, Duhaut P, et al. Long-term course of mixed cryoglobulinemia in patients infected with hepatitis C virus. *J Rheumatol* 2004;31:2199–206.
- [28] Ferri C, Marzo E, Longombardo G, Lombardini F, La Civita L, Vanacore R, et al. Interferon-alpha in mixed cryoglobulinemia patients: a randomized, crossover-controlled trial. *Blood* 1993;81:1132–6.
- [29] Marcellin P, Descamps V, Martinot-Peignoux M, Larzul D, Xu L, Boyer N, et al. Cryoglobulinemia with vasculitis associated with hepatitis C virus infection. *Gastroenterology* 1993;104:272–7.
- [30] Johnson RJ, Gretch DR, Yamabe H, Hart J, Bacchi CE, Hartwell P, et al. Membranoproliferative glomerulonephritis associated with hepatitis C virus infection. *N Engl J Med* 1993;328:465–70.
- [31] Joshi S, Kuczynski M, Heathcote EJ. Symptomatic and virological response to antiviral therapy in hepatitis C associated with extrahepatic complications of cryoglobulinemia. *Dig Dis Sci* 2007;52:2410–7.
- [32] Landau DA, Saadoun D, Halfon P, Martinot-Peignoux M, Marcellin P, Fois E, et al. Relapse of hepatitis C virus-associated mixed cryoglobulinemia vasculitis in patients with sustained viral response. *Arthritis Rheum* 2008;58:604–11.
- [33] Montalbano M, Pasulo L, Sonzogni A, Remuzzi G, Colledan M, Strazzabosco M. Treatment with pegylated interferon and ribavirin for hepatitis C virus-associated severe cryoglobulinemia in a liver/kidney transplant recipient. *J Clin Gastroenterol* 2007;41:216–20.
- [34] Garini G, Allegri L, Lannuzzella F, Vaglio A, Buzio C. HCV-related cryoglobulinemic glomerulonephritis: implications of antiviral and immunosuppressive therapies. *Acta Biomed* 2007;78:51–9.
- [35] Cacoub P, Lidove O, Maisonobe T, Duhaut P, Thibault V, Ghillani P, et al. Interferon-alpha and ribavirin treatment in patients with hepatitis C virus-related systemic vasculitis. *Arthritis Rheum* 2002;46:3317–26.
- [36] Mazzaro C, Zorat F, Comar C, Nascimben F, Bianchini D, Baracetti S, et al. Interferon plus ribavirin in patients with hepatitis C virus positive mixed cryoglobulinemia resistant to interferon. *J Rheumatol* 2003;30:1775–81.
- [37] Pietrogrande M, De Vita S, Zignego AL, Pioltelli P, Sansonno D, Sollima S, et al. Recommendations for the management of mixed cryoglobulinemia syndrome in hepatitis C virus-infected patients. *Autoimmun Rev* 2011;10:444–54.
- [38] Saadoun D, Resche Rigon M, Pol S, Thibault V, Blanc F, Pialoux G, et al. PegIFNalpha/ribavirin/protease inhibitor combination in severe hepatitis C virus-associated mixed cryoglobulinemia vasculitis. *J Hepatol* 2015;62:24–30.
- [39] Gragnani L, Fabbri A, Triboli E, Urraro T, Boldrini B, Fognani E, et al. Triple antiviral therapy in hepatitis C virus infection with or without mixed cryoglobulinemia: a prospective, controlled pilot study. *Dig Liver Dis* 2014;46:833–7.
- [40] Stine JG, Cornella S, Shah NL. Treatment of chronic hepatitis C complicated by mixed cryoglobulinemia with new protease inhibitor, sofosbuvir. *Ann Rheum Dis* 2014;73:e64.
- [41] Cornella SL, Stine JG, Kelly V, Caldwell SH, Shah NL. Persistence of mixed cryoglobulinemia despite cure of hepatitis C with new oral antiviral therapy including direct-acting antiviral sofosbuvir: a case series. *Postgrad Med* 2015;127:413–7.
- [42] Saadoun D, Thibault V, Si Ahmed SN, Alric L, Mallet M, Guillaud C, et al. Sofosbuvir plus ribavirin for hepatitis C virus-associated cryoglobulinemia vasculitis: VASCUVALDIC study. *Ann Rheum Dis* 2015.
- [43] Sise ME, Bloom AK, Wisocky J, Lin MV, Gustafson JL, Lundquist AL, et al. Treatment of hepatitis C virus-associated mixed cryoglobulinemia with direct-acting antiviral agents. *Hepatology* 2016;63:408–17.
- [44] Gragnani L, Piluso A, Urraro T, Fabbri A, Fognani E, Petracchia L, et al. Virological and clinical response to interferon-free regimens in patients with HCV-related mixed cryoglobulinemia: preliminary results of a prospective pilot study. *Curr Drug Targets* 2016.
- [45] Gragnani L, Piluso A, Urraro T, Fabbri A, Fognani E, Petracchia L, et al. Virological and clinical response in patients with HCV-related mixed cryoglobulinemia treated with interferon-free regimens: preliminary results of a prospective pilot study. *Hepatology* 2015;62:798a–a.
- [46] Gragnani L, Visentini M, Fognani E, Urraro T, De Santis A, Petracchia L, et al. Prospective study of guideline-tailored therapy with direct-acting antivirals for hepatitis C virus-associated mixed cryoglobulinemia. *Hepatology* 2016;64:1473–82.
- [47] Bonacci M, Lens S, Londono MC, Marino Z, Cid MC, Ramos-Casals M, et al. Virologic, clinical, and immune response outcomes of patients with hepatitis C virus-associated cryoglobulinemia treated with direct-acting antivirals. *Clin Gastroenterol Hepatol* 2016.
- [48] Hegazy MT, Hussein MA, Quartuccio L, Fawzy M, Zoheir N, Ellawindi MI, et al. Treatment of cryoglobulinemic vasculitis with sofosbuvir in four combination protocols. *Arthritis Rheum* 2016;68(Suppl. 10).
- [49] Kondili LA WL, Mallano A, Fucili L, Massella M, Vinci M, et al. HCV-related mixed cryoglobulinemia: data from PITER, a nationwide Italian HCV cohort study. *J Hepatol* 2016;S618.
- [50] Mazzaro C, Panarello G, Carniello S, Faelli A, Mazzi G, Crovatto M, et al. Interferon versus steroids in patients with hepatitis C virus-associated cryoglobulinemic glomerulonephritis. *Dig Liver Dis* 2000;32:708–15.
- [51] Dammacco F, Sansonno D, Han JH, Shyamala V, Cornacchiolo V, Iacobelli AR, et al. Natural interferon-alpha versus its combination with 6-methyl-prednisolone in the therapy of type II mixed cryoglobulinemia: a long-term, randomized, controlled study. *Blood* 1994;84:3336–43.
- [52] Vacca A, Felli MP, Farina AR, Martinotti S, Maroder M, Screpanti I, et al. Glucocorticoid receptor-mediated suppression of the interleukin 2 gene expression through impairment of the cooperativity between nuclear factor of activated T cells and AP-1 enhancer elements. *J Exp Med* 1992;175:637–46.
- [53] De Vecchi A, Montagnino G, Pozzi C, Tarantino A, Locatelli F, Ponticelli C. Intravenous methylprednisolone pulse therapy in essential mixed cryoglobulinemia nephropathy. *Clin Nephrol* 1983;19:221–7.
- [54] Caviglia AG, Monti G, Navassa G, Colzani M, Gomitoni A, Villa P, et al. Chronic-relapsing polyneuropathy in the course of cryoglobulinemia. Clinical aspects and plasmapheresis treatment. *Ric Clin Lab* 1986;16:385–7.
- [55] Pioltelli P, Maldifassi P, Vacca A, Mazzaro C, Mussini C, Migliaresi S, et al. GISC protocol experience in the treatment of essential mixed cryoglobulinemia. *Clin Exp Rheumatol* 1995;13(Suppl. 13):S187–90.

- [56] Ferri C, Sebastiani M, Giuggioli D, Cazzato M, Longombardo G, Antonelli A, et al. Mixed cryoglobulinemia: demographic, clinical, and serologic features and survival in 231 patients. *Semin Arthritis Rheum* 2004;33:355–74.
- [57] Terrier B, Semoun O, Saadoun D, Sene D, Resche-Rigon M, Cacoub P. Prognostic factors in patients with hepatitis C virus infection and systemic vasculitis. *Arthritis Rheum* 2011;63:1748–57.
- [58] Monti G, Saccardo F, Rinaldi G, Petrozzino MR, Gomitoni A, Invernizzi F. Colchicine in the treatment of mixed cryoglobulinemia. *Clin Exp Rheumatol* 1995;13(Suppl. 13):S197–9.
- [59] Invernizzi F, Monti G. Colchicine and mixed cryoglobulinemia. *Arthritis Rheum* 1993;36:722–3.
- [60] Ferri C, Pietrogrande M, Cecchetti R, Tavoni A, Cefalo A, Buzzetti G, et al. Low-antigen-content diet in the treatment of patients with mixed cryoglobulinemia. *Am J Med* 1989;87:519–24.
- [61] Urraro T, Gragnani L, Piluso A, Fabbrizzi A, Monti M, Fognani E, et al. Combined treatment with antiviral therapy and rituximab in patients with mixed cryoglobulinemia: review of the literature and report of a case using direct antiviral agents-based antihepatitis C virus therapy. *Case Rep Immunol* 2015;2015:816424.
- [62] Zaja F, De Vita S, Mazzaro C, Sacco S, Damiani D, De Marchi G, et al. Efficacy and safety of rituximab in type II mixed cryoglobulinemia. *Blood* 2003;101:3827–34.
- [63] Sansonno D, De Re V, Lauletta G, Tucci FA, Boiocchi M, Dammacco F. Monoclonal antibody treatment of mixed cryoglobulinemia resistant to interferon alpha with an anti-CD20. *Blood* 2003;101:3818–26.
- [64] Roccatello D, Baldovino S, Rossi D, Mansouri M, Naretto C, Gennaro M, et al. Long-term effects of anti-CD20 monoclonal antibody treatment of cryoglobulinaemic glomerulonephritis. *Nephrol Dial Transplant* 2004;19:3054–61.
- [65] Visentini M, Granata M, Veneziano ML, Borghese F, Carlesimo M, Pimpinelli F, et al. Efficacy of low-dose rituximab for mixed cryoglobulinemia. *Clin Immunol* 2007;125:30–3.
- [66] Quartuccio L, Soardo G, Romano G, Zaja F, Scott CA, De Marchi G, et al. Rituximab treatment for glomerulonephritis in HCV-associated mixed cryoglobulinaemia: efficacy and safety in the absence of steroids. *Rheumatology (Oxford)* 2006;45:842–6.
- [67] Pekow J, Chung RT. Treatment of type II cryoglobulinemia associated with hepatitis C with rituximab. *J Clin Gastroenterol* 2006;40:450.
- [68] Basse G, Ribes D, Kamar N, Mehrenberger M, Esposito L, Guitard J, et al. Rituximab therapy for de novo mixed cryoglobulinemia in renal transplant patients. *Transplantation* 2005;80:1560–4.
- [69] Quartuccio L, Petrarca A, Mansutti E, Pieroni S, Calcabrini L, Avellini C, et al. Efficacy of rituximab in severe and mild abdominal vasculitis in the course of mixed cryoglobulinemia. *Clin Exp Rheumatol* 2010;28:84–7.
- [70] Terrier B, Saadoun D, Sene D, Sellam J, Perard L, Coppere B, et al. Efficacy and tolerability of rituximab with or without PEGylated interferon alfa-2b plus ribavirin in severe hepatitis C virus-related vasculitis: a long-term followup study of thirty-two patients. *Arthritis Rheum* 2009;60:2531–40.
- [71] Lamprecht P, Lerin-Lozano C, Merz H, Dennin RH, Gause A, Voswinkel J, et al. Rituximab induces remission in refractory HCV associated cryoglobulinaemic vasculitis. *Ann Rheum Dis* 2003;62:1230–3.
- [72] Bestard O, Cruzado JM, Ercilla G, Goma M, Torras J, Seron D, et al. Rituximab induces regression of hepatitis C virus-related membranoproliferative glomerulonephritis in a renal allograft. *Nephrol Dial Transplant* 2006;21:2320–4.
- [73] Korte MR, van Heerde MJ, de Man RA, Betjes MH. Rituximab for the treatment of glomerulonephritis in hepatitis C associated cryoglobulinaemia. *Neth J Med* 2008;66:27–30.
- [74] Evans JT, Shepard MM, Oates JC, Self SE, Reuben A. Rituximab-responsive cryoglobulinemic glomerulonephritis in a patient with autoimmune hepatitis. *J Clin Gastroenterol* 2008;42:862–3.
- [75] Cavallo R, Roccatello D, Menegatti E, Naretto C, Napoli F, Baldovino S. Rituximab in cryoglobulinemic peripheral neuropathy. *J Neurol* 2009;256:1076–82.
- [76] Braun A, Neumann T, Oelzner P, Hein G, Grone HJ, Ziemer M, et al. Cryoglobulinaemia type III with severe neuropathy and immune complex glomerulonephritis: remission after plasmapheresis and rituximab. *Rheumatol Int* 2008;28:503–6.
- [77] Petrarca A, Rigacci L, Monti M, Giannini C, Bernardi F, Caini P, et al. Improvement in liver cirrhosis after treatment of HCV-related mixed cryoglobulinemia with rituximab. *Dig Liver Dis* 2007;39(Suppl. 1):S129–33.
- [78] Petrarca A, Rigacci L, Caini P, Colagrande S, Romagnoli P, Vizzutti F, et al. Safety and efficacy of rituximab in patients with hepatitis C virus-related mixed cryoglobulinemia and severe liver disease. *Blood* 2010;116:335–42.
- [79] Cabibbo S, Antolino A, Garozzo G, Manenti GO, Bonomo P. Clinical improvement induced by rituximab in two cases of type II mixed cryoglobulinaemia syndrome unresponsive to conventional treatments. *Blood Transfus* 2010;8:196–8.
- [80] Uppal R, Charles E, Lake-Bakaar G. Acute wrist and foot drop associated with hepatitis C virus related mixed cryoglobulinemia: rapid response to treatment with rituximab. *J Clin Virol* 2010;47:69–71.
- [81] Visentini M, Tinelli C, Colantuono S, Monti M, Ludovisi S, Gragnani L, et al. Efficacy of low-dose rituximab for the treatment of mixed cryoglobulinemia vasculitis: phase II clinical trial and systematic review. *Autoimmun Rev* 2015;14:889–96.
- [82] Saadoun D, Rosenzweig M, Landau D, Piette JC, Klatzmann D, Cacoub P. Restoration of peripheral immune homeostasis after rituximab in mixed cryoglobulinemia vasculitis. *Blood* 2008;111:5334–41.
- [83] De Vita S, Quartuccio L. Rituximab monotherapy, rather than rituximab plus antiviral drugs, for initial treatment of severe hepatitis C virus-associated mixed cryoglobulinemia syndrome: comment on the article by Terrier et al. *Arthritis Rheum* 2010;62:908–9 [author reply 9].
- [84] De Vita S, Quartuccio L, Fabris M. Hepatitis C virus infection, mixed cryoglobulinemia and BlyS upregulation: targeting the infectious trigger, the autoimmune response, or both? *Autoimmun Rev* 2008;8:95–9.
- [85] Saadoun D, Resche-Rigon M, Sene D, Terrier B, Karras A, Perard L, et al. Rituximab plus Peg-interferon-alpha/ribavirin compared with Peg-interferon-alpha/ribavirin in hepatitis C-related mixed cryoglobulinemia. *Blood* 2010;116:326–34 [quiz 504–5].
- [86] Dammacco F, Tucci FA, Lauletta G, Gatti P, De Re V, Conteduca V, et al. Pegylated interferon-alpha, ribavirin, and rituximab combined therapy of hepatitis C virus-related mixed cryoglobulinemia: a long-term study. *Blood* 2010;116:343–53.
- [87] Ignatova T, Chernova O, Novikov P, Moiseev S. HCV-associated cryoglobulinaemic vasculitis: triple/dual antiviral treatment and/or rituximab? *Ann Rheum Dis* 2014;73:e58.
- [88] Saadoun D, Cacoub P. HCV-associated cryoglobulinemic vasculitis: triple/dual antiviral treatment and/or rituximab? Reply to the comment by Ignatova et al. *Ann Rheum Dis* 2014;73:e59.
- [89] Ferri C, La Civita L, Caracciolo F, Zignego AL. Non-Hodgkin's lymphoma: possible role of hepatitis C virus [letter]. *JAMA* 1994;272:355–6.
- [90] Ferri C, Caracciolo F, Zignego AL, La Civita L, Monti M, Longombardo G, et al. Hepatitis C virus infection in patients with non-Hodgkin's lymphoma. *Br J Haematol* 1994;88:392–4.
- [91] Zuckerman E, Zuckerman T, Levine AM, Douer D, Gutekunst K, Mizokami M, et al. Hepatitis C virus infection in patients with B-cell non-Hodgkin lymphoma. *Ann Intern Med* 1997;127:423–8.
- [92] de Sanjose S, Benavente Y, Vajdic CM, Engels EA, Morton LM, Bracci PM, et al. Hepatitis C and non-Hodgkin lymphoma among 4784 cases and 6269 controls from the International Lymphoma Epidemiology Consortium. *Clin Gastroenterol Hepatol* 2008;6:451–8.
- [93] Hausfater P, Cacoub P, Sterkers Y, Thibault V, Amoura Z, Nguyen L, et al. Hepatitis C virus infection and lymphoproliferative diseases: prospective study on 1,576 patients in France. *Am J Hematol* 2001;67:168–71.
- [94] Gisbert JP, Garcia-Buey L, Pajares JM, Moreno-Otero R. Prevalence of hepatitis C virus infection in B-cell non-Hodgkin's lymphoma: systematic review and meta-analysis. *Gastroenterology* 2003;125:1723–32.
- [95] Matsuo K, Kusano A, Sugumar A, Nakamura S, Tajima K, Mueller NE. Effect of hepatitis C virus infection on the risk of non-Hodgkin's lymphoma: a meta-analysis of epidemiological studies. *Cancer Sci* 2004;95:745–52.
- [96] Negri E, Little D, Boiocchi M, La Vecchia C, Franceschi S. B-cell non-Hodgkin's lymphoma and hepatitis C virus infection: a systematic review. *Int J Cancer* 2004;111:1–8.
- [97] Dal Maso L, Franceschi S. Hepatitis C virus and risk of lymphoma and other lymphoid neoplasms: a meta-analysis of epidemiologic studies. *Cancer Epidemiol Biomarkers Prev* 2006;15:2078–85.
- [98] Mele A, Pulsoni A, Bianco E, Musto P, Szklo A, Sanpaolo MG, et al. Hepatitis C virus and B-cell non-Hodgkin lymphomas: an Italian multicenter case-control study. *Blood* 2003;102:996–9.
- [99] Marcucci F, Mele A. Hepatitis viruses and non-Hodgkin lymphoma: epidemiology, mechanisms of tumorigenesis, and therapeutic opportunities. *Blood* 2011;117:1792–8.
- [100] Hermine O, Lefrere F, Bronowicki JP, Mariette X, Jondeau K, Eclache-Saudreau V, et al. Regression of splenic lymphoma with villous lymphocytes after treatment of hepatitis C virus infection. *N Engl J Med* 2002;347:89–94.
- [101] Merli M, Carli G, Arcaini L, Visco C. Antiviral therapy of hepatitis C as curative treatment of indolent B-cell lymphoma. *World J Gastroenterol* 2016;22:8447–58.
- [102] Arcaini L, Rossi D, Paulli M. Splenic marginal zone lymphoma: from genetics to management. *Blood* 2016;127:2072–81.
- [103] Torres HA, Mahale P. Most patients with HCV-associated lymphoma present with mild liver disease: a call to revise antiviral treatment prioritization. *Liver Int* 2015;35:1661–4.
- [104] Dreyling M, Thieblemont C, Galloway A, Arcaini L, Campo E, Hermine O, et al. ESMO Consensus conferences: guidelines on malignant lymphoma. part 2: marginal zone lymphoma, mantle cell lymphoma, peripheral T-cell lymphoma. *Ann Oncol* 2013;24:857–77.
- [105] Zelenetz AD, Wierda WG, Abramson JS, Advani RH, Andreadis CB, Bartlett N, et al. Non-Hodgkin's lymphomas, version 1.2013. *J Natl Compr Canc Netw* 2013;11:257–72; [quiz 73].
- [106] EASL. Clinical practice guidelines: management of hepatitis C virus infection. *J Hepatol* 2014;60:392–420.
- [107] Merli M, Visco C, Spina M, Luminari S, Ferretti VV, Gotti M, et al. Outcome prediction of diffuse large B-cell lymphomas associated with hepatitis C virus infection: a study on behalf of the Fondazione Italiana Linfomi. *Haematologica* 2014;99:489–96.
- [108] Tilly H, Gomes da Silva M, Vitolo U, Jack A, Meignan M, Lopez-Guillermo A, et al. Diffuse large B-cell lymphoma (DLBCL): ESMO Clinical Practice Guidelines for diagnosis, treatment and follow-up. *Ann Oncol* 2015;26(Suppl. 5):v116–25.
- [109] Ennishi D, Maeda Y, Niitsu N, Kojima M, Izutsu K, Takizawa J, et al. Hepatic toxicity and prognosis in hepatitis C virus-infected patients with diffuse large B-cell lymphoma treated with rituximab-containing chemotherapy regimens: a Japanese multicenter analysis. *Blood* 2010;116:5119–25.
- [110] Musto P, Dell'Olivo M, La Sala A, Mantuano S, Cascavilla N. Diffuse B-large cell lymphomas (DLBCL) with hepatitis-C virus (HCV) infection: clinical outcome and preliminary results of a pilot study combining R-CHOP with antiviral therapy. *Blood* 2005;106:688a–a.
- [111] Michot JM, Canioni D, Driss H, Alric L, Cacoub P, Suarez F, et al. Antiviral therapy is associated with a better survival in patients with hepatitis C virus and B-cell non-Hodgkin lymphomas, ANRS HC-13 lympho-C study. *Am J Hematol* 2015;90:197–203.

- [112] Carrier P, Jaccard A, Jacques J, Tabouret T, Debette-Gratien M, Abraham J, et al. HCV-associated B-cell non-Hodgkin lymphomas and new direct antiviral agents. *Liver Int* 2015;35:2222–7.
- [113] Kyvernitakis A, Mahale P, Popat UR, Jiang Y, Hosry J, Champlin RE, et al. Hepatitis C virus infection in patients undergoing hematopoietic cell transplantation in the era of direct-acting antiviral agents. *Biol Blood Marrow Transplant* 2016;22:717–22.
- [114] Locasciulli A, Bruno B, Alessandrino EP, Meloni G, Arcese W, Bandini G, et al. Hepatitis reactivation and liver failure in haemopoietic stem cell transplants for hepatitis B virus (HBV)/hepatitis C virus (HCV) positive recipients: a retrospective study by the Italian group for blood and marrow transplantation. *Bone Marrow Transplant* 2003;31:295–300.
- [115] Varma A, Saliba RM, Torres HA, Afrough A, Hosing C, Khouri IF, et al. Outcomes in hepatitis C virus seropositive lymphoma and myeloma patients after autologous stem cell transplantation. *Bone Marrow Transplant* 2016.
- [116] Butt AA, Wang X, Fried LF. HCV infection and the incidence of CKD. *Am J Kidney Dis* 2011;57:396–402.
- [117] Fabrizi F, Poordad FF, Martin P. Hepatitis C infection and the patient with end-stage renal disease. *Hepatology* 2002;36:3–10.
- [118] El-Serag HB, Hampel H, Yeh C, Rabeneck L. Extrahepatic manifestations of hepatitis C among United States male veterans. *Hepatology* 2002;36:1439–45.
- [119] Dalrymple LS, Koepsell T, Sampson J, Louie T, Dominitz JA, Young B, et al. Hepatitis C virus infection and the prevalence of renal insufficiency. *Clin J Am Soc Nephrol* 2007;2:715–21.
- [120] Wyatt CM, Malvestutto C, Coca SG, Klotman PE, Parikh CR. The impact of hepatitis C virus coinfection on HIV-related kidney disease: a systematic review and meta-analysis. *AIDS* 2008;22:1799–807.
- [121] Lee JJ, Lin MY, Yang YH, Lu SN, Chen HC, Hwang SJ. Association of hepatitis C and B virus infection with CKD in an endemic area in Taiwan: a cross-sectional study. *Am J Kidney Dis* 2010;56:23–31.
- [122] Roccatello D, Fornasieri A, Giachino O, Rossi D, Beltrame A, Banfi G, et al. Multicenter study on hepatitis C virus-related cryoglobulinemic glomerulonephritis. *Am J Kidney Dis* 2007;49:69–82.
- [123] Alpers C, Bloom RD, Fabrizi F, Izopet J, Jadoul M, Lindley E, et al. KDIGO clinical practice guidelines for the prevention, diagnosis, evaluation, and treatment of hepatitis C in chronic kidney disease - introduction. *Kidney Int* 2008;73:S6–S99.
- [124] Cacoub P, Desbois AC, Isnard-Bagnis C, Roccatello D, Ferri C. Hepatitis C virus infection and chronic kidney disease: time for reappraisal. *J Hepatol* 2016;65: S82–94.
- [125] Scarpato S, Tirri E, Naclerio C, Moscato P, Salvati G. Plasmapheresis in cryoglobulinemic neuropathy: a clinical study. *Dig Liver Dis* 2007;39(Suppl. 1):S136–7.
- [126] Sene D, Ghillani-Dalbin P, Amoura Z, Musset L, Cacoub P. Rituximab may form a complex with IgMkappa mixed cryoglobulin and induce severe systemic reactions in patients with hepatitis C virus-induced vasculitis. *Arthritis Rheum* 2009;60: 3848–55.
- [127] Roccatello D, Sciascia S, Baldovino S, Rossi D, Alpa M, Naretto C, et al. Improved (4 Plus 2) rituximab protocol for severe cases of mixed cryoglobulinemia: a 6-year observational study. *Am J Nephrol* 2016;43:251–60.
- [128] Ye J, Wang C, Sumpter Jr R, Brown MS, Goldstein JL, Gale Jr M. Disruption of hepatitis C virus RNA replication through inhibition of host protein geranylgeranylation. *Proc Natl Acad Sci U S A* 2003;100:15865–70.
- [129] Ashrafi M, Modabbernia A, Dalir M, Taslimi S, Karami M, Ostovaneh MR, et al. Predictors of mental and physical health in non-cirrhotic patients with viral hepatitis: a case control study. *J Psychosom Res* 2012;73:218–24.
- [130] Sockalingam S, Abbey SE, Alosaimi F, Novak M. A review of sleep disturbance in hepatitis C. *J Clin Gastroenterol* 2010;44:38–45.
- [131] Poynard T, Cacoub P, Ratzin V, Myers RP, Dezailles MH, Mercadier A, et al. Fatigue in patients with chronic hepatitis C. *J Viral Hepat* 2002;9:295–303.
- [132] Monaco S, Mariotto S, Ferrari S, Calabrese M, Zanusso G, Gajofatto A, et al. Hepatitis C virus-associated neurocognitive and neuropsychiatric disorders: advances in 2015. *World J Gastroenterol* 2015;21:11974–83.
- [133] Kallman J, O'Neil MM, Larive B, Boparai N, Calabrese L, Younossi ZM. Fatigue and health-related quality of life (HRQL) in chronic hepatitis C virus infection. *Dig Dis Sci* 2007;52:2531–9.
- [134] Solinas A, Piras MR, Deplano A. Cognitive dysfunction and hepatitis C virus infection. *World J Hepatol* 2015;7:922–5.
- [135] Lowry D, Coughlan B, McCarthy O, Crowe J. Investigating health-related quality of life, mood and neuropsychological test performance in a homogeneous cohort of Irish female hepatitis C patients. *J Viral Hepat* 2010;17:352–9.
- [136] Forton DM, Thomas HC, Murphy CA, Allsop JM, Foster GR, Main J, et al. Hepatitis C and cognitive impairment in a cohort of patients with mild liver disease. *Hepatology* 2002;35:433–9.
- [137] McAndrews MP, Farcnik K, Carlen P, Damyanovich A, Mrkonjic M, Jones S, et al. Prevalence and significance of neurocognitive dysfunction in hepatitis C in the absence of correlated risk factors. *Hepatology* 2005;41:801–8.
- [138] Wilkinson J, Radkowski M, Laskus T. Hepatitis C virus neuroinvasion: identification of infected cells. *J Virol* 2009;83:1312–9.
- [139] Schaefer M, Capuron L, Friebe A, Diez-Quevedo C, Robaey G, Neri S, et al. Hepatitis C infection, antiviral treatment and mental health: a European expert consensus statement. *J Hepatol* 2012;57:1379–90.
- [140] Laskus T, Radkowski M, Adair DM, Wilkinson J, Scheck AC, Rakela J. Emerging evidence of hepatitis C virus neuroinvasion. *AIDS* 2005;19(Suppl. 3):S140–4.
- [141] Martinez RM, Zarpelon AC, Cardoso RD, Vicentini FT, Georgetti SR, Baracat MM, et al. Tephrosia sinapou ethyl acetate extract inhibits inflammatory pain in mice: opioid receptor dependent inhibition of TNFalpha and IL-1beta production. *Pharm Biol* 2013;51:1262–71.
- [142] Palin K, Bluth RM, McCusker RH, Moos F, Dantzer R, Kelley KW. TNFalpha-induced sickness behavior in mice with functional 55 kD TNF receptors is blocked by central IGF-I. *J Neuroimmunol* 2007;187:55–60.
- [143] Cozzi A, Zignego AL, Carpando R, Biagiotti T, Aldinucci A, Monti M, et al. Low serum tryptophan levels, reduced macrophage IDO activity and high frequency of psychopathology in HCV patients. *J Viral Hepat* 2006;13:402–8.
- [144] Casato M, Saadoun D, Marchetti A, Limal N, Picq C, Pantano P, et al. Central nervous system involvement in hepatitis C virus cryoglobulinemia vasculitis: a multicenter case-control study using magnetic resonance imaging and neuropsychological tests. *J Rheumatol* 2005;32:484–8.
- [145] Bonkovsky HL, Woolley JM. Reduction of health-related quality of life in chronic hepatitis C and improvement with interferon therapy. The Consensus Interferon Study Group. *Hepatology* 1999;29:264–70.
- [146] Bonkovsky HL, Snow KK, Malet PF, Back-Madruga C, Fontana RJ, Sterling RK, et al. Health-related quality of life in patients with chronic hepatitis C and advanced fibrosis. *J Hepatol* 2007;46:420–31.
- [147] Kang SC, Hwang SJ, Lee SH, Chang FY, Lee SD. Health-related quality of life and impact of antiviral treatment in Chinese patients with chronic hepatitis C in Taiwan. *World J Gastroenterol* 2005;11:7494–8.
- [148] Younossi Z, Kallman J, Kincaid J. The effects of HCV infection and management on health-related quality of life. *Hepatology* 2007;45:806–16.
- [149] McHutchison JG, Ware Jr JE, Bayliss MS, Pianko S, Albrecht JK, Cort S, et al. The effects of interferon alpha-2b in combination with ribavirin on health related quality of life and work productivity. *J Hepatol* 2001;34:140–7.
- [150] Spiegel BM, Younossi ZM, Hays RD, Revicki D, Robbins S, Kanwal F. Impact of hepatitis C on health related quality of life: a systematic review and quantitative assessment. *Hepatology* 2005;41:790–800.
- [151] Raison CL, Borisov AS, Broadwell SD, Capuron L, Woolwine BJ, Jacobson IM, et al. Depression during pegylated interferon-alpha plus ribavirin therapy: prevalence and prediction. *J Clin Psychiatry* 2005;66:41–8.
- [152] Vignau J, Karila L, Costisella O, Canva V. Hepatitis C, interferon and depression: main physiopathologic hypothesis. *Encéphale* 2005;31:349–57.
- [153] Hauser P, Khosla J, Aurora H, Laurin J, Kling MA, Hill J, et al. A prospective study of the incidence and open-label treatment of interferon-induced major depressive disorder in patients with hepatitis C. *Mol Psychiatry* 2002;7:942–7.
- [154] Younossi ZM, Stepanova M, Zeuzem S, Dusheiko G, Esteban R, Hezode C, et al. Patient-reported outcomes assessment in chronic hepatitis C treated with sofosbuvir and ribavirin: the VALENCE study. *J Hepatol* 2014;61:228–34.
- [155] Modabbernia A, Poustchi H, Malekzadeh R. Neuropsychiatric and psychosocial issues of patients with hepatitis C infection: a selective literature review. *Hepat Mon* 2013;13:e8340.
- [156] Isaacs D, Abdelaziz N, Keller M, Tibble J, Haq I. Measuring the response of extrahepatic symptoms and quality of life to antiviral treatment in patients with hepatitis C. *Hepat Res Treat* 2013;2013:910519.
- [157] Younossi ZM, Stepanova M, Marcellin P, Afdhal N, Kowdley KV, Zeuzem S, et al. Treatment with ledipasvir and sofosbuvir improves patient-reported outcomes: results from the ION-1, -2, and -3 clinical trials. *Hepatology* 2015;61: 1798–808.
- [158] Younossi Z, Henry L. Systematic review: patient-reported outcomes in chronic hepatitis C—the impact of liver disease and new treatment regimens. *Aliment Pharmacol Ther* 2015;41:497–520.
- [159] Rowan PJ, Bhulani N. Psychosocial assessment and monitoring in the new era of non-interferon-alpha hepatitis C virus treatments. *World J Hepatol* 2015;7: 2209–13.
- [160] Cacoub P, Poynard T, Ghillani P, Charlotte F, Olivi M, Piette JC, et al. Extrahepatic manifestations of chronic hepatitis C. MULTIVIRC Group. Multidepartment Virus C. *Arthritis Rheum* 1999;42:2204–12.
- [161] Fernandez I, Castellano G, de Salamanca RE, Colina F, Gomez de la Camara A, Moran MJ, et al. Porphyria cutanea tarda as a predictor of poor response to interferon alpha therapy in chronic hepatitis C. *Scand J Gastroenterol* 2003;38:314–9.
- [162] Desai TK, Jamil LH, Balasubramaniam M, Koff R, Bonkovsky HL. Phlebotomy improves therapeutic response to interferon in patients with chronic hepatitis C: a meta-analysis of six prospective randomized controlled trials. *Dig Dis Sci* 2008; 53:815–22.
- [163] Garcovich S, Garcovich M, Capizzi R, Gasbarrini A, Zocco MA. Cutaneous manifestations of hepatitis C in the era of new antiviral agents. *World J Hepatol* 2015;7: 2740–8.
- [164] Gisbert JP, Garcia-Buey L, Pajares JM, Moreno-Otero R. Prevalence of hepatitis C virus infection in porphyria cutanea tarda: systematic review and meta-analysis. *J Hepatol* 2003;39:620–7.
- [165] Azim J, McCurdy H, Moseley RH. Porphyria cutanea tarda as a complication of therapy for chronic hepatitis C. *World J Gastroenterol* 2008;14:5913–5.
- [166] Le Cleach L, Chosidow O. Clinical practice. Lichen planus. *N Engl J Med* 2012;366: 723–32.
- [167] Shengyuan L, Songpo Y, Wen W, Wenjing T, Haitao Z, Binyou W. Hepatitis C virus and lichen planus: a reciprocal association determined by a meta-analysis. *Arch Dermatol* 2009;145:1040–7.
- [168] Carbone T, Nasorri F, Pennino D, Donnarumma M, Garcovich S, Eyerich K, et al. CD56 highCD16 - NK cell involvement in cutaneous lichen planus. *Eur J Dermatol* 2010;20:724–30.
- [169] Sontheimer RD. Lichenoid tissue reaction/interface dermatitis: clinical and histological perspectives. *J Invest Dermatol* 2009;129:1088–99.
- [170] Dalekos GN, Christodoulou D, Kistis KG, Zervou EK, Hatzis J, Tsianos EV. A prospective evaluation of dermatological side-effects during alpha-interferon therapy for chronic viral hepatitis. *Eur J Gastroenterol Hepatol* 1998;10:933–9.

- [171] Manousaridis I, Manousaridis K, Peitsch WK, Schneider SW. Individualizing treatment and choice of medication in lichen planus: a step by step approach. *J Dtsch Dermatol Ges* 2013;11:981–91.
- [172] Cheng S, Kirtschig G, Cooper S, Thornhill M, Leonardi-Bee J, Murphy R. Interventions for erosive lichen planus affecting mucosal sites. *Cochrane Database Syst Rev* 2012;CD008092.
- [173] Fallahi P, Ferrari SM, Politti U, Giuggioli D, Ferri C, Antonelli A. Autoimmune and neoplastic thyroid diseases associated with hepatitis C chronic infection. *Int J Endocrinol* 2014;2014:935131.
- [174] Shen Y, Wang XL, Xie JP, Shao JG, Lu YH, Zhang S, et al. Thyroid disturbance in patients with chronic hepatitis C infection: a systematic review and meta-analysis. *J Gastrointest Liver Dis* 2016;25:227–34.
- [175] Fallahi P, Ferrari SM, Ruffilli I, Elia G, Giuggioli D, Colaci M, et al. Incidence of thyroid disorders in mixed cryoglobulinemia: results from a longitudinal follow-up. *Autoimmun Rev* 2016;15:747–51.
- [176] Mao XR, Zhang LT, Chen H, Xiao P, Zhang YC. Possible factors affecting thyroid dysfunction in hepatitis C virus-infected untreated patients. *Exp Ther Med* 2014;8:133–40.
- [177] Antonelli A, Ferri C, Fallahi P. Hepatitis C: thyroid dysfunction in patients with hepatitis C on IFN-alpha therapy. *Nat Rev Gastroenterol Hepatol* 2009;6:633–5.
- [178] Mammen JS, Ghazarian SR, Rosen A, Ladenson PW. Patterns of interferon-alpha-induced thyroid dysfunction vary with ethnicity, sex, smoking status, and pretreatment thyrotropin in an international cohort of patients treated for hepatitis C. *Thyroid* 2013;23:1151–8.
- [179] Czarnywojtek A, Zgorzalewicz-Stachowiak M, Wasko R, Czepczynski R, Szczepanek-Parulska E, Waligorska-Stachura J, et al. Patients with chronic hepatitis type C and interferon-alpha-induced hyperthyroidism in two-years clinical follow-up. *Neuro Endocrinol Lett* 2013;34:154–61.
- [180] Minelli R, Spagnoli F, Marchesi E, Venturi N, Marina M, Orlandini A, et al. Course of graves disease in interferon-treated patients with chronic hepatitis C virus infection and in uninfected patients. *J Invest Med* 2013;61:1173–7.
- [181] Nair Kesavachandran C, Haamann F, Nienhaus A. Frequency of thyroid dysfunctions during interferon alpha treatment of single and combination therapy in hepatitis C virus-infected patients: a systematic review based analysis. *PLoS One* 2013;8:e55364.
- [182] Antonelli A, Ferri C, Fallahi P, Ferrari SM, Frascerra S, Sebastiani M, et al. High values of CXCL10 serum levels in patients with hepatitis C associated mixed cryoglobulinemia in presence or absence of autoimmune thyroiditis. *Cytokine* 2008;42:137–43.
- [183] Zhang RW, Shao CP, Huo N, Li MR, Xi HL, Yu M, et al. Thyroid dysfunction in Chinese hepatitis C patients: prevalence and correlation with TPOAb and CXCL10. *World J Gastroenterol* 2015;21:9765–73.
- [184] El Raziky M, Fathalah WF, Zakaria Z, Eldeen HG, Abul-Fotouh A, Salama A, et al. Predictors of virological response in 3,235 chronic HCV Egyptian patients treated with peginterferon alpha-2a compared with peginterferon alpha-2b using statistical methods and data mining techniques. *J Interferon Cytokine Res* 2016;36:338–46.
- [185] Vita R, Fallahi P, Antonelli A, Benvenega S. The administration of L-thyroxine as soft gel capsule or liquid solution. *Expert Opin Drug Deliv* 2014;11:1103–11.
- [186] Honer Zu Siederdisen C, Maasoumy B, Marra F, Deterding K, Port K, Manns MP, et al. Drug-drug interactions with novel all oral interferon-free antiviral agents in a large real-world cohort. *Clin Infect Dis* 2016;62:561–7.
- [187] Antonelli A, Ferrari SM, Corrado A, Di Domenicantonio A, Fallahi P. Autoimmune thyroid disorders. *Autoimmun Rev* 2015;14:174–80.
- [188] Mehta SH, Brancati FL, Sulkowski MS, Strathdee SA, Szklo M, Thomas DL. Prevalence of type 2 diabetes mellitus among persons with hepatitis C virus infection in the United States. *Ann Intern Med* 2000;133:592–9.
- [189] Younossi Z, Park H, Henry L, Adeyemi A, Stepanova M. Extrahepatic manifestations of hepatitis C: a meta-analysis of prevalence, quality of life, and economic burden. *Gastroenterology* 2016;150:1599–608.
- [190] Konishi I, Horiike N, Hiasa Y, Tokumoto Y, Mashiba T, Michitaka K, et al. Diabetes mellitus reduces the therapeutic effectiveness of interferon-alpha2b plus ribavirin therapy in patients with chronic hepatitis C. *Hepatol Res* 2007;37:331–6.
- [191] Elgouhari HM, Zein CO, Hanouneh I, Feldstein AE, Zein NN. Diabetes mellitus is associated with impaired response to antiviral therapy in chronic hepatitis C infection. *Dig Dis Sci* 2009;54:2699–705.
- [192] Saeed MJ, Olsen MA, Powderly WG, Presti RM. Diabetes mellitus is associated with higher risk of developing decompensated cirrhosis in chronic hepatitis C patients. *J Clin Gastroenterol* 2016.
- [193] Lai MS, Hsieh MS, Chiu YH, Chen TH. Type 2 diabetes and hepatocellular carcinoma: a cohort study in high prevalence area of hepatitis virus infection. *Hepatology* 2006;43:1295–302.
- [194] Bose SK, Ray R. Hepatitis C virus infection and insulin resistance. *World J Diabetes* 2014;5:52–8.
- [195] Romero-Gomez M, Del Mar Viloria M, Andrade RJ, Salmeron J, Diago M, Fernandez-Rodriguez CM, et al. Insulin resistance impairs sustained response rate to peginterferon plus ribavirin in chronic hepatitis C patients. *Gastroenterology* 2005;128:636–41.
- [196] Goossens N, Negro F. The impact of obesity and metabolic syndrome on chronic hepatitis C. *Clin Liver Dis* 2014;18:147–56.
- [197] Kralj D, Virovic Jukic L, Stojisavljevic S, Duvnjak M, Smolic M, Curcic IB. Hepatitis C virus, insulin resistance, and steatosis. *J Clin Transl Hepatol* 2016;4:66–75.
- [198] Domont F, Cacoub P. Chronic hepatitis C virus infection, a new cardiovascular risk factor? *Liver Int* 2016;36:621–7.
- [199] Crook ED, Penumalee S, Gavini B, Filippova K. Hepatitis C is a predictor of poorer renal survival in diabetic patients. *Diabetes Care* 2005;28:2187–91.
- [200] Konrad T, Zeuzem S, Vicini P, Toffolo G, Briem D, Lormann J, et al. Evaluation of factors controlling glucose tolerance in patients with HCV infection before and after 4 months therapy with interferon-alpha. *Eur J Clin Invest* 2000;30:111–21.
- [201] Vanni E, Bugianesi E, Saracco G. Treatment of type 2 diabetes mellitus by viral eradication in chronic hepatitis C: Myth or reality? *Dig Liver Dis* 2016;48:105–11.
- [202] Pashun RA, Shen NT, Jesudian A. Markedly improved glycemic control in poorly controlled type 2 diabetes following direct acting antiviral treatment of genotype 1 hepatitis C. *Case Rep Hepatol* 2016;2016:7807921.
- [203] Wynter J, Stine JG, Shah NL. Chronic hepatitis C and diabetes: more questions than answers with the new direct acting antiviral drugs? *Dig Liver Dis* 2016.
- [204] Younossi ZM, Stepanova M, Chan HL, Lee MH, Yu ML, Dan YY, et al. Patient-reported outcomes in Asian patients with chronic hepatitis C treated with ledipasvir and sofosbuvir. *Medicine (Baltimore)* 2016;95:e2702.
- [205] Pattullo V, Heathcote J. Hepatitis C and diabetes: one treatment for two diseases? *Liver Int* 2010;30:356–64.
- [206] Kita Y, Mizukoshi E, Takamura T, Sakurai M, Takata Y, Arai K, et al. Impact of diabetes mellitus on prognosis of patients infected with hepatitis C virus. *Metabolism* 2007;56:1682–8.
- [207] Bressler BL, Guindi M, Tomlinson G, Heathcote J. High body mass index is an independent risk factor for nonresponse to antiviral treatment in chronic hepatitis C. *Hepatology* 2003;38:639–44.
- [208] Gunton JE, Delhanty PJ, Takahashi S, Baxter RC. Metformin rapidly increases insulin receptor activation in human liver and signals preferentially through insulin-receptor substrate-2. *J Clin Endocrinol Metab* 2003;88:1323–32.
- [209] Knowler WC, Barrett-Connor E, Fowler SE, Hamman RF, Lachin JM, Walker EA, et al. Reduction in the incidence of type 2 diabetes with lifestyle intervention or metformin. *N Engl J Med* 2002;346:393–403.
- [210] Shaw RJ, Lamia KA, Vasquez D, Koo SH, Bardeesy N, Depinho RA, et al. The kinase LKB1 mediates glucose homeostasis in liver and therapeutic effects of metformin. *Science* 2005;310:1642–6.
- [211] Harris K, Smith L. Safety and efficacy of metformin in patients with type 2 diabetes mellitus and chronic hepatitis C. *Ann Pharmacother* 2013;47:1348–52.
- [212] O'Leary JG, Chan JL, McMahon CM, Chung RT. Atorvastatin does not exhibit antiviral activity against HCV at conventional doses: a pilot clinical trial. *Hepatology* 2007;45:895–8.
- [213] Henderson LM, Patel S, Giordano TP, Green L, El-Serag HB. Statin therapy and serum transaminases among a cohort of HCV-infected veterans. *Dig Dis Sci* 2010;55:190–5.
- [214] Toussiot E, Le Huede G, Mouglin C, Balblanc JC, Bettinger D, Wendling D. Presence of hepatitis C virus RNA in the salivary glands of patients with Sjogren's syndrome and hepatitis C virus infection. *J Rheumatol* 2002;29:2382–5.
- [215] Koike K, Moriya K, Ishibashi K, Yotsuyanagi H, Shintani Y, Fujie H, et al. Sialadenitis histologically resembling Sjogren syndrome in mice transgenic for hepatitis C virus envelope genes. *Proc Natl Acad Sci U S A* 1997;94:233–6.
- [216] Cacoub P, Renou C, Rosenthal E, Cohen P, Loury I, Loustaud-Ratti V, et al. Extrahepatic manifestations associated with hepatitis C virus infection. A prospective multicenter study of 321 patients. The GERMIVIC. Groupe d'Etude et de Recherche en Medecine Interne et Maladies Infectieuses sur le Virus de l'Hepatie C. *Medicine (Baltimore)* 2000;79:47–56.
- [217] Ramos-Casals M, Garcia-Carrasco M, Cervera R, Gaya J, Halperin I, Ubieta I, et al. Thyroid disease in primary Sjogren syndrome. Study in a series of 160 patients. *Medicine (Baltimore)* 2000;79:103–8.
- [218] Ferri C. Mixed cryoglobulinemia. *Orphanet J Rare Dis* 2008;3:25.
- [219] Doffoel-Hantz V, Loustaud-Ratti V, Ramos-Casals M, Alain S, Bezanahary H, Liozon E, et al. Evolution of Sjogren syndrome associated with hepatitis C virus when chronic hepatitis C is treated by interferon or the association of interferon and ribavirin. *Rev Med Interne* 2005;26:88–94.
- [220] Palazzi C, D'Amico E, D'Angelo S, Gilio M, Olivieri I. Rheumatic manifestations of hepatitis C virus chronic infection: Indications for a correct diagnosis. *World J Gastroenterol* 2016;22:1405–10.
- [221] Palazzi C, Olivieri I, D'Amico E, D'Agostino L, Nicolucci A, Pennese E, et al. Hepatitis C virus infection in psoriatic arthritis. *Arthritis Rheum* 2005;53:223–5.
- [222] Buskila D, Shnaider A, Neumann L, Lorber M, Zilberman D, Hilzenrat N, et al. Musculoskeletal manifestations and autoantibody profile in 90 hepatitis C virus infected Israeli patients. *Semin Arthritis Rheum* 1998;28:107–13.
- [223] Rivera J, Garcia-Monforte A. Hepatitis C virus infection presenting as rheumatoid arthritis. Why not? *J Rheumatol* 1999;26:2062–3.
- [224] Lovy MR, Starkebaum G, Uberoi S. Hepatitis C infection presenting with rheumatic manifestations: a mimic of rheumatoid arthritis. *J Rheumatol* 1996;23:979–83.
- [225] Zuckerman E, Keren D, Rozenbaum M, Toubi E, Slobodin G, Tamir A, et al. Hepatitis C virus-related arthritis: characteristics and response to therapy with interferon alpha. *Clin Exp Rheumatol* 2000;18:579–84.
- [226] Fadda P, La Civita L, Zignego AL, Ferri C. Hepatitis C virus infection and arthritis. A clinico-serological investigation of arthritis in patients with or without cryoglobulinemic syndrome. *Reumatismo* 2002;54:316–23.
- [227] Palazzi C, D'Angelo S, Olivieri I. Hepatitis C virus-related arthritis. *Autoimmun Rev* 2008;8:48–51.
- [228] Olivieri I, Palazzi C, Padula A. Hepatitis C virus and arthritis. *Rheum Dis Clin North Am* 2003;29:111–22.
- [229] Sene D, Ghillani-Dalbin P, Limal N, Thibault V, van Boekel T, Piette JC, et al. Anti-cyclic citrullinated peptide antibodies in hepatitis C virus associated rheumatological manifestations and Sjogren's syndrome. *Ann Rheum Dis* 2006;65:394–7.
- [230] Bombardieri M, Alessandri C, Labbadia G, Iannuccelli C, Carlucci F, Riccieri V, et al. Role of anti-cyclic citrullinated peptide antibodies in discriminating patients with

- rheumatoid arthritis from patients with chronic hepatitis C infection-associated polyarticular involvement. *Arthritis Res Ther* 2004;6:R137–41.
- [231] Akhtar AJ, Funnay AS. Hepatitis C virus associated arthritis in absence of clinical, biochemical and histological evidence of liver disease—responding to interferon therapy. *Med Sci Monit* 2005;11:CS37–9.
- [232] Palazzi C, D'Amico E, D'Angelo S, Gilio M, Leccese P, Olivieri I. An update on the management of hepatitis C virus-related arthritis. *Expert Opin Pharmacother* 2014;15:2039–45.
- [233] Ferri C, Sebastiani M, Antonelli A, Colaci M, Manfredi A, Giuggioli D. Current treatment of hepatitis C-associated rheumatic diseases. *Arthritis Res Ther* 2012;14:215.
- [234] Ferri C, Cacoub P, Mazzaro C, Roccatello D, Scaini P, Sebastiani M, et al. Treatment with rituximab in patients with mixed cryoglobulinemia syndrome: results of multicenter cohort study and review of the literature. *Autoimmun Rev* 2011;11:48–55.
- [235] Zimmermann R, König V, Bauditz J, Hopf U. Interferon alfa in leukocytoclastic vasculitis, mixed cryoglobulinaemia, and chronic hepatitis c. *Lancet* 1993;341(8844):561–2.
- [236] Bojic I, Lalic D, Radojicic C, Mijuskovic P. deterioration of mixed cryoglobulinemia during treatment with interferon-alpha-2a. *J Gastroenterol* 1994;29(3):369–71.
- [237] Johnson RJ, Gretch DR, Couser WG, Alpers CE, Wilson J, Chung M, et al. Hepatitis C virus-associated glomerulonephritis. Effect of alpha-interferon therapy. *Kidney Int* 1994;46(6):1700–4.
- [238] Mazzaro C, Pozzato G, Moretti M, Crovatto M, Modolo ML, Mazzi G, et al. Long-term effects of alpha-interferon therapy for type II mixed cryoglobulinemia. *Haematologica* 1994;79(4):342–9.
- [239] Gilli P, Stabellini N, Storari A, Gualandi G, Guerra G, Ghinelli F. Effect of human leukocyte alpha interferon on cryoglobulinaemic membranoproliferative glomerulonephritis associated with hepatitis C virus infection. *Nephrol Dial Transplant* 1996;11(3):526–8.
- [240] Harle JR, Disdier P, Pelletier J, Azulay JP, Perréard M, Weiller PJ, et al. Dramatic worsening of hepatitis C virus-related cryoglobulinemia subsequent to treatment with interferon alfa. *JAMA* 1995;274(2):126.
- [241] Mazzaro C, Lacchin T, Moretti M, Tulissi P, Manazzono O, Colle R, et al. Effects of two different alpha-interferon regimens on clinical and virological findings in mixed cryoglobulinemia. *Clin Exp Rheumatol* 1995;13(Suppl. 13):S181–5.
- [242] Migliaresi S, Tirri G. Interferon in the treatment of mixed cryoglobulinemia. *Clin Exp Rheumatol* 1995;13(Suppl. 13):S175–80.
- [243] Yamabe H, Inuma H, Osawa H, Kaizuka M, Tamura N, Tsunoda S, et al. Glomerular deposition of hepatitis C virus in membranoproliferative glomerulonephritis. *Nephron* 1996;72(4):741.
- [244] Casaril M, Capra F, Gabrielli GB, Bassi A, Squarzone S, Dagradi R, et al. Cryoglobulinemia in hepatitis C virus chronic active hepatitis: effects of interferon-alpha therapy. *J Interferon Cytokine Res* 1996;16(8):585–8.
- [245] Cohen P, Nguyen QT, Deny P, Ferrière F, Roulot D, Lortholary O, et al. Treatment of mixed cryoglobulinemia with recombinant interferon alpha and adjuvant therapies. A prospective study on 20 patients. *Ann Med Interne (Paris)* 1996;147(2):81–6.
- [246] Sarac E, Bastacky S, Johnson JP. Response to high-dose interferon-alpha after failure of standard therapy in MPGN associated with hepatitis C virus infection. *Am J Kidney Dis* 1997;30(1):113–5.
- [247] Zuber M, Gause A. Peripheral neuropathy during interferon-alpha therapy in patients with cryoglobulinemia and hepatitis virus infection. *J Rheumatol* 1997;24(12):2488–9.
- [248] Akriviadis EA, Xanthakis I, Navrozidou C, Papadopoulos A. Prevalence of cryoglobulinemia in chronic hepatitis C virus infection and response to treatment with interferon-alpha. *J Clin Gastroenterol* 1997;25(4):612–8.
- [249] Casato M, Agnello V, Pucillo LP, Knight GB, Leoni M, Del Vecchio S, et al. Predictors of long-term response to high-dose interferon therapy in type II cryoglobulinemia associated with hepatitis C virus infection. *Blood* 1997;90(10):3865–73.
- [250] Mazzaro C, Carniello GS, Colle R, Doretto P, Mazzi G, Crovatto M, et al. Interferon therapy in HCV-positive mixed cryoglobulinaemia: viral and host factors contributing to efficacy of the therapy. *Ital J Gastroenterol Hepatol* 1997;29(4):343–50.
- [251] Donada C, Crucitti A, Donadon V, Chemello L, Alberti A. Interferon and ribavirin combination therapy in patients with chronic hepatitis C and mixed cryoglobulinemia. *Blood* 1998;92(8):2983–4.
- [252] Durand JM, Cacoub P, Lunel-Fabiani F, Cosserat J, Cretel E, Kaplanski G, et al. Ribavirin in hepatitis C related cryoglobulinemia. *J Rheumatol* 1998;25(6):1115–7.
- [253] Gordon AC, Edgar JD, Finch RG. Acute exacerbation of vasculitis during interferon-alpha therapy for hepatitis C-associated cryoglobulinaemia. *J Infect* 1998;36(2):229–30.
- [254] Scelsa SN, Herskovitz S, Reichler B. Treatment of mononeuropathy multiplex in hepatitis C virus and cryoglobulinemia. *Muscle Nerve* 1998;21(11):1526–9.
- [255] Calleja JL, Albillos A, Moreno-Otero R, Rossi I, Cacho G, Domper F, et al. Sustained response to interferon-alpha or to interferon-alpha plus ribavirin in hepatitis C virus-associated symptomatic mixed cryoglobulinaemia. *Aliment Pharmacol Ther* 1999;13(9):1179–86.
- [256] Cid MC, Hernandez-Rodríguez J, Robert J, del Río A, Casademont J, Coll-Vinent B, et al. Interferon-alpha may exacerbate cryoglobulinemia-related ischemic manifestations: an adverse effect potentially related to its anti-angiogenic activity. *Arthritis Rheum* 1999;42(5):1051–5.
- [257] Cresta P, Musset L, Cacoub P, Frangeul L, Vitour D, Poynard T, et al. Response to interferon alpha treatment and disappearance of cryoglobulinaemia in patients infected by hepatitis C virus. *Gut* 1999;45(1):122–8.
- [258] Friedman G, Mehta S, Sherker AH. Fatal exacerbation of hepatitis C-related cryoglobulinemia with interferon-alpha therapy. *Dig Dis Sci* 1999;44(7):1364–5.
- [259] Misiani R, Bellavita P, Baio P, Caldara R, Ferruzzi S, Rossi P, et al. Successful treatment of HCV-associated cryoglobulinaemic glomerulonephritis with a combination of interferon-alpha and ribavirin. *Nephrol Dial Transplant* 1999;14(6):1558–60.
- [260] Garini G, Allegri L, Carnevali L, Cattellani W, Manganeli P, Buzzi C. Interferon-alpha in combination with ribavirin as initial treatment for hepatitis C virus-associated cryoglobulinemic membranoproliferative glomerulonephritis. *Am J Kidney Dis* 2001;38(6):E35.
- [261] Naarendorp M, Kallemuchikkal U, Nuovo GJ, Gorevic PD. Longterm efficacy of interferon-alpha for extrahepatic disease associated with hepatitis C virus infection. *J Rheumatol* 2001;28(11):2466–73.
- [262] Beddhu S, Bastacky S, Johnson JP. The clinical and morphologic spectrum of renal cryoglobulinemia. *Medicine (Baltimore)* 2002;81(5):398–409.
- [263] Casato M, Mecucci C, Agnello V, Fiorilli M, Knight GB, Matteucci C, et al. Regression of lymphoproliferative disorder after treatment for hepatitis C virus infection in a patient with partial trisomy 3, Bcl-2 overexpression, and type II cryoglobulinemia. *Blood* 2002;99(6):2259–61.
- [264] Loustaud-Ratti V, Liozon E, Karaaslan H, Alain S, Paraf F, Le Meur Y, et al. Interferon alpha and ribavirin for membranoproliferative glomerulonephritis and hepatitis C infection. *Am J Med* 2002;113(6):516–9.
- [265] Sikaneta T, Williams WW, Chung RT, Cosimi AB, Pascual AM. Remission of hepatitis C virus-associated cryoglobulinemic glomerulonephritis with interferon alfa-2b and ribavirin combination therapy after liver transplantation. *Transplantation* 2002;74(12):1767–8.
- [266] Bruchfeld A, Lindahl K, Stahle L, Soderberg M, Schvarcz R. Interferon and ribavirin treatment in patients with hepatitis C-associated renal disease and renal insufficiency. *Nephrol Dial Transplant* 2003;18(8):1573–80.
- [267] Rossi P, Bertani T, Baio P, Caldara R, Luliri P, Tengattini F, et al. Hepatitis C virus-related cryoglobulinemic glomerulonephritis: long-term remission after antiviral therapy. *Kidney Int* 2003;63(6):2236–41.
- [268] Alric L, Plaisier E, Thebault S, Péron JM, Rostaing L, Pourrat J, et al. Influence of antiviral therapy in hepatitis C virus-associated cryoglobulinemic MPGN. *Am J Kidney Dis* 2004;43(4):617–23.
- [269] Batisse D, Karmochkine M, Jacquot C, Kazatchkine MD, Weiss L. Sustained exacerbation of cryoglobulinaemia-related vasculitis following treatment of hepatitis C with peginterferon alfa. *Eur J Gastroenterol Hepatol* 2004;16(7):701–3.
- [270] Cacoub P, Saadoun D, Limal N, Sene D, Lidove O, Piette Jc. PEGylated interferon alfa-2b and ribavirin treatment in patients with hepatitis C virus-related systemic vasculitis. *Arthritis Rheum* 2005;52(3):911–5.
- [271] Levine JW, Gota C, Fessler BJ, Calabrese LH, Cooper SM. Persistent cryoglobulinemic vasculitis following successful treatment of hepatitis C virus. *J Rheumatol* 2005;32(6):1164–7.
- [272] Mazzaro C, Zorat F, Caizzi M, Donada C, Di Gennaro G, Maso LD, et al. Treatment with peg-interferon alfa-2b and ribavirin of hepatitis C virus-associated mixed cryoglobulinemia: a pilot study. *J Hepatol* 2005;42(5):632–8.
- [273] Vigani AG, Macedo-De-Oliveira A, Pavan MH, Pedro MN, Goncalves Jr FL. Hepatitis C virus infection, cryoglobulinemia, and peripheral neuropathy: a case report. *Braz J Med Biol Res* 2005;38(12):1729–34.
- [274] Saadoun D, Resche-Rigon M, Thibault V, Piette JC, Cacoub P. Antiviral therapy for hepatitis C virus-associated mixed cryoglobulinemia vasculitis: a long-term followup study. *Arthritis Rheum* 2006;54(11):3696–706.
- [275] Parise ER, De Oliveira AC, Ferraz ML, Pereira AB, Leite KR. Cryoglobulinemia in chronic hepatitis C: clinical aspects and response to treatment with interferon alpha and ribavirin. *Rev Inst Med Trop Sao Paulo* 2007;49(2):67–72.
- [276] Koziolk MJ, Scheel A, Bramlage C, Groene HJ, Mueller GA, Strutz F. Effective treatment of hepatitis C-associated immune-complex nephritis with cryoprecipitate apheresis and antiviral therapy. *Clin Nephrol* 2007;67(4):245–9.
- [277] Trebst C, Wedemeyer H, Manns MP, Tillmann H, Windhagen A. Treatment of hepatitis C virus-associated inflammatory polyneuropathy with pegylated interferon-alpha and ribavirin. *Eur J Gastroenterol Hepatol* 2007;19(1):91–2.
- [278] De Blasi T, Aguilari Maruccio D, Cariti G, Maiello A, De Rosa FG, Di Perri G. Cryoglobulinemia-related vasculitis during effective anti-HCV treatment with PEG-interferon alfa-2b. *Infection* 2008;36(3):285–7.
- [279] Landau DA, Rosenzweig M, Saadoun D, Trebeden-Negre H, Klatzmann D, Cacoub P. Correlation of clinical and virologic responses to antiviral treatment and regulatory T cell evolution in patients with hepatitis C virus-induced mixed cryoglobulinemia vasculitis. *Arthritis Rheum* 2008;58(9):2897–907.
- [280] Donato MF, Fabrizi F, Fogazzi GB, Cresseri D, Passerini P, Martin P, et al. Remission of HCV-associated glomerulonephritis with pegylated ifn and ribavirin therapy after liver transplantation: case report and literature review. *Int J Artif Organs* 2013;36(1):63–8.
- [281] Saadoun D, Resche Rigon M, Thibault V, Longuet M, Pol S, Blanc F, et al. Peg-IFNalpha/ribavirin/protease inhibitor combination in hepatitis C virus associated mixed cryoglobulinemia vasculitis: results at week 24. *Ann Rheum Dis* 2014;73(5):831–7.
- [282] De Nicola S, Aghemo A, Campise MR, D'Ambrosio R, Rumi MG, Messa P, et al. Telaprevir in a patient with chronic hepatitis C and cryoglobulinemic glomerulonephritis. *Antivir Ther* 2014;19(5):527–31.
- [283] Sultanik P, Klotz C, Brault P, Pol S, Mallet V. Regression of an HCV-associated disseminated marginal zone lymphoma under IFN-free antiviral treatment. *Blood* 2015;125(15):2446–7.
- [284] Flemming JA, Lowe CE. Successful treatment of hepatitis C, genotype 3, with sofosbuvir/ledipasvir in decompensated cirrhosis complicated by mixed cryoglobulinaemia. *BMJ Case Rep* 2016;2016.
- [285] Sollima S, Milazzo L, Peri AM, Torre A, Antinori S, Galli M. Persistent mixed cryoglobulinaemia vasculitis despite hepatitis C virus eradication after interferon-free antiviral therapy. *Rheumatology (Oxford)* 2016.