

Isolation of *Leptospira* serovar Pomona from a crested porcupine (*Hystrix cristata*, L., 1758)

Giovanni Cilia¹ | Fabrizio Bertelloni¹  | Francesca Coppola¹  | Barbara Turchi¹ |
 Claudia Biliotti^{1,2} | Alessandro Poli¹ | Francesca Parisi¹ | Antonio Felicioli¹ |
 Domenico Cerri¹ | Filippo Fratini¹ 

¹Department of Veterinary Sciences,
 University of Pisa, Pisa, Italy

²CRASM "Semproniano", Grosseto, Italy

Correspondence

Filippo Fratini, Department of Veterinary
 Science, University of Pisa, Viale delle
 Piagge 2, 56124 Pisa, Italy.
 Email: filippo.fratini@unipi.it

Funding information

University of Pisa

Abstract

Pathogenic *Leptospira* is widespread in rodents, the most studied *reservoir* and the main hosts involved in its transmission. In Italy, among rodents, *Hystrix cristata* (crested porcupine) is the largest species and it is distributed all over the country. In this paper, the isolation and characterization of pathogenic *Leptospira* spp. from the kidney of *H. cristata* is reported for the first time. During Autumn 2018, *Leptospira* detection by real-time PCR and isolation were performed from kidneys of two died female porcupines (an adult and a porcupette). Only for porcupette kidney sample, real-time PCR for pathogenic *Leptospira* tested positive. The isolated strain was identified as *Leptospira interrogans* serogroup Pomona serovar Pomona, using the three schemes of multilocus sequence typing. The results show that *H. cristata* could be a *Leptospira* host. The infection of serovars Pomona could be related to the habitat shared with wild boar, a typical *reservoir* host for this serovar.

KEYWORDS

crested porcupine, isolation, *Leptospira*, MLST, zoonosis

1 | INTRODUCTION

Leptospirosis is a re-emerging bacterial zoonosis (Chikeka & Dumler, 2015; Picardeau, 2017; Ruiz-Fons, 2017) with a wide distribution in tropical, subtropical and temperate areas. The spreading of this disease is favoured by the presence of a large diversity of wild and domestic mammals with the function of *Leptospira reservoir* (Chikeka & Dumler, 2015; Faine, Adler, Bolin, & Perolat, 1999). Among asymptomatic maintenance hosts, localization of *Leptospira* occurs in the kidney, liver and in some animals, such as bovine or swine, also in the

reproductive tract (Ellis, 2015). *Leptospira* localization in the kidney is the main route of shedding and environmental spread of this bacterium (Adler & de la Peña Moctezuma, 2010; Ellis, 2015). *Leptospira* epidemiology is strictly related to the presence of the maintenance hosts species (Cerri, Ebani, Fratini, Pinzauti, & Andreani, 2003). Recently, association between serovars and new wild and domestic species emerged, suggesting variation in leptospirosis epidemiology in both humans and animals (Tagliabue et al., 2016).

Rodents are considered among the most important *reservoir* of *Leptospira* (Adler & de la Peña Moctezuma, 2010). In different

Giovanni Cilia and Fabrizio Bertelloni equally contributed to this work.

The peer review history for this article is available at <https://publons.com/publon/10.1002/vms3.308>.

This is an open access article under the terms of the Creative Commons Attribution License, which permits use, distribution and reproduction in any medium, provided the original work is properly cited.

© 2020 The Authors. *Veterinary Medicine and Science* published by John Wiley & Sons Ltd

countries, some rodents, such as for *Apodemus* spp., *Bandicota* spp., *Delomys* spp., *Mus* spp., *Necomys* spp., *Oryzomys* spp., *Rattus* spp., *Thaptomys* spp., *Trinomys* spp. and also for *Myocastor coypus*, and *Hydrochaeris hydrochaeris* were described as *Leptospira* maintenance hosts (Cortizo et al., 2015; Cosson et al., 2014; Fratini et al., 2015; Jorge et al., 2012; Krijger, Ahmed, Goris, Groot Koerkamp, & Meerburg, 2019; Levett, 2001; Michel et al., 2001; Moreno, Miraglia, Marvulo, et al., 2016; Vieira et al., 2019; Vieira, Pinto, & Lilenbaum, 2018).

Recently, crested porcupine (*Hystrix cristata*, L. 1758) sera collected in Italy resulted positive for serogroup Icterohaemorrhagiae, Australis and Pomona (Coppola, Cilia, et al., 2020). Furthermore, among porcupines (Rodentia; Hystricomorpha), *Leptospira* serovar Pomona, was isolated from the blood, urine and kidney of one North American porcupine, *Erethizon dorsatum* (Mitchell, Robertson, Corner, & Boulanger, 1966). Serological investigation on Malayan porcupine (*Hystrix brachyura*) evidenced antibodies against the serovars Javanica, Hurstbridge, Ballum, Celledoni and Hardjoprajitno (Siti-Nurdyana, Bahaman, Sharma, Azlan, & Abdul Razak, 2016). Molecular analysis on the DNA extracted from urine of *Sphiggurus villosus* (orange-spined hairy dwarf porcupine) also evidenced a renal *Leptospira* infection, despite the microscopic agglutination test (MAT) resulted negative (Fornazari, Langoni, Marson, Nóbrega, & Teixeira, 2018).

Italy is the only European country where the crested porcupine live in the wild as naturalized specie (Coppola, Dari, Vecchio, Scarselli & Felicioli, In press, Santini, 1980). Porcupine is the largest rodent of the Italian fauna and is widely distributed in mainland and it is also present in Sicily and Sardinia. (Loy et al., 2019; Mori, Sforzi, Bogliani, & Milanesi, 2018). Recently, Vecchio, Coppola, Scarselli, Giannini, and Felicioli (2018) report the presence of at least one free-ranging crested porcupine in the Island of Elba using camera-trapping rising the question if a population of this rodent is also present in the Island.

Within a more general study on the epidemiology of *Leptospira* in Italian wildlife, this paper reports the first case of *Leptospira* serovar Pomona isolation in *H. cristata*.

2 | MATERIAL AND METHODS

2.1 | Samples collection

In Autumn 2018, sampling was performed on two crested porcupines died for traumatic impact in a veterinary clinic, in the Grosseto province (Tuscany, Italy). The first one was recovered in the area of Pescia Fiorentina (Capalbio), whereas the second one in the area of Arcille (Campagnatico). At the clinic, animals were treated with enrofloxacin and dexamethasone for about 3 days before the death. From each carcass, during necropsy, kidneys and a blood sample from the heart cavity were collected. Before the necropsy, both animals were sexed and weighted and the age class was estimated (porcupette < 5 kg; 5 kg ≤ sub-adult < 11 kg; adult ≥ 12 kg; (Coppola, Vecchio, & Felicioli, 2019).

2.2 | Microscopic agglutination test

Blood samples were centrifugated at 1,200 g rpm for 10 min to obtain the serum. The sera were tested to detect *Leptospira* antibodies by MAT (OIE, 2018). Titre of 1:100 was considered as positive. The *Leptospira* live antigens used for MAT were as follows: Icterohaemorrhagiae (serogroup Icterohaemorrhagiae, strain Bianchi), Canicola (serogroup Canicola, strain Alarik), Pomona (serogroup Pomona, strain Mezzano), Grippotyphosa (serogroup Grippotyphosa, strain Moskva V), Tarassovi (serogroup Tarassovi, strain Mitis Johnson), Bratislava (serogroup Australis, strain Riccio 2), Hardjo (serogroup Sejroe, serovar Hardjoprajitno), Castellonis (serogroup Ballum, strain Castellon 3), Copenhageni (serogroup Icterohaemorrhagiae, strain Wijmberg), Bataviae (serogroup Bataviae, strain Pavia), Australis (serogroup Australis, strain Ballico), Zانونi (serogroup Pyrogenes, strain Zانونi), Saxkoebing (serogroup Sejroe, strain Mus 24), Sejroe (serogroup Sejroe, strain Topo 1), Poi (serogroup Javanica, strain Poi), Mini (serogroup Mini, strain Sari), Lora (serogroup Australis, strain Riccio 37), Hardjo (serogroup Sejroe, strain Farina), Autumnalis (serogroup Autumnalis, strain Akiyami A) and Hebdomadis (serogroup Hebdomadis, strain Hebdomadis).

2.3 | *Leptospira* spp. isolation

The kidney samples were cultured in Ellinghausen–McCullough–Johnson–Harris (EMJH) medium (Difco). A portion of 10 cm³ from each porcupine kidney was homogenized with 5 ml of sterile water. One ml of homogenate was cultured in 5 ml of EMJH, incubated at 30 ± 1°C for 120 days and checked every 10 days under dark-filed microscopy to assess bacterial growth.

In case of positive cultures, subcultures were performed to maintain the isolated strains alive.

2.4 | *Leptospira* spp. genotyping

Isolated *Leptospira* were genotyped using a multilocus sequence typing scheme encompassing housekeeping genes (Ahmed et al., 2006; Boonsilp et al., 2013; Varni et al., 2014).

The amplification of each target gene was performed with HotStarTaq Master Mix Kit (Qiagen). Amplicons were further sequenced (BMR Genomics) using the same primer sets and analysed using BioEdit Software (Hall, 1999).

2.5 | Molecular analysis

DNA was extracted from each kidney using the Quick-DNA Plus Kits (Zymo Research) according to the manufacturer's instructions.

The *lipL32* gene Taqman RealTime PCR was performed on a Rotorgene Corbett 6000 (Corbett Research) to detect pathogenic leptospire (Stoddard, Gee, Wilkins, McCaustland, & Hoffmaster, 2009). The following thermal conditions were

employed: a holding stage of 95°C for 5 min, and 45 cycles of 95°C for 15 s and 60°C for 30 s. Samples with Ct *lipL32*<35 were considered as positive.

2.6 | Histopathology and immunohistochemistry

Representative portions of the kidneys collected during necropsy were routinely processed, paraffin-embedded and 5- μ m-thick sections were stained with haematoxylin and eosin, Masson trichrome Goldner and Warthin Starry stains. Tissue sections were also submitted to immunohistochemistry. Antigen retrieval was achieved on the slides by placing them in a bath of 10 mmol/L citric acid (pH 6) and boiling for 16 min in an 800-W microwave oven. The slides were dried at room temperature and washed with running tap water. A peroxidase block was performed, and the slides were incubated with specific rabbit antisera against *Leptospira interrogans* serogroup Pomona and *Leptospira kirschneri* serogroup Grippotyphosa. The primary antibodies were diluted 1:300 in a buffer solution (PBS) prior to incubation. A polyclonal horse serum (1 drop diluted in 1 ml of PBS) was used as a secondary antibody for 30 min at room temperature (Vector Laboratories). Antibody binding was detected using a streptavidin-biotin-peroxidase kit (Vector Laboratories). The enzymatic reaction was developed with the use of 3-1-diaminobenzidine (Sigma Chemical) as a substrate. Stained slides were subsequently counter-stained in haematoxylin for 40 s followed by a wash in tap water, dehydration in graded alcohols (70%, 90% and 100%), and clearance with xylene. Sections were mounted in DPX (08600E; Surgipath Europe). As a positive control, a pig kidney culture-positive for serogroup Pomona and a mouse kidney culture-positive for serogroup Grippotyphosa were used.

3 | RESULTS

Both exanimate porcupines were female, one adult of 11 kg (more than 1 year old) and a porcupette (around 2 months old) of 1.4 kg. The kidney of the porcupette showed small gray-white focal lesions, mainly located in the renal cortex and varying from 1 to 2 mm in diameter. Microscopically, a mild chronic interstitial nephritis was present, characterized by vacuolar degeneration of the tubular epithelium and scattered interstitial foci consisting of lymphocytes and plasma cells (Figure 1a), accompanied by interstitial fibrosis (Figure 1b). In silver-stained sections, leptospirae were never detected in the tubular lumen adhering to the luminal surface of tubular cells, whereas Intracytoplasmic spherical bodies within cells of a tubule undergoing regressive changes were observed. In immunoperoxidase-stained sections, using antisera against *Leptospira* serogroup Pomona an intense immunoreactivity for leptospiral antigen was detectable within the tubular epithelia cells and in cellular debris in tubular lumen (Figure 1c), whereas the absence of immune-labelling was observed when

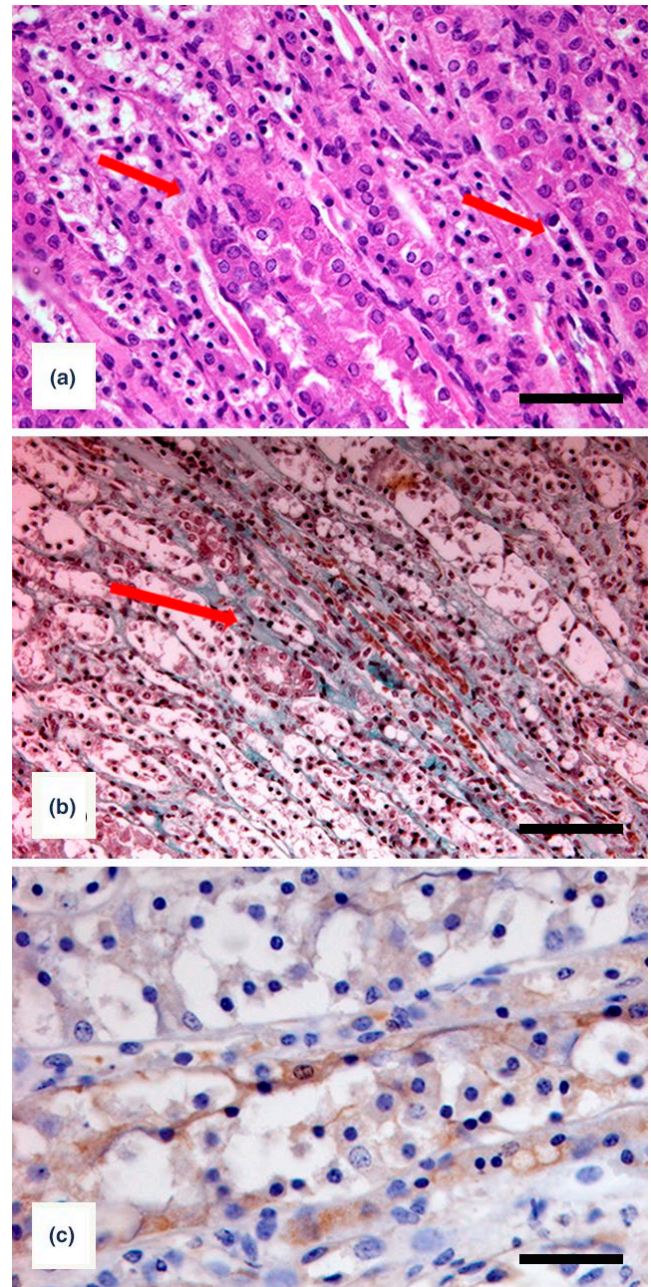


FIGURE 1 Crested porcupine kidney. Renal alterations associated with *Leptospira* infection. (a) Mild interstitial nephritis characterized by lymphocyte and plasma cell infiltration (arrows; H-E; bar = 50 μ m). (b) Mild interstitial fibrosis (arrow) surrounded by scattered inflammatory cells (Masson trichrome Goldner stain; bar = 50 μ m). (c) Leptospiral antigen is present within tubular epithelial cells undergoing regressive changes (immunohistochemical staining using anti serovar Pomona antiserum and haematoxylin counterstain; bar = 30 μ m)

the antiserum against *Leptospira* serogroup *Grippotyphosa* was used.

Both sera samples resulted negative to MAT for all *Leptospira* serogroups tested. Only in porcupette kidney, *Leptospira* DNA was detected and after 2 months of incubation, the bacterium was isolated. The isolated strain was identified as *L. interrogans* serogroup Pomona

serovar Pomona, showing the sequence type (ST) 140 for scheme 1, ST 4 for scheme 2 and ST 58 for scheme 3.

4 | DISCUSSION

Only recently, crested porcupine was investigated as potential vector or host for a wide range of parasites and micro-organisms, such as fleas and hard ticks (Mori et al., 2015; Scaravelli, Senini, & Bonacci, 2017), *Giardia duodenalis* (Coppola, Maestrini, et al., 2020) and pathogenic *Leptospira* (Coppola, Cilia, et al., 2020). For the first time, *L. interrogans* serogroup Pomona serovar Pomona was isolated from one out of two analysed porcupine kidneys. Both sampled sera were negative for *Leptospira* serovars Pomona and for the other *Leptospira* serovars tested, whereas pathogenic *Leptospira* DNA was detected only in renal tissue from porcupette. The seronegativity of *Leptospira*-positive subjects was previously reported for other species (Agampodi, Matthias, Moreno, & Vinetz, 2012; Hall & Lambourne, 2014; Merien, Baranton, & Perolat, 1995) and for porcupine (*S. villosus*), as well (Fornazari et al., 2018). The serological negativity of *Leptospira*-positive porcupette could be related to the quality of blood sample collected from the heart cavity or to an early or chronic infection. However, a chronic infection seems to be unlikely due to the young age of the animal. At the same time, the presence of an early stage infection can be excluded considering the stage of renal lesions, characterized by the presence of inflammatory infiltrates, mild fibrosis and the absence of a large amount of leptospire localized in tubular lumen, typically detectable during early *Leptospira* infection. At this stage, the micro-organisms should be numerous, intact and easy to visualize by both the immunohistochemical and silver-staining methods and the perifocal inflammatory infiltrates are scanty or absent (Michna & Campbell, 1969). Subsequently, when the inflammatory cells surround the infected tubules, leptospire are lysed, clumped and leptospiral antigen are taken up by tubular cells. In this case, immunohistochemical studies allow to detect the presence of *Leptospira* antigen in tubular epithelial cells and to reveal intracytoplasmic spherical bodies within the cells of renal tubules undergoing regressive changes, as previously described in leptospiral nephritis in swine (Scanziani, Sironi, & Mandelli, 1989). Previous electron microscopic studies demonstrated the presence of degenerating leptospire within these vesicles in tubular cells (Ellis, Robertson, Hustas, & Kirby, 1983).

The seronegativity of *Leptospira*-positive subject could be related to the antibiotic treatment with enrofloxacin, performed during the hospitalization. Activity of enrofloxacin against *Leptospira* is documented in vitro, but some studies showed increased MIC values in recent isolates (Liegeon, Delory, & Picardeau, 2018; Moreno et al. 2016). Carrascosa et al. (2017) showed a low effectiveness of this antibiotic in vivo in order to prevent *Leptospira* renal colonization in hamster and a decrease in antibiotic effectiveness when the treatment is delayed from the starting of the infection. However, antibiotic treatment could have

affect the antibodies response, leading to negative MAT results, as previously reported by Ricaldi, Swancutt, and Matthias (2013) and Courdurie et al. (2017). The antibiotic treatment could have also determined the lack of leptospire in the renal tissue highlighted with specific Warthin Starry staining. The reduced bacterial load has also been highlighted by the long incubation period of the culture before the isolation of the *Leptospira* strain (Azizi, Kheirandish, & Rahimi, 2014).

Rodents are well known important *Leptospira* carriers, involved in the infection transmission to animals and humans (Blasdell, Morand, Perera, & Firth, 2019; Mori et al., 2017). The evidence of a possible *Leptospira* infection in crested porcupine was previously investigated in the same studied area. Seven out of 14 (50%) of porcupine sera resulted positive to anti-*Leptospira* antibodies detection; Icterohaemorrhagiae resulted the most prevalent serogroup (4 positive sera), followed by serogroup Pomona and Australis (2 sera, respectively). Titres of 1:400 and 1:100 were recorded for serogroup Pomona (Coppola, Cilia, et al., 2020). At the best of Authors knowledge, excluding *H. cristata*, among the Hystricomorpha rodents, isolation of *Leptospira* serovar Pomona from kidney, blood and urine was only performed in one North American porcupine (Mitchell et al., 1966) and no other *Leptospira* serovar were isolated. The crested porcupine *Leptospira* serovar Pomona infection documented in this paper could be the result of habitat sharing with wild boar (*Sus scrofa*) which are present in Tuscany (Italy) with an high-density population (Massei et al., 2015; Santilli & Varuzza, 2013). The wild boar plays a key role in the spreading of some *Leptospira* serovars, such as Pomona, in the environment (Bertelloni et al., 2019; Chiari et al., 2016). These factors could strongly increase and promote the possibility of porcupine infection.

The isolation of *Leptospira* from crested porcupine suggests that *H. cristata* could be a new potential natural host for this bacterium.

Authors are aware of the limit of the study, since it represents a case report of *Leptospira* serovar Pomona infection in crested porcupine. Despite the single positive sample, this result could be a useful contribute to the description of the epidemiology of leptospirosis. Further investigations are needed to specifically determine the role of crested porcupine as accidental or as maintenance host for *Leptospira*.

5 | CONCLUSION

Leptospirosis is one of the most widespread and emerging zoonotic disease in the world, and wild animals were known to be reservoir of *Leptospira*. The results obtained in this paper show that *H. cristata* could be a *Leptospira* host, as hypothesized for other hystricomorph rodents. The infection by serovars Pomona, typically observed in swine and wild boar, could suggest an adaptability and/or a change in host range for this serovar, as assumed for other serovars. Further investigations are needed to clarify the role of this peculiar rodent in the epidemiology of leptospirosis in Italy.

ACKNOWLEDGEMENT

This research has been supported by Fondi di Ateneo of the University of Pisa.

CONFLICT OF INTEREST

All authors declare no conflict of interests.

AUTHOR CONTRIBUTION

Giovanni Cilia: Data curation; Formal analysis; Investigation; Methodology; Writing-original draft; Writing-review & editing. **Fabrizio Bertelloni:** Data curation; Formal analysis; Methodology; Writing-original draft; Writing-review & editing. **FRANCESCA COPPOLA:** Data curation; Investigation; Writing-original draft; Writing-review & editing. **Barbara Turchi:** Data curation; Investigation; Methodology; Writing-review & editing. **Claudia Biliotti:** Data curation; Investigation; Writing-review & editing. **Alessandro Poli:** Data curation; Investigation; Methodology; Writing-review & editing. **Francesca Parisi:** Data curation; Investigation; Methodology; Writing-review & editing. **Antonio Felicioli:** Conceptualization; Data curation; Supervision; Writing-original draft; Writing-review & editing. **Domenico Cerri:** Conceptualization; Data curation; Resources; Supervision; Writing-review & editing. **Filippo Fratini:** Conceptualization; Data curation; Investigation; Methodology; Resources; Supervision; Writing-original draft; Writing-review & editing.

ETHICAL STATEMENT

The authors confirm that the ethical policies of the journal, as noted on the journal's author guidelines page, have been adhered to. No ethical approval was required.

DATA AVAILABILITY STATEMENT

The data that support the findings of this study are available from the corresponding author upon reasonable request.

ORCID

Fabrizio Bertelloni  <https://orcid.org/0000-0002-5292-0613>
 Francesca Coppola  <https://orcid.org/0000-0003-1571-3620>
 Filippo Fratini  <https://orcid.org/0000-0002-1717-2947>

REFERENCES

- Adler, B., & de la Peña Moctezuma, A. (2010). *Leptospira* and leptospirosis. *Veterinary Microbiology*, *140*, 287–296. <https://doi.org/10.1016/j.vetmic.2009.03.012>
- Agampodi, S. B., Matthias, M. A., Moreno, A. C., & Vinetz, J. M. (2012). Utility of quantitative polymerase chain reaction in leptospirosis diagnosis: Association of level of leptospiremia and clinical manifestations in Sri Lanka. *Clinical Infectious Disease*, *54*, 1249–1255. <https://doi.org/10.1093/cid/cis035>
- Ahmed, N., Devi, S. M., de los Á Valverde, M., Vijayachari, P., Machang'u, R. S., Ellis, W. A., & Hartskeerl, R. A. (2006). Multilocus sequence typing method for identification and genotypic classification of pathogenic *Leptospira* species. *Annals of Clinical Microbiology and Antimicrobials*, *5*, 28. <https://doi.org/10.1186/1476-0711-5-28>
- Azizi, S., Kheirandish, R., & Rahimi, E. (2014). Comparison of polymerase chain reaction and Warthin-Starry techniques to detect

- Leptospira* spp. in kidneys of slaughtered cattle. *Onderstepoort Journal of Veterinary Research*, *81*, 1–6. <https://doi.org/10.4102/ojvr.v81i1.821>
- Bertelloni, F., Cilia, G., Turchi, B., Pinzauti, P., Cerri, D., & Fratini, F. (2019). Epidemiology of leptospirosis in North-Central Italy: Fifteen years of serological data (2002–2016). *Comparative Immunology, Microbiology and Infectious Disease*, *65*, 14–22. <https://doi.org/10.1016/J.CIMID.2019.04.001>
- Blasdel, K. R., Morand, S., Perera, D., & Firth, C. (2019). Association of rodent-borne *Leptospira* spp. with urban environments in Malaysian Borneo. *PLoS Neglected Tropical Disease*, *13*, e0007141. <https://doi.org/10.1371/journal.pntd.0007141>
- Boonsilp, S., Thaipadungpanit, J., Amornchai, P., Wuthiekanun, V., Bailey, M. S., Holden, M. T. G., ... Peacock, S. J. (2013). A single Multilocus Sequence Typing (MLST) scheme for seven pathogenic *Leptospira* species. *PLoS Neglected Tropical Disease*, *7*, e1954. <https://doi.org/10.1371/journal.pntd.0001954>
- Carrascosa, A., Gutierrez, L., De la Peña, A., Candanosa, I. E., Tapia, G., & Sumano, H. (2017). Efficacy of a New Recrystallized Enrofloxacin Hydrochloride-Dihydrate against Leptospirosis in a Hamster Model. *Antimicrob. Agents Chemother.* *61*. <https://doi.org/10.1128/AAC.01285-17>
- Cerri, D., Ebani, V. V., Fratini, F., Pinzauti, P., & Andreani, E. (2003). Epidemiology of leptospirosis: Observations on serological data obtained by a "diagnostic laboratory for leptospirosis" from 1995 to 2001. *New Microbiology*, *26*, 383–389.
- Chiari, M., Figarolli, B. M., Tagliabue, S., Alborali, G. L., Bertoletti, M., Papetti, A., ... Boniotti, M. B. (2016). Seroprevalence and risk factors of leptospirosis in wild boars (*Sus scrofa*) in northern Italy. *Hystrix, Italian Journal of Mammalogy*, *27*. <https://doi.org/10.4404/hystrix-27.2-11682>
- Chikeka, I., & Dumler, J. S. (2015). Neglected bacterial zoonoses. *Clinical Microbiology and Infection*, *21*, 404–415. <https://doi.org/10.1016/j.cmi.2015.04.022>
- Coppola, F., Cilia, G., Bertelloni, F., Casini, L., D'Addio, E., Fratini, F., ... Felicioli, A. (2020). Crested porcupine (*Hystrix cristata* L.): A new potential host for pathogenic leptospira among semi-fossorial mammals. *Comparative Immunology, Microbiology and Infectious Diseases*, *70*, 101472. <https://doi.org/10.1016/j.cimid.2020.101472>
- Coppola, F., Dari, C., Vecchio, G., Scarselli, D., & Felicioli, A. (In press). Co-habitation settlements between Crested Porcupines (*Hystrix cristata*), Red Foxes (*Vulpes vulpes*) and European Badgers (*Meles meles*). *Current science*.
- Coppola, F., Maestrini, M., Berrilli, F., Procesi, I. G., Felicioli, A., & Perrucci, S. (2020). First report of *Giardia duodenalis* infection in the crested porcupine (*Hystrix cristata* L., 1758). *International Journal for Parasitology: Parasites and Wildlife*, *11*, 108–113. <https://doi.org/10.1016/j.ijppaw.2020.01.006>
- Coppola, F., Vecchio, G., & Felicioli, A. (2019). Diurnal motor activity and "sunbathing" behaviour in crested porcupine (*Hystrix cristata* L., 1758). *Scientific Reports*, *9*, 14283. <https://doi.org/10.1038/s41598-019-50784-y>
- Cortizo, P., Loureiro, A. P., Martins, G., do Rodrigues, P. R., Faria, B. P., Lilienbaum, W., & Deminicis, B. B. (2015). Risk factors to incidental leptospirosis and its role on the reproduction of ewes and goats of Espírito Santo state, Brazil. *Tropical Animal Health and Production*, *47*, 231–235. <https://doi.org/10.1007/s11250-014-0684-4>
- Cosson, J.-F., Picardeau, M., Mielcarek, M., Tatar, C., Chaval, Y., Suputtamongkol, Y., ... Morand, S. (2014). Epidemiology of *Leptospira* transmitted by rodents in Southeast Asia. *PLoS Neglected Tropical Disease*, *8*, e2902. <https://doi.org/10.1371/journal.pntd.0002902>
- Courdurie, C., Le Govic, Y., Bourhy, P., Alexer, D., Pailla, K., Theodose, R., ... Olive, C. (2017). Evaluation of different serological assays for early diagnosis of leptospirosis in Martinique (French West Indies). *PLoS*

- Neglected Tropical Disease*, 11, e0005678. <https://doi.org/10.1371/journal.pntd.0005678>
- Ellis, T. M., Robertson, G. M., Hustas, L., & Kirby, M. (1983). Detection of leptospires in tissue using an immunoperoxidase staining procedure. *Australian Veterinary Journal*, 60, 364–367. <https://doi.org/10.1111/j.1751-0813.1983.tb02849.x>
- Ellis, W. A. (2015). Animal leptospirosis. *Current Topics in Microbiology and Immunology*, 387, 99–137. https://doi.org/10.1007/978-3-662-45059-8_6
- Faine, S., Adler, B., Bolin, C., & Perolat, P. (1999). *Leptospira* and Leptospirosis. In *Leptospira and leptospirosis*. Melbourne, Vic., Australia: Medisci Press.
- Fornazari, F., Langoni, H., Marson, P. M., Nóbrega, D. B., & Teixeira, C. R. (2018). *Leptospira* reservoirs among wildlife in Brazil: Beyond rodents. *Acta Tropica*, 178, 205–212. <https://doi.org/10.1016/j.actatropica.2017.11.019>
- Fratini, F., Turchi, B., Ebani, V. V., Bertelloni, F., Galiero, A., & Cerri, D. (2015). The presence of *Leptospira* in coypus (*Myocastor coypus*) and rats (*Rattus norvegicus*) living in a protected wetland in Tuscany (Italy). *Veterinarski Arhiv*, 85, 407–414.
- Hall, C., & Lambourne, J. (2014). The challenges of diagnosing leptospirosis. *Journal of Travel Medicine*, 21, 139–140. https://doi.org/10.1111/jtm.12095_1
- Hall, T. A. (1999). BioEdit: A user-friendly biological sequence alignment editor and analysis program for Windows 95/98/NT. *Nucleic Acids Symposium Series*, 41, 95–98.
- Jorge, S., Monte, L. G., Coimbra, M. A., Albano, A. P., Hartwig, D. D., Lucas, C., ... Hartleben, C. P. (2012). Detection of virulence factors and molecular typing of pathogenic *Leptospira* from capybara (*Hydrochaeris hydrochaeris*). *Current Microbiology*, 65, 461–464. <https://doi.org/10.1007/s00284-012-0169-5>
- Krijger, I. M., Ahmed, A. A. A., Goris, M. G. A., Groot Koerkamp, P. W. G., & Meerburg, B. G. (2019). Prevalence of *Leptospira* Infection in Rodents from Bangladesh. *International Journal of Environmental Research and Public Health*, 16, 2113. <https://doi.org/10.3390/ijerph16122113>
- Levett, P. N. (2001). Leptospirosis. *Clinical Microbiology Review*, 14, 296–326. <https://doi.org/10.1128/CMR.14.2.296-326.2001>
- Liegeon, G., Delory, T., & Picardeau, M. (2018). Antibiotic susceptibilities of livestock isolates of *Leptospira*. *International Journal of Antimicrobial Agents*, 51, 693–699. <https://doi.org/10.1016/j.ijant.2017.12.024>
- Loy, A., Aloise, G., Ancillotto, L., Angelici, F. M., Bertolino, S., Capizzi, D., ... Amori, G. (2019). Mammals of Italy: An annotated checklist. *Hystrix*, 30, 87–106. <https://doi.org/10.4404/hystrix-00196-2019>
- Massei, G., Kindberg, J., Licoppe, A., Gačić, D., Šprem, N., Kamler, J., ... Náhlik, A. (2015). Wild boar populations up, numbers of hunters down? A review of trends and implications for Europe. *Pest Management Science*, 71, 492–500. <https://doi.org/10.1002/ps.3965>
- Merien, F., Baranton, G., & Perolat, P. (1995). Comparison of polymerase chain reaction with microagglutination test and culture for diagnosis of leptospirosis. *Journal of Infectious Diseases*, 172, 281–285. <https://doi.org/10.1093/infdis/172.1.281>
- Michel, V., Ruvoen-Clouet, N., Menard, A., Sonrier, C., Fillonneau, C., Rakotova, F., ... André-Fontaine, G. (2001). Role of the coypu (*Myocastor coypus*) in the epidemiology of leptospirosis in domestic animals and humans in France. *European Journal of Epidemiology*, 17, 111–121. <https://doi.org/10.1023/A:1017931607318>
- Michna, S. W., & Campbell, R. S. (1969). Leptospirosis in pigs: Epidemiology, microbiology and pathology. *Veterinary Records*, 84, 135–138. <https://doi.org/10.1136/vr.84.6.135>
- Mitchell, D., Robertson, A., Corner, A. H., & Boulanger, P. (1966). Some observations on the diagnosis and epidemiology of leptospirosis in swine. *Canadian Journal of Comparative Medicine and Veterinary Science*, 30, 211–217.
- Moreno, L. Z., Miraglia, F., Lilenbaum, W., Neto, J. S. F., Freitas, J. C., Morais, Z. M., ... Moreno, A. M. (2016). Profiling of *Leptospira interrogans*, *L. santarosai*, *L. meyeri* and *L. borgpetersenii* by SE-AFLP, PFGE and susceptibility testing – A continuous attempt at species and serovar differentiation. *Emerging Microbes and Infections*, 5, e17. <https://doi.org/10.1038/emi.2016.16>
- Moreno, L. Z., Miraglia, F., Marvulo, M. F. V., Silva, J. C. R., Paula, C. D., Costa, B. L. P., ... Moreno, A. M. (2016). Characterization of *Leptospira santarosai* serogroup Grippotyphosa serovar Bananal isolated from capybara (*Hydrochaeris hydrochaeris*) in Brazil. *Journal of Wildlife Diseases*, 52, 688–693. <https://doi.org/10.7589/2015-09-245>
- Mori, E., Sforzi, A., Bogliani, G., & Milanese, P. (2018). Range expansion and redefinition of a crop-raiding rodent associated with global warming and temperature increase. *Climatic Change*, 150, 319–331. <https://doi.org/10.1007/s10584-018-2261-8>
- Mori, E., Sforzi, A., Menchetti, M., Mazza, G., Lovari, S., & Pisanu, B. (2015). Ectoparasite load in the crested porcupine *Hystrix cristata* Linnaeus, 1758 in Central Italy. *Parasitology Research*, 114, 2223–2229. <https://doi.org/10.1007/s00436-015-4413-3>
- Mori, M., Bourhy, P., Le Guyader, M., Van Esbroeck, M., Djelouadji, Z., Septfons, A., ... Picardeau, M. (2017). Pet rodents as possible risk for leptospirosis, Belgium and France, 2009 to 2016. *Eurosurveillance*, 22(43). <https://doi.org/10.2807/1560-7917.ES.2017.22.43.16-00792>
- OIE. (2018). Leptospirosis. In *Manual of diagnostic tests and vaccines for terrestrial animals*, (503–516). https://www.oie.int/fileadmin/Home/eng/Health_standards/tahm/3.01.12_LEPTO.pdf
- Picardeau, M. (2017). Virulence of the zoonotic agent of leptospirosis: Still terra incognita? *Nature Reviews Microbiology*, 15, 297–307. <https://doi.org/10.1038/nrmicro.2017.5>
- Ricaldi, J. N., Swancutt, M. A., & Matthias, M. A. (2013). Current trends in translational research in leptospirosis. *Current Opinion in Infectious Disease*, 26, 1. <https://doi.org/10.1097/QCO.0000000000000001>
- Ruiz-Fons, F. (2017). A review of the current status of relevant zoonotic pathogens in wild swine (*Sus scrofa*) populations: Changes modulating the risk of transmission to humans. *Transboundary and Emerging Diseases*, 64, 68–88. <https://doi.org/10.1111/tbed.12369>
- Santilli, F., & Varuzza, P. (2013). Factors affecting wild boar (*Sus scrofa*) abundance in southern Tuscany. *Hystrix, Italian Journal of Mammalogy*, 24, 169–173. <https://doi.org/10.4404/hystrix-24.2-4776>
- Santini, L. (1980). The habits and influence on the environment of the old world porcupine *Hystrix cristata* L. in the northernmost part of its range. In *Proceedings of the 9th vertebrate pest conference* (pp. 149–153). <https://digitalcommons.unl.edu/vpc9/34>
- Scanziani, E., Sironi, G., & Mandelli, G. (1989). Immunoperoxidase studies on leptospiral nephritis of swine. *Veterinary Pathology*, 26, 442–444. <https://doi.org/10.1177/030098588902600510>
- Scaravelli, D., Senini, C., & Bonacci, T. (2017). First case of traumatic myiasis caused by *Calliphora vicina* in a crested porcupine *Hystrix cristata* L. in Italy. *Journal of Entomological and Acarological Research*, 49, 81–84. <https://doi.org/10.4081/jear.2017.6823>
- Siti-Nurdyana, A., Bahaman, A., Sharma, R., Azlan, C., & Abdul Razak, M. (2016). Serological prevalence of leptospiral infection in captive Malayan porcupines (*Hystrix brachyura*). *Journal of Veterinary Malaysia*, 28, 1–3.
- Stoddard, R. A., Gee, J. E., Wilkins, P. P., McCaustland, K., & Hoffmaster, A. R. (2009). Detection of pathogenic *Leptospira* spp. through TaqMan polymerase chain reaction targeting the LipL32 gene. *Diagnostic Microbiology and Infectious Disease*, 64, 247–255. <https://doi.org/10.1016/j.diagmicrobio.2009.03.014>
- Tagliabue, S., Figarolli, B. M., D'Incau, M., Foschi, G., Gennero, M. S., Giordani, R., ... Ruocco, L. (2016). Serological surveillance of Leptospirosis in Italy: Two-year national data (2010–2011). *Veterinaria Italiana*, 52, 129–138. <https://doi.org/10.12834/VetIt.58.169.2>

- Varni, V., Ruybal, P., Lauthier, J. J., Tomasini, N., Brihuega, B., Koval, A., & Caimi, K. (2014). Reassessment of MLST schemes for *Leptospira* spp. typing worldwide. *Infection, Genetic and Evolution*, 22, 216–222. <https://doi.org/10.1016/j.meegid.2013.08.002>
- Vecchio, G., Coppola, F., Scarselli, D., Giannini, F., & Felicioli, A. (2018). Crested porcupine in the Island of Elba, Italy: Native or alien? *Current Science*, 114, 246–247. <https://doi.org/10.18520/cs/v114/i02/246-247>
- Vieira, A. S., D'Andrea, P. S., do V. Vilela, R., Loretto, D., Jaeger, L. H., Carvalho-Costa, F. A., & Lilenbaum, W. (2019). Pathogenic *Leptospira* species are widely disseminated among small mammals in Atlantic Forest biome. *Transboundary and Emerging Diseases*, 66, 1195–1201. <https://doi.org/10.1111/tbed.13135>
- Vieira, A. S., Pinto, P. S., & Lilenbaum, W. (2018). A systematic review of leptospirosis on wild animals in Latin America. *Tropical Animal Health and Production*, 50, 229–238. <https://doi.org/10.1007/s11250-017-1429-y>

How to cite this article: Cilia G, Bertelloni F, Coppola F, et al. Isolation of *Leptospira* serovar Pomona from a crested porcupine (*Hystrix cristata*, L., 1758). *Vet Med Sci*. 2020;00: 1–7. <https://doi.org/10.1002/vms3.308>