

Serum 25-hydroxyvitamin D concentration in Japanese Akita dogs: A survey

L. Casini^{a,*}, D. Zago^b, E. Cavicchioli^b, C. Tomiazzi^b

^a Department of Veterinary Science, University of Pisa, Viale delle Piagge 2, 56124 Pisa, Italy

^b Veterinary Clinic San Giacomo, Via Risorgimento 42b, 35020 Albinasego, Padova, Italy

ARTICLE INFO

Keywords:

Depigmentation
Dogs
Immune-mediated disease
Japanese Akita breed
Vitamin D

ABSTRACT

Low serum level of vitamin D has been linked to numerous diseases. The Akita breed of dog shows a high incidence of immune-mediated diseases such as uveodermatologic (UVD) syndrome and sebaceous adenitis (SA). Furthermore, in Japanese Akita dogs, skin depigmentation often appears after birth at different ages, in healthy dogs, and without any other symptoms. In humans poliosis is associated to low vitamin D level. The aim of this survey was to evaluate serum 25-hydroxyvitamin D (25(OH)D) levels in Japanese Akita dogs. One hundred and three Akita blood samples were collected for the 25(OH)D evaluation. Age, sex, current disease, presence and location of skin depigmentation, and diet were reported on a medical record. Based on history and clinical examination, dogs were classified according their health status as healthy (HE) or pathological (PA). The overall mean of 25(OH)D concentration was 82.42 ± 26.14 ng/mL, whereas the concentrations in the healthy dogs were significantly higher (84.90 ± 3.36 ng/mL) in comparison with the dogs with diseases (72.13 ± 4.09 ng/mL) ($P < 0.01$). In this study, the depigmented healthy dogs showed low level of 25(OH)D and very similar to the sick group. The appearance of depigmented areas associated with low levels of vitamin D could be considered as an alert sign in Akitas as well as in humans. However, clinical trials should also be carried out to establish whether vitamin D supplementation could be an effective preventive treatment to limit the onset of immune-mediated diseases in Japanese Akita dogs.

Introduction

In recent years, vitamin D deficiency or low serum 25-hydroxyvitamin D (25(OH)D) levels has been linked to numerous inflammatory and immune-mediated diseases. The great diffusion of vitamin D receptors in several organs and tissues confirms a wide involvement of vitamin D in many biological processes, not strictly linked to calcium homeostasis metabolism. Genomic analysis identified more than 2700 genomic position of vitamin D receptors and many vitamin D receptor binding sites were significantly mapped near to autoimmune and cancer associated genes (Ramagopalan et al., 2010). Furthermore, in healthy humans, low vitamin D status has been associated with an increase in inflammatory markers (Peterson & Heffernan, 2008). Deficiency or low serum 25(OH)D levels have been also reported in vitiligo human patients with and without systemic autoimmune diseases (Birlea, Costin, & Norris, 2009; Kriegel, Manson & Costenbader, 2011; Xianglong, Peizeng, Min Sun, & Fuzhen, 2011; Saleh, Abdel Fattah, & Hamza, 2013; Karagün et al., 2016). For these evidences, control of serum vitamin D level is often recommended in risk patients, and Vitamin D supplementation is used to treat vitiligo and other skin disorders (AlGhamdi, Kumar, & Moussa, 2013). Vitamin

D deficiency is known to be prevalent in epilepsy patients as well, and evidences showed that maintaining adequate levels of vitamin D improves the control of epileptic seizures (Hollò, Clemens, Kamondi, Lakatos, & Szűcs, 2012).

In domestic carnivores, unlike other mammals including humans, skin vitamin D synthesis induced by sun exposure does not occur, therefore dogs for vitamin D supply are mainly dependent on food intake (How, Hazewinkel, & Mol, 1994; Corbee, Vaandrager, Kik, Molenaar, & Hazewinkel, 2015). Because of this reason, both quantity and bioavailability of vitamin D in diet makes the daily intake of fundamental importance for dogs' health condition. Moreover, according to Weidner and Verbrughe (2017) the blood 25(OH)D concentration can be considered a useful marker of vitamin D status.

As well as in humans, researchers have found associations of low 25(OH)D levels in dogs affected by different diseases: acute and chronic renal failure, canine lymphoma, cutaneous mast cell tumours, inflammatory bowel disease, heart disease, blastomycosis, and cancer (Gerber, Hässig, & Reusch, 2003; Gow et al., 2011; Wakshlag et al., 2011; Selting, Sharp, Ringold, Thamm, & Backus, 2014; Titmarsh et al., 2015; O'Brien, McMichael, & Le Boedec, 2018).

The Akita dog breed shows a high incidence of immune-mediated

* Corresponding author.

E-mail address: lcasini@unipi.it (L. Casini).

<https://doi.org/10.1016/j.vas.2020.100139>

Received 24 June 2020; Received in revised form 14 August 2020; Accepted 16 August 2020

Available online 17 August 2020

2451-943X/ © 2020 The Authors. Published by Elsevier Ltd. This is an open access article under the CC BY-NC-ND license (<http://creativecommons.org/licenses/by-nc-nd/4.0/>).

diseases characterized by severe and debilitating symptoms. In Akitas, the most common immune-mediated diseases are uveodermatologic (UVD) syndrome and sebaceous adenitis (SA). UVD syndrome, also known as Vogt-Koyanagi-Harada (VKH)-like syndrome, has a high incidence in many breeds of dogs (Baiker et al., 2011; Kang, Lim, & Park, 2014) but the highest predisposition appears among Akitas (Barros et al., 1991; Pye, 2009), with about 80% of the case reports in the veterinary literature (Angles, Famula, & Pedersen, 2005). In humans, VKH syndrome is characterized by bilateral granulomatous uveitis with poliosis, dysacusia, and meningitis. Dogs affected by UVD have similar symptoms with chronic bilateral uveitis and cutaneous involvement, characterized by poliosis. Like UVD, SA has been described in many breeds but there seems to be a breed predisposition in Akita dogs (Reichler et al., 2001). In Japanese Akita dogs, skin depigmentation similar to vitiligo often appears after birth at different ages in healthy dogs without any other symptoms.

Despite the wealth of research on vitamin D and its relationship with chronic diseases, little has been studied in dogs (Gerber et al., 2003; Gow et al., 2011; Rosa, Schoeman, Berry, Mellanby, & Dvir, 2013; Kraus et al., 2014; Selting et al., 2014; Sharp, Selting, & Ringold, 2015; Spoo et al., 2015; Titmarsh et al., 2015). At present, at our knowledge, no publications evaluating the vitamin D status in Japanese Akita breed are available.

Due to the importance of Vitamin D blood concentration and the specific Akita predisposition in developing immune-mediated disease, the aim of this study was to evaluate serum 25(OH)D levels in Japanese Akita dogs.

Materials and methods

Serum samples

Owners of Japanese Akita dogs were contacted by the nonprofit AkitaLab Association (Rieti, Italy); they were invited to allow veterinarians to submit an aliquot of serum from blood sample, previously collected during routine veterinary visits and withdrawals, for 25-hydroxyvitamin D (25(OH)D) evaluation. Each owner was required to provide signed consent. Age, sex, current disease, presence and location of skin depigmentations, and diet for each dog were reported on a medical record. Over a period of one year, 103 serum samples from Japanese Akita dogs were collected and included in the present study.

On the basis of the history and the clinical examination, dogs were classified according to their health status as healthy (HE) or pathological (PA). The pathological dogs were affected by: UVD syndrome, sebaceous adenitis, chronic dermatitis, epilepsy, toxoplasmosis, allergy, enteritis, and arthrosis. Moreover, inside the HE and PA groups, dogs were subgrouped according to the presence of complete pigmentation (PI) or the presence of not-congenital depigmented areas (DE).

Analysis

After collection, the blood samples were centrifuged, and serum stored at -18 °C till analysis. Serum 25(OH)D was analysed at an accredited laboratory (IDEXX Laboratories, accreditation n. D-PL-13356-01 according to DIN EN ISO/IEC 17025:2005, Germany) using the High-Performance Liquid Chromatography (HPLC) technique (RS-LC UltiMate™ 3000, Dionex) for the quantitative determination of 25(OH)D. Intra and inter-assay precision were 8 and 13% respectively.

Statistical methods

Descriptive statistics were performed (mean \pm SD, range, number or percentage of observations). Differences between HE and PA groups for the presence of pigmented and not-pigmented areas was evaluated by χ^2 test. Correlation between vitamin D level and dogs' age was tested by the Pearson correlation coefficient (r). Serum 25(OH)D

Table 1

Signalment information of 103 Japanese Akita dogs under investigation.

		n	%
Sex	male	45 (neutered 4)	43.69
	female	58 (spayed 15)	56.31
Healthy	pigmented	37	62.71
	depigmented	22	37.29
Pathological	pigmented	28	63.64
	depigmented	16	36.36
Pathology	Sebaceous Adenitis	21	47.73
	Dermatitis	6	13.64
	Uveodermatologic syndrome	6	13.64
	Epilepsy	5	11.36
	Arthrosis	2	4.55
	Enteritis	2	4.55
	Allergy	1	2.27
	Toxoplasmosis	1	2.27
Diet	Commercial	72	69.90
	Home-made	31	30.10

concentration was evaluated by ANOVA including health status (HE or PA), skin pigmentation (PI or DE), and diet (Commercial or Home-made) as main factors, and the health status x skin status interaction. Interactions including diets were not considered because of the low number of animals fed home-made diets. Shapiro-Wilk test was performed to verify the normal distribution of the residuals. The t -test and Tukey's Honest Significant Differences (HSD) test were used and the level of significance was set at $P \leq 0.05$; the resulting data are shown as LSM \pm ES. All statistical tests were performed using JMP® software (SAS Institute Inc., Cary, NC).

Results

Dogs mean age was 2.60 ± 1.58 years old. Furthermore, out of 103, 45 were males (41 sexually intact and 4 neutered) and 58 females (43 sexually intact and 15 spayed). The prevalent disease recorded among investigated Akitas was sebaceous adenitis (47.73%), then 13.64% cases of dermatitis, and 13.64% of uveodermatologic syndrome were observed. Commercial dry food, from 25 different brands, was consumed by 72 subjects (69.90%), and 31 dogs (30.10%) were fed home-made diet (Table 1). In the commercial food used, the average inclusion level of vitamin D was 1405 UI/kg as feed (ranging from 520 to 2500 UI/kg), whereas for the home-made diets the level of vitamin D supplementation was not available.

The overall mean serum 25(OH)D concentration in the sampled dogs was 82.42 ± 26.14 ng/mL (mean \pm SD), with a range from 33.00 to 144.00 ng/mL. No correlation ($r = -0.17$; $P = 0.08$) between serum 25(OH)D concentration and age was observed (Fig. 1).

Fifty-nine dogs resulted healthy, whereas 44 dogs were included in the PA group. Sixty-five dogs were recorded as completely pigmented, whereas 38 were classified as depigmented ones. As for the latter, the areas of depigmentation were mainly located on nose, oral mucosa, palate and near genital area. The χ^2 test did not detect differences between pigmented and depigmented dogs within the HE and PA groups (37.29% and 36.36%, respectively).

Due to the low number of dogs fed home-made diet, the effect of diet was not included in the statistical model, nevertheless the lowest level of 25(OH)D concentrations were observed in PA/PI group fed home-made diet (60.55 ± 15.59 ng/mL), and the highest 25(OH)D levels in HE/PI dogs fed commercial diet (98.11 ± 26.30 ng/mL).

According to the ANOVA a significant difference in serum 25(OH)D concentration was detected for health status ($P = 0.01$). The healthy dogs showed a higher level of 25(OH)D (84.90 ± 3.36 ng/mL) than the pathological dogs' group (72.13 ± 4.09 ng/mL). Although the skin status effect was not significant ($P = 0.06$), the pigmented dogs showed a higher 25(OH)D level (83.22 ± 3.24 ng/mL) than the depigmented ones (73.82 ± 4.16 ng/mL). Also diet main effect was not significant

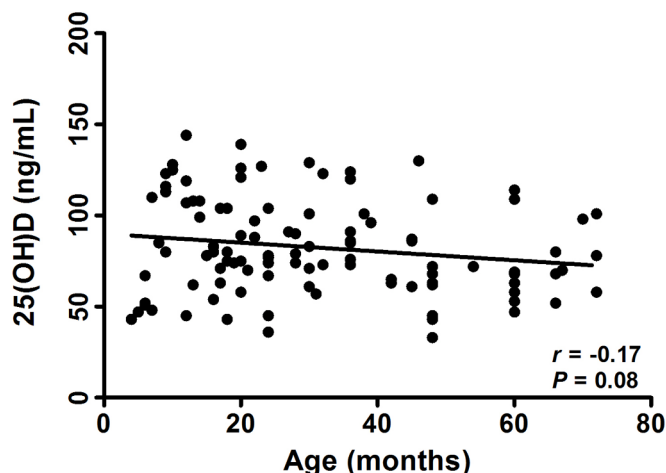


Fig. 1. Scatterplot and Pearson correlation coefficient (*r*) between 25(OH)D concentration and age (months) in Japanese Akita dogs.

(*P* = 0.13), but a higher 25(OH)D concentration was found for dogs fed commercial diet (82.58 ± 2.97 ng/mL) compared to Akitas receiving home-made diets (74.45 ± 4.55 ng/mL). Therefore, for both factors, health and skin status, a good health status and regular skin pigmentation were related to a higher level of serum 25(OH)D concentration than non-healthy or depigmented dogs, respectively.

The analysis of the health status x skin status interaction, although not significant at the ANOVA, showed that the serum 25(OH)D in HE/PI dogs (93.81 ± 4.19 ng/mL) was significantly higher than all other dogs' groups (Table 2). Therefore, according to Tukey HSD test, within the group of healthy dogs the skin depigmentation was significantly related to a reduction in 25(OH)D serum. Differently, within the PA group, pigmented and depigmented dogs showed almost the same level of 25(OH)D that was also close to the level detected in HE depigmented dogs (Fig. 2).

Discussion

Japanese Akita dogs have a high frequency of immune-mediate diseases, such as uveodermatologic (UVD) syndrome and sebaceous adenitis (SA) (Angles et al., 2005). One of the clinical signs of UVD is the presence of depigmented areas of the skin, quite similar to vitiligo in humans. The association of vitiligo with vitamin D deficiency is widely studied in human patients (Birlea et al., 2009; Saleh et al., 2013; Colucci et al., 2020). Moreover, results available from scientific literature suggest that vitamin D influences the immune system and low 25(OH)D levels are associated with autoimmune diseases (Cantorna & Mahon, 2004; Smolders, Menheere, Kessels, Damoiseaux, & Hupperts, 2008; Ersoy-Evans, 2010).

In the present study, Japanese Akita breed dogs affected by immune-mediated (UVD and SA) and chronic diseases showed a significant lower serum 25(OH)D concentration in comparison with healthy Akitas. Nonetheless, in healthy and pigmented dogs the 25(OH)D

Table 2
Serum 25(OH)D level (LSM ± ES) in healthy and pathological Japanese Akita dogs.

	<i>n</i>	25(OH)D ng/mL
Healthy pigmented	37	93.81 ± 4.19 a
Healthy depigmented	22	75.99 ± 4.70 b
Pathological pigmented	28	72.62 ± 5.20 b
Pathological depigmented	16	71.64 ± 6.41 b

n: number of dogs.

a, b: means with different letters within column are significantly different.

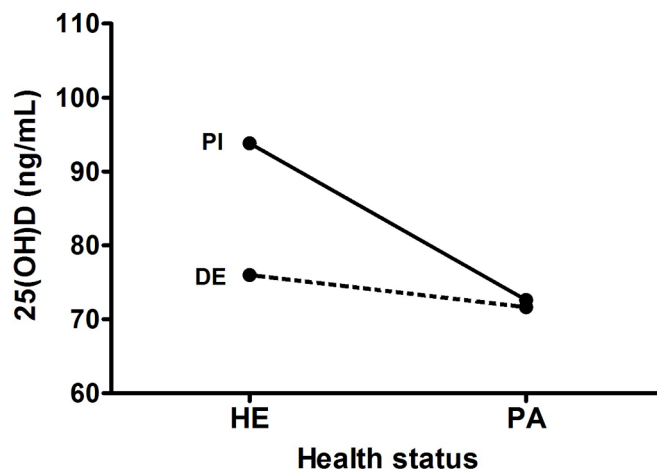


Fig. 2. Interaction between health status (HE: healthy, PA: pathological) and skin pigmentation (PI: pigmented, DE: depigmented) for 25(OH)D in Japanese Akita dogs.

D mean value was below to 100 ng/mL that is considered the sufficient level to reduce the risk for serious diseases (Selting et al., 2014). As reported by other Authors, breed significantly influenced serum vitamin D concentration. Indeed, as referred by Sharp et al. (2015) German Shepherd breed (mean value: 76.5 ng/mL) highlighted a 26% higher 25(OH)D concentration than Golden Retrievers (mean value: 60.6 ng/mL). In the investigated Akitas, the maximum value recorded for vitamin D was 144 ng/mL, which was lower compared to the one indicated by Sharp et al. (2015) for German Shepherds and Golden Retrievers (212.80 ng/mL and 249.20 ng/mL, respectively).

In human studies a strong correlation between hypovitaminosis D and the autoimmune skin disease vitiligo was detected (Upala & Snaguankeo, 2016; El-Hanbuli, Dawoud, & Mahmoud, 2018). The association between low serum 25(OH)D level and depigmentation was also found in the current study and it is confirmed by a significantly lower serum 25(OH)D level in the group of HE/DE Akitas compared to the HE/PI one.

Vitamin D is strictly involved in many biological activities, in particular it is able to modify the T cell compartment into a more anti-inflammatory and regulated state (Baekke, Takiishi, Korf, Gysemans, & Mathieu, 2010; Miraglia Del Giudice, Indolfi, & Strisciuglio, 2018). Moreover, canine C-reactive protein, biomarker of systemic inflammation in dogs, significantly decreased when 25(OH)D concentrations rose above 100 ng/mL of 25(OH)D and significant drop when 25(OH)D concentrations reach 100 ng/mL (Selting et al., 2014). The low serum 25(OH)D concentration observed in Akita group affected by different diseases and compared with the healthy one, confirmed the previous investigations in several dog breeds (Gow et al., 2011; Selting et al., 2014; Titmarsh et al., 2015).

Because of the importance of daily intake of vitamin D with food, the type of diet could affect circulating vitamin D levels. In this study, healthy and pigmented dogs fed commercial diets showed the highest levels of vitamin D. These findings are probably due to the differences between the vitamin D inclusion in commercial and home-made diets.

In the present survey a high percentage of dogs fed commercial diet rather than home-made diet was found, showing a preference of dogs' owners for commercial products. In pet food, vitamin D supplementation satisfies dog requirements according to NRC (2006) and FEDIAF, European Pet Food Industry Federation (2019) recommendations, which are only related to the minimum requirements for calcium and phosphorus metabolism. Therefore, the regular intake of pet food will allow to maintain adequate levels of vitamin D in normal dogs, while the present results suggest that healthy-depigmented, as well as pathological, Akita dogs need a higher level of vitamin D supplementation

than healthy-pigmented ones. Therefore, the addition of vitamin D in feed should be adjusted based on the health and/or skin pigmentation status of the dogs.

Unfortunately, in the present study, the great variety of home-made recipes and the multiple differences between commercial diets did not make possible to estimate the vitamin D real content in the diets and its level of intake in the monitored Akita dogs.

Conclusions

The survey results support the relationship between low serum level of 25(OH)D, diseases, and depigmentation as highlighted in other investigation both in humans and dogs. The constant low vitamin D levels could be an additional risk factor in the onset of serious pathologies and should be a wake-up call in veterinary diagnostics. Furthermore, the appearance of depigmented areas associated with low levels of vitamin D could be considered as an alert sign in dogs, especially in Akitas, as well as in humans. Therefore, the monitoring of serum 25(OH)D concentration in dogs with skin depigmentation, particularly in breeds at risk of severe immune-mediated diseases, could be considered within a haematological analysis profile. Nevertheless, the results of the present survey have several limitations. In particular, the data analysed were based on an observational study without any control on diets. Therefore, further prospective studies are needed to assess the association between vitamin D and diseases; clinical trials should also be helpful to establish whether vitamin D supplementation could be used as preventive treatment to limit the onset of immune-mediated diseases in Japanese Akita breed.

Funding

This study was supported by the University of Pisa public grant and by nonprofit AkitaLab Association.

Ethical statement

The approval of the ethics committee was not considered necessary because we did not handle the animals, according the Directive 2010/63/EU. The biological material was provided by private veterinary clinics and withdrawn for other purposes. Furthermore, the owners involved in the research were informed and provided signed consent to use the dogs' clinical data.

Declaration of Competing Interest

None of the authors has financial or personal relationships that could inappropriately influence or bias the content of the paper. Dr. C. Tomiazio, as president of the nonprofit AkitaLab Association, organized the collection and the shipment of the samples without any involvement in data analysis and results interpretation.

Acknowledgments

We are grateful to the nonprofit AkitaLab Association (Rieti, Italy) for organizing the collection of samples.

References

AlGhamdi, K., Kumar, A., & Moussa, N. (2013). The role of vitamin D in melanogenesis with an emphasis on vitiligo. *Indian Journal of Dermatology, Venereology and Leprology*, 79, 750–758. <https://doi.org/10.4103/0378-6323.120720>.

Angles, J. M., Famula, T. R., & Pedersen, N. C. (2005). Uveodermatologic (VKH-like) syndrome in American Akita dogs is associated with an increased frequency of DQA1*00201. *Tissue Antigens*, 66, 656–665. <https://doi.org/10.1111/j.1399-0039.2005.00508.x>.

Baeke, F., Takiishi, T., Korf, H., Gysemans, C., & Mathieu, C. (2010). Vitamin D: Modulator of the immune system. *Current Opinion in Pharmacology*, 10, 482–496.

<https://doi.org/10.1016/j.coph.2010.04.001>.

Baiker, K., Scurrill, E., Wagner, T., Walker, D., Solano-Gallego, L., Holt, E., et al. (2011). Polymyositis following Vogt-Koyanagi-Harada-like syndrome in a Jack Russell terrier. *Journal of Comparative Pathology*, 144, 317–323. <https://doi.org/10.1016/j.jcpa.2010.10.006>.

Barros, P. S.de, Safatle, A., Malerba, T. A., Yrio, K., Alvarenga, J., & Larsson, M. H. (1991). Uveitis and dermal depigmentation (Vogt-Koyanagi-Harada-like syndrome) in Akita dogs. I. Clinical aspects. *Brazilian Journal of Veterinary Research and Animal Science*, 28(1), 75–79. <https://doi.org/10.11606/issn.1678-4456.bjvras.1991.51927>.

Birlea, S. A., Costin, G. E., & Norris, D. A. (2009). New insights on therapy with vitamin D analogs targeting the intracellular pathways that control repigmentation in human vitiligo. *Medicinal Research Reviews*, 29(3), 514–546. <https://doi.org/10.1002/med.20146>.

Cantorna, M. T., & Mahon, B. D. (2004). Mounting evidence for vitamin D as an environmental factor affecting autoimmune disease prevalence. *Experimental Biology and Medicine*, 229(11), 1136–1142. [10.1177/153537020422901108](https://doi.org/10.1177/153537020422901108).

Colucci, R., Conti, R., Dragoni, F., Cammi, A., Cianferotti, L., Brandi, M. L., et al. (2020). Evidence of a possible therapeutic role of vitamin D in a cohort of adult Caucasian vitiligo patients. *International Journal for Vitamin and Nutrition Research*, 90, 200–204. <https://doi.org/10.1024/0300-9831/a000605>.

Corbee, R. J., Vaandrager, A. B., Kik, M. J. L., Molenaar, M. R., & Hazewinkel, H. A. W. (2015). Cutaneous Vitamin D Synthesis in Carnivorous Species. *Journal of Veterinary Medicine and Research*, 2(4), 1031–1034.

El-Hanbuli, H. M., Dawoud, N. M., & Mahmoud, R. H. (2018). Narrow-band UVB effects on cutaneous vitamin D receptor expression and serum 25-hydroxyvitamin D in generalized vitiligo. *Photodermatology, Photoimmunology & Photomedicine*, 34, 175–183. <https://doi.org/10.1111/phpp.12362>.

Ersoy-Evans, S. (2010). Commentary: Vitamin D and autoimmunity. Is there an association. *Journal of the American Academy of Dermatology*, 62(6), 942–944. <https://doi.org/10.1016/j.jaad.2010.02.009>.

FEDIAF, European Pet Food Industry Federation, (2019). Nutritional Guidelines for complete and complementary pet food for cats and dogs. pp. 96.

Gerber, B., Hässig, M., & Reusch, C. E. (2003). Serum concentrations of 1,25-dihydroxycholecalciferol and 25-hydroxycholecalciferol in clinically normal and dogs with acute and chronic renal failure. *American Journal of Veterinary Research*, 64(9), 1161–1166. <https://doi.org/10.2460/ajvr.2003.64.1161>.

Gow, A. G., Else, R., Evans, H., Berry, J. L., Herrtage, M. E., & Mellanby, R. J. (2011). Hypovitaminosis D in dogs with inflammatory bowel disease and hypoalbuminaemia. *The Journal of Small Animal Practice*, 52(8), 411–418. <https://doi.org/10.1111/j.1748-5827.2011.01082.x>.

Holló, A., Clemens, Z., Kamondi, A., Lakatos, P., & Szűcs, A. (2012). Correction of vitamin D deficiency improves seizure control in epilepsy: A pilot study. *Epilepsy & Behavior*, 24, 131–133. <https://doi.org/10.1016/j.yebeh.2012.03.011>.

How, K. L., Hazewinkel, H. A. W., & Mol, J. A. (1994). Dietary vitamin D dependence of cat and dog due to inadequate cutaneous synthesis of vitamin D. *General and Comparative Endocrinology*, 96, 12–18. <https://doi.org/10.1006/gcen.1994.1154>.

Kang, M. H., Lim, C. Y., & Park, H. M. (2014). Uveodermatologic syndrome concurrent with keratoconjunctivitis sicca in a miniature poodle dog. *The Canadian Veterinary Journal*, 55(6), 585–588.

Karagün, E., Ergin, C., Baysak, S., Erden, G., Aktaş, H., & Ekiz, Ö (2016). The role of serum vitamin D levels in vitiligo. *Advances in Dermatology and Allergology*, XXXIII(4), 300–302. <https://doi.org/10.5114/pdia.2016.59507>.

Kraus, M. S., Rassnick, K. M., Wakshlag, J. J., Gelzer, A. R., Waxman, A. S., Struble, A. M., et al. (2014). Relation of vitamin D status to congestive heart failure and cardiovascular events in dogs. *Journal of Veterinary Internal Medicine*, 28(1), 109–115. <https://doi.org/10.1111/jvim.12239>.

Kriegel, M. A., Manson, J. E., & Costenbader, K. H. (2011). Does vitamin D affect risk of developing autoimmune disease?: A systematic review. *Seminars in Arthritis and Rheumatism*, 40(6), 512–531. <https://doi.org/10.1016/j.semarthrit.2010.07.009>.

Miraglia Del Giudice, M., Indolfi, C., & Striccioli, G. (2018). Vitamin D: Immunomodulatory Aspects. *Journal of Clinical Gastroenterology*, (Suppl. 1), 86–88. <https://doi.org/10.1097/MCG.0000000000001112>.

NRC National Research Council. (2006). *Nutrient Requirements of Dogs and Cats*. Washington, DC: National Academies Press447.

O'Brien, E. A., McMichael, M. A., & Le Boedec, K. (2018). 25-Hydroxyvitamin D concentrations in dogs with naturally acquired blastomycosis. *Journal of Veterinary Internal Medicine*, 32(5), 1684–1691. <https://doi.org/10.1111/jvim.15255>.

Peterson, C. A., & Heffernan, M. E. (2008). Serum tumor necrosis factor-alpha concentrations are negatively correlated with serum 25(OH)D concentrations in healthy women. *Journal of Inflammation*. <https://doi.org/10.1186/1476-9255-5-10>.

Pye, C. C. (2009). Uveodermatologic syndrome in an Akita. *The Canadian Veterinary Journal*, 50(8), 861–864.

Ramagopalan, S. V., Heger, A., Berlanga, A. J., Maugeri, N. J., Lincoln, M. R., Burrell, A., et al. (2010). ChIP-seq defined genome-wide map of vitamin D receptor binding: Associations with disease and evolution. *Genome Research*, 20, 1352–1360. <https://doi.org/10.1101/gr.107920.110>.

Reichler, I. M., Hauser, B., Schiller, I., Dunstan, R. W., Credille, K. M., Binder, H., et al. (2001). Sebaceous adenitis in the Akita: Clinical observations, histopathology and heredity. *Veterinary Dermatology*, 12, 243–253. <https://doi.org/10.1046/j.0959-4493.2001.00251.x>.

Rosa, C. T., Schoeman, J. P., Berry, J. L., Mellanby, R. J., & Dvir, E. (2013). Hypovitaminosis D in Dogs with Spirocerosis. *Journal of Veterinary Internal Medicine*, 27(5), 1159–1164. <https://doi.org/10.1111/jvim.12161>.

Saleh, H. M., Abdel Fattah, N. S., & Hamza, H. T. (2013). Evaluation of serum 25-hydroxyvitamin D levels in vitiligo patients with and without autoimmune diseases. *Photodermatology, Photoimmunology & Photomedicine*, 29, 34–40. <https://doi.org/10.1111/phpp.12362>.

- 1111/phpp.12016.
- Selting, K. A., Sharp, C. R., Ringold, R., Thamm, D. H., & Backus, R. (2014). Serum 25-hydroxyvitamin D concentrations in dogs – correlation with health and cancer risk. *Veterinary and Comparative Oncology*, *14*(3), 295–305. <https://doi.org/10.1111/vco.12101>.
- Sharp, C. R., Selting, K. A., & Ringold, R. (2015). The effect of diet on serum 25-hydroxyvitamin D concentrations in dogs. *BioMed Central Research Notes*, *8*, 444–450. <https://doi.org/10.1186/s13104-015-1360-0>.
- Smolders, J., Menheere, P., Kessels, A., Damoiseaux, J., & Hupperts, R. (2008). Association of vitamin D metabolite levels with relapse rate and disability in multiple sclerosis. *Multiple Sclerosis*, *14*(9), 1220–1224. [10.1177/1352458508094399](https://doi.org/10.1177/1352458508094399).
- Spoor, J. W., Downey, R. L., Griffiths, C., Horst, R. J., Levine, C. B., Childs, R. M., et al. (2015). Plasma Vitamin D metabolites and C-reactive protein in stage-stop racing endurance sled dogs. *Journal of Veterinary Internal Medicine*, *29*, 519–525. <https://doi.org/10.1111/jvim.12546>.
- Titmarsh, H. F., Gow, A. G., Kilpatrick, S., Cartwright, J. A., Milne, E. M., Philbey, et al. (2015). Low vitamin D status is associated with systemic and gastrointestinal inflammation in dogs with a chronic enteropathy. *PLoS One*, *10*(9), Article e0137377. <https://doi.org/10.1371/journal.pone.0137377>.
- Upala, S., & Sanguankee, A. (2016). Low 25-hydroxyvitamin D levels are associated with vitiligo: A systematic review and meta-analysis. *Photodermatology, Photoimmunology & Photomedicine*, *32*, 181–190. <https://doi.org/10.1111/phpp.12241>.
- Wakshlag, J. J., Rassnick, K. M., Malone, E. K., Struble, A. M., Vachhani, P., Trump, D. L., et al. (2011). Cross-sectional study to investigate the association between vitamin D status and cutaneous mast cell tumours in Labrador retrievers. *The British Journal of Nutrition*, (Suppl. 1), 60–63. <https://doi.org/10.1017/S000711451100211X>.
- Weidner, N., & Verbrugghe, A. (2017). Current knowledge of vitamin D in dogs. *Critical Reviews in Food Science and Nutrition*, *57*(18), 3850–3859. <https://doi.org/10.1080/10408398.2016.1171202>.
- Xianglong, Y., Peizeng, Y., Min Sun, Y. Y., & Fuzhen, L. (2011). Decreased 1,25-dihydroxyvitamin D3 level is involved in the pathogenesis of Vogt-Koyanagi-Harada (VKH) disease. *Molecular Vision*, *17*, 673–679.