

# Comparison between synovial fluid cytology and joint capsule histopathology in horses with chronic osteochondritis dissecans



IRENE NOCERA<sup>1</sup>, VALENTINA VITALE<sup>2</sup>, SIMONETTA CITI<sup>1</sup>,  
GIULIA MARIANELLI<sup>3</sup>, ALESSANDRO POLI<sup>1</sup>, FRANCESCA BONELLI<sup>1</sup>,  
MELANIE PIERRE<sup>1</sup>, MICAELA SGORBINI<sup>1</sup>

<sup>1</sup> Ospedale Didattico Veterinario “Mario Modenato”, Dipartimento Scienze Veterinarie, Università di Pisa

<sup>2</sup> Veterinary Teaching Hospital, Sydney School of Veterinary Science, The University of Sydney,  
410 Werombi Road, Camden, NSW, Australia

<sup>3</sup> Private veterinarian, Pisa, Italy

## SUMMARY

**Introduction and objective** - The osteochondrosis dissecans (OCD) is a disease that affects humans and animals and its aetiology and pathogenesis have been investigated for long time in human and veterinary medicine. OCD can cause slight changes in viscosity, mild increase in total protein and mild to severe increase in cell count, depending on the stage of the disease, in the synovial fluid of affected joint. Histological examination of the articular cartilage of horses with OCD showed areas of disorganization with reduction of glycosaminoglycans, including chondroitin sulphate, compared to normal horses. The purpose of the present work was to study the relationship between synovial fluid cytology and histopathologic examination of the articular capsule of horses with OCD.

**Materials and methods** - Fifteen horses of different breed, age and sex with OCD were included in the study and all of them underwent arthroscopy. Synovial fluid samples and osteochondral, or synovial capsule, samples were collected from 22 joints affected by OCD during arthroscopic surgery. For each synovial fluid sample was assessed the following parameters: synovial fluid turbidity, viscosity, mucin clot, total protein (TP), total nucleated cell count (TNCC) and differential cell count. Furthermore, osteochondral or synovial capsule samples were evaluated on histologic examination. The samples were retrospectively divided into two groups according to the results of the differential cell count of synovial fluid: a) group 1: hypocellular synovial fluid (few lymphocytes); b) group 2: cellular synovial fluid. Data were expressed as average and standard deviation. T-test was applied to verify differences between group 1 vs 2 for TNCC and TP, while chi-square test was used for turbidity, viscosity and mucin clot test.

**Results** - Ten/22 joint samples were classified into the group 1 and 12/22 into the group 2. No significant differences were found between the 2 groups for turbidity, viscosity and mucin clot, while differences were obtained for TNCC and TP. Histological examination was normal in 16/22 joints and abnormal in 6/22.

**Conclusions** - The lower viscosity, abnormal mucin clot test and increasing in turbidity might be related to a dysregulation of pathways involving inflammation, and matrix damage, similar to those found in osteoarthritis. Comparing the two groups, TP were higher in the group 2 vs group 1, supporting the hypothesis of different grade of inflammation in the two group (low vs mild). Synovial TNCC results and the cytological assessment are suggestive of degenerative inflammatory changes in both groups. The prevalences of histological alterations support the hypothesis that the histological evaluation of the cartilages is not useful in the diagnosis of degenerative joint diseases, in line with previous studies. In conclusion, the assessment of synovial fluid cytology seems to be more sensitive than the histological exam in the diagnosis of degenerative joint diseases, as reported by others (4).

## KEY WORDS

Synovial fluid; OCD; Horse; Cytology; Histology.

## INTRODUCTION

Osteochondrosis (OC) is a multifocal pathology, which takes place in both articular-epiphyseal cartilage complex and growth plate in a variety of mammalian species<sup>1,2,3</sup>. The disorder is characterized by failure of endochondral ossification and is considered as one of the most common primary causes of degenerative joint disease in domestic animals<sup>2-6</sup>. OC has been believed to be caused by a combination of factors<sup>6-7</sup> such as traumatic lesions, ischemia and failure

of cartilaginous canals and blood vessels, dyschondroplasia and alteration of the cartilaginous matrix, rapid growth, heredity and dietary imbalances<sup>8</sup>.

One of the most recurrent manifestations of OC is the osteochondrosis dissecans (OCD)<sup>2</sup>. It is a non-septic degenerative disease caused by a failure of cellular differentiation in growing cartilage, leading to its dramatic thickening or retention, emergence of fissures and eventual focal loss of cartilage flaps into the joint cavity<sup>9-10</sup>. The detached fragments may be responsible of severe joint inflammation, which can lead to subsequent development of secondary osteoarthritis (OA)<sup>2,11-12</sup>.

OCD clinical signs may develop when the joint surface is involved by the dissecting lesions<sup>2</sup>. Sometimes the OCD frag-

Corresponding Author:

Irene Nocera (irene.nocera@vet.unipi.it).

ments and debris released into the joint lead to synovitis, joint inflammation and clinical signs of pain and lameness<sup>2,13</sup>. In some cases, no defect in the subchondral bone are present, no evident clinical signs of the disease can be pointed out<sup>2,13</sup>.

OCD medical treatment depends on the severity of the disease. Some younger foals with larger cartilage flaps and little subchondral bone attachment may be amenable to reattachment to underlying subchondral bone via arthroscopically placed polydioxanone (PDS) pins<sup>13</sup>. In some cases, treatment with mesenchymal stem cells, platelet-rich plasma, or other biologics may be appropriate, depending on the type of OC lesion<sup>13</sup>. Arthroscopic removal of osteochondral chips or fragments is generally recommended after foals have reached a year of age, reducing predominant intra-articular fractures and accurately diagnosing ligamentous and meniscal lesions<sup>2,14</sup>.

When alterations occur in the articular cartilage, meniscus, ligament or synovial membrane, some molecules may be released into the synovial fluid, whereas the biomarkers of bone tissue will generally be released into the blood, if the underlying bone of a joint is involved<sup>13,15-16</sup>.

Analysis of cartilaginous explants bearing OCD lesions as well as serum and synovial biomarker measurements of animals suffering from OCD, revealed a significant increase in collagen turnover<sup>14,16-17</sup>. Synovial fluid biomarkers associated with OC are mainly products of collagen (CPII:C2C) and proteoglycan degradation products, mainly represented by Chondroitin Sulphate epitope 846 (CS846) and glycosaminoglycan (GAG)<sup>2,13,16</sup>.

These biomarkers linearly correlate with severity grade of osteochondral lesions, indicate that this epitope is closely associated with OCD and suggest involvement of increased synthesis of cartilaginous aggrecan and procollagen type II during the pathophysiological development of this condition<sup>6,18</sup>. Histopathological results from articular cartilage samples reveal pathological cellular changes represented by increased cell volume, cell death, proteolysis of collagen and thus the reduction of its content in early OC<sup>18</sup>. Lecocq and colleagues (2008)<sup>7</sup> demonstrated that type II collagen synthesis is altered in OC cartilage and may be an initiating factor in weakening of cartilage matrix near cartilage canals and the osteochondral junction. Increased expression of matrix metalloproteinase (MMP-13 and MMP-3) may also results in biomechanical weakening of matrix in these locations<sup>16,19-20</sup>.

The aim of the present study was to assess synovial fluid cytology and histopathological articular cartilage samples for the detection of OCD in horses.

## MATERIALS AND METHODS

A cohort of 15 horses affected by OCD were included in this two-years study (2009-2010). Seven out of fifteen were female, five out of fifteen were male and three out of fifteen were geldings. The median age was 3 years (range 1-7 years). Eight/15 horses were Trotters, 4/15 Thoroughbreds and 3/15 were Warmbloods.

All the horses underwent orthopaedic visit and local anaesthesia in order to recognise the specific lesion location; after that the x-ray exam and the arthroscopy surgery were performed for each pathological joint, in order to remove OCD fragments. During surgical procedures, the synovial fluid and histopathological articular cartilage samples were collected

from 22 pathological joint. The synovial fluid was collected in plain tubes without anticoagulant and in EDTA tubes and analysed within 1h after collection. Mucin clot test and total protein (TP) concentration were evaluated using samples collected in plain tubes<sup>15,21-22</sup>.

TP were assessed using a refractometer<sup>21-22</sup>. Turbidity, viscosity and Total Nucleated Cell Count (TNCC) were evaluated using synovial fluid samples collected in EDTA tubes<sup>15</sup>. Turbidity and viscosity were qualitative assessed by others<sup>21-22</sup>. TNCC was quantified after hyaluronidase treatment<sup>23</sup> to reduce viscosity using an automated cell counter (Hecovet C 01030360/ITA, and CAL-SEAC 71010810 multiparametric haematology calibrator, SEAC-RADIM Co, Italy). Cytological smears were prepared starting from EDTA synovial fluid samples. Smears were cytocentrifuged at 1500 gpm for 5 minutes (Cytofuge 2, StatSpin, USA) to improve smear quality<sup>23</sup>, air-dried, coloured using a modified Romanowsky staining technique (Diff Quik®, DADA, Milan) and observed at 40X and 100X for differential cell count evaluation (expressed as percentage)<sup>15,21-23</sup>.

Two groups were retrospectively and arbitrarily detected, based on differential cell count. Group 1: hypocellular synovial fluid (few lymphocytes); b) group 2: cellular synovial fluid (presence of inflammatory cells).

Histopathological articular cartilage samples were stored in 10% formalin solution and routinely processed. Histologic smears were stained with haematoxylin and eosin and observed at 10X and 20X.

Data relating TP, TNCC, and differential cells count were expressed as mean and standard deviation. Differences between group 1 vs 2 were assessed using a T-test for unpaired data for TP and TNCC. The Chi-Square test with Yates correction, was applied to compare group 1 vs 2 for turbidity, viscosity and mucin clot test. Significance level was set at  $P < 0.05$ . Statistical analysis was performed with a commercial software.

## RESULTS

No lameness and/or no joint effusion were detected in 5/15 horses (33.3%), while 10/15 horses (66.7%) were lame. Twenty-two pathological joint were detected: 15/22 were tarsocrural joint (68.2%); 4/22 were hind limb fetlock joints (18.2%); 2/22 were front limb fetlock joints (9.1%); 1/22 was distal interphalangeal joint in front limb (4.5%). Only one pathological joint was detected in 9/15 horses (60%), 5/15 (33.3%) subjects showed two pathological joints and 1/15 (6.7%) had three pathological joints (Table 1).

No statistically differences were found between group 1 vs 2 for turbidity, viscosity and mucin clot test. Synovial fluid turbidity was found increased in 16/22 joint (72.7%) and normal in 6/22 (27.3%). Synovial fluid viscosity was found lower in 8/22 joints (36.4%) and normal in 14/22 (63.6%). Mucin clot test was resulted lower in 2/22 joints (9.1%) and normal in 20/22 (90.9%).

Ten out of 22 (45.5%) articular samples were included in group 1 and 12/22 (54.5%) in group 2. Data on synovial TP, TNCC (groups 1 and 2) and leukocyte cells (neutrophils, macrophages, lymphocytes) (group 2) were reported in Table 2. TNCC for both groups 1 and 2 and the percentage of inflammatory cells for group 2 were within reference in-

**Table 1** - Lesions' distribution within the cohort of 15 horses included in the study.

Horses	Tarso-cruiral Joint	Fore Fetlock Joint	Hind Fetlock Joint	Fore Distal Interphalangeal Joint
1	Present	-	-	-
2	Present	-	-	-
3	Present	-	Present	-
4	Present	-	-	-
5	Present	-	Present	-
6	Present	-	-	Present
7	Present	-	-	-
8	Present	-	-	-
9	Present	Present	Present	-
10	Present	-	-	-
11	Present	-	-	-
12	Present	-	-	-
13	Present	-	Present	-
14	Present	-	-	-
15	Present	Present	-	-

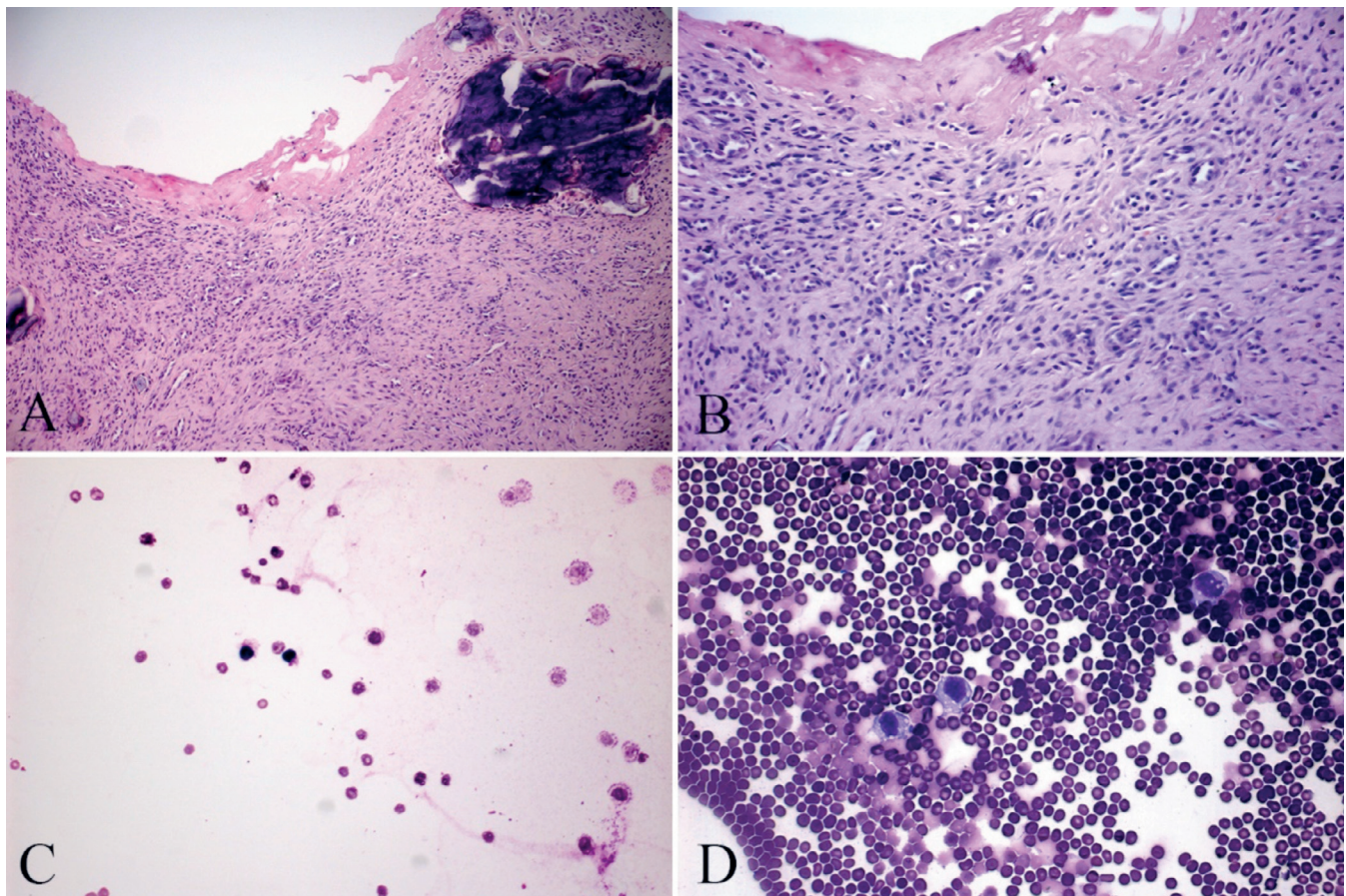
**Table 2** - Data on synovial total protein concentration (TP), total nucleated cell count (TNCC) and leukocyte cells (neutrophils, macrophages, lymphocytes) were reported.

	Group 1	Group 2
TP (gr/dL)	2.2±1.2*	2.2±0.9*
TNCC (cells/μL)	216±185*	433±115*
Neutrophils	0±0	9±11.9
Macrophages	0±0	25.4±11.1
Lymphocytes	1±0.1	65.7±14.2

Legend: \* within the same row means ≠.

tervals<sup>23</sup> for all the joint analysed. Statistical differences were found between group 1 vs 2 for TP and TNCC. Figure 1C and D showed synovial fluid cytology of one horse owned to group 1 and 2, respectively.

Histopathological articular cartilage samples were found normal in 16/22 joints (72.7%) and abnormal in 6/22 (27.3%). Bone inflammation was present in 3/6 joints (50%); in 2/6 joints (33.3%) fibrous cartilage was detected; 1/6 joints (16.7%) showed fibrous cartilage degeneration and synovial membrane inflammation. All the horses with abnormal histopathological findings belonged to group 2 (Figure 1A, B).



**Figure 1** - **A)** The articular biopsy of one horse, included in group 2. Synovial surface necrosis and thickening of the articular capsule, due to stromal cells proliferation, with bony metaplasia areas (Hematoxylin-Eosin., Ob. 10X). **B)** The articular biopsy of one horse, included in group 2. It represents Figure 1A higher magnification. Histological exam shows stromal cells proliferation of the articular capsule, evident neoangiogenesis and chronic inflammation, represented by macrophages small lymphocytes and mature neutrophil (Hematoxylin-Eosin., Ob. 20X). **C)** The synovial fluid cytological exam of one horse, included in group 1. Slight background colouring due to high protein component. The smear shows red blood cells and few small lymphocytes (Diff Quik, Ob 40X). **D)** The synovial fluid cytological exam of one horse, included in group 2. Numerous red blood cells and macrophages, with many vacuoles within the cytoplasm, mature neutrophil and small size lymphocytes (Diff-Quik, Ob 40X).

## DISCUSSION AND CONCLUSION

During pathological processes of joint diseases, the articular environment dramatically changes due to synovial membrane impairment<sup>12-13;21</sup>. In particular, synovial fluid GAG (i.e. hyaluronic acid and chondroitin sulphate) concentration increased, and molecular weight of hyaluronic acid and fluid viscosity decreased<sup>14</sup>. Diagnosis usually is performed based on clinical signs and diagnostic imaging.

The assessment of synovial fluid turbidity, viscosity and mucin clot test, the fluid cellularity (TNCC, differential cell count) and the TP concentration are important to differentiate septic or degenerative joint diseases.

One of the most frequent degenerative joint diseases in the horse is OCD. This pathology affects 20,000 to 25,000 foals every year in the northwestern Europe; therefore, it is one of the most important of the so-called 'developmental orthopaedic diseases' in horses<sup>2</sup>.

The aim of the present study was to assess synovial fluid cytology and histopathological articular cartilage samples for the detection of OCD in horses.

All the horses affected by OCD and included in this study showed TNCC and differential cell count values, and TP concentration compatible with the diagnosis of a degenerative joint disease<sup>22</sup>, such the OCD.

No differences in viscosity and turbidity and mucin clot test have been found between horses with hypocellular or cellular synovial fluid. In particular, viscosity and mucin clot test were decreased, and turbidity was increased in both groups with similar prevalences' distribution. These results are in agreement with literature<sup>21-22</sup>. The alteration of the quality of synovial fluid usually is due to the presence of fibrin and/or cartilage fragments within articular space, but the inflammation is low-mild in degenerative joint diseases than to septic ones<sup>21</sup>. The lower viscosity, abnormal mucin clot test and increasing in turbidity might be related to a dysregulation of pathways involving inflammation, and matrix damage, similar to those found in osteoarthritis<sup>13</sup>.

Total protein concentrations did not exceed 3 gr/dL concentration<sup>15;21-22</sup>. This finding is consistent with other studies<sup>22</sup> and it agrees with normal value found during degenerative joint disease. Comparing the two groups, TP were higher in the group 2 vs group 1, supporting the hypothesis of different grade of inflammation in the two group (low vs mild). Synovial TNCC was found to be less than 600 cells/ $\mu$ L in both groups and the cytological exam detects no significant neutrophilic percentage. According to the literature, these results are suggestive of degenerative inflammatory changes<sup>15;22</sup>.

Finally, the histological exam did not show pathological alterations in 72.7% examined joint, while it revealed pathological lesions in 27.3%. These prevalences are in line with previous studies<sup>2;6</sup> assessing the histological alterations of cartilage in degenerative joint diseases. Our results seem to support the hypothesis that the histological evaluation of the cartilages is not useful in the diagnosis of degenerative joint diseases. Probably this is due to difficulties in sampling a truly representative slice of the whole articular cartilage surface<sup>8</sup>.

In conclusion, the assessment of synovial fluid cytology seems to be more sensitive than the histological exam in the diagnosis of degenerative joint diseases, as reported by others<sup>21</sup>.

## ACKNOWLEDGMENTS

The authors thank private veterinarians for the collaboration in the collection of samples.

## References

1. Ytrehus B., Ekman S., Carlson C.S., Teige J., Reinholt F.P. (2004). Focal changes in blood supply during normal epiphyseal growth are central in the pathogenesis of osteochondrosis in pigs. *Bone*, 5: 294-306.
2. Bourebaba L., Röcken M., Marycz K. (2019). Osteochondritis dissecans (OCD) in Horses-Molecular Background of its Pathogenesis and Perspectives for Progenitor Stem Cell Therapy. *Stem Cell Rev and Rep*, 15: 374-390.
3. Levi M., Dittmer K.E., Gentile A., Beltrame A., Bolcato M., Morgante M., Fiore E., Benazzi C. (2017). Growth plate lesions of fattening bulls. *Vet Pathol*, 54: 437-444.
4. Fiore E., Levi M., Giancesella M., Benazzi C., Morgante M., Beltrame A., Vaccaro C., Gentile A. (2016). Epiphysitis in fattening bulls: radiological and pathologic findings. *Large Anim Rev*, 22: 43-45.
5. Jeffcott L.B., Henson F.M.D. (1998). Studies on growth cartilage in the horse and their application to aetiopathogenesis of dyschondroplasia (osteochondrosis). *Vet J*, 156: 177-192.
6. Laverty S., O'Kouneff S., Ionescu M., Reiner A., Pidoux I., Webber C., Rossier Y., Billingham R.C., Poole A.R. (2002). Excessive degradation of type II collagen in articular cartilage in equine osteochondrosis. *J Orthop Res*, 20: 1282-1289.
7. Lecocq M., Girard C.A., Fogarty U., Beauchamp G., Richard H., Laverty S. (2008). Cartilage matrix changes in the developing epiphysis: early events on the pathway to equine osteochondrosis? *Equine Vet J*, 40: 442-454.
8. Ytrehus B., Carlson C.S., Ekman S. (2007). Etiology and pathogenesis of osteochondrosis. *Vet Pathol*, 44: 429-448.
9. Brink P., Skydsgaard M., Teige J., Tverdal A., Dolvik N.I. (2010). Association between clinical signs and histopathologic changes in the synovium of the tarsocrural joint of horses with osteochondritis dissecans of the tibia. *Am J Vet Res*, 71: 47-54.
10. De Grauw J.C., Brama P.A., Wiemer P., Brommer H., Van de Lest C.H., Van Weeren P.R. (2006). Cartilage-derived biomarkers and lipid mediators of inflammation in horses with osteochondritis dissecans of the distal intermediate ridge of the tibia. *Am J Vet Res*, 67: 1156-1162.
11. Laverty S., Girard C. (2013). Pathogenesis of epiphyseal osteochondrosis. *Vet J*, 197: 3-12.
12. Caron J.P. (2011). Osteoarthritis. In: *Diagnosis and management of lameness in the horse*, Eds. Ross M.W., Dyson S.J., 2nd ed., 655-668, Elsevier Saunders, USA.
13. Semevolos, S.A. (2017). Osteochondritis Dissecans Development. *Vet Clin North Am Equine Pract*, 33: 367-378.
14. Machado T.S.L., Correia da Silva L.C., Baccarin R.Y.A., Michelacci Y.M. (2012). Synovial fluid chondroitin sulphate indicates abnormal joint metabolism in asymptomatic osteochondritic horses. *Equine Vet J*, 44: 404-411.
15. Mahaffey E.A. (2002). Synovial Fluid. In: *Diagnostic and Hematology of the horse*, Eds. Cowell R.L., Tyler R.D., 2nd ed, 163-170, Mosby Inc, USA.
16. Wauters J., Pille F., Martens A., Franck T., Serteyn D., Gasthuys F., Meyer E. (2013). Equine myeloperoxidase: a novel biomarker in synovial fluid for the diagnosis of infection. *Equine Vet J*, 45: 278-283.
17. Ribera T., Monreal L., Delgado M.A., Rios J., Prades M. (2013). Synovial fluid D-dimer concentration in horses with osteochondritis dissecans and osteoarthritis. *Vet Comp Orthop Traumatol*, 26: 54-60.
18. Bertone A.L., Bramlage L.R., McIlwraith C.W., Malesud C.L. (2005). Comparison of proteoglycan and collagen in articular cartilage of horses with naturally developing osteochondrosis and healing osteochondral fragments of experimentally induced fractures. *Am J Vet Res*, 66: 1881-1890.
19. Trumble T.N., Trotter G.W., Oxford J.R.T., McIlwraith C.W., Cammarata S., Goodnight J.L., Billingham R.C., Frisbie D.D. (2001). Synovial fluid gelatinase concentrations and matrix metalloproteinase and cytokine expression in naturally occurring joint disease in horses. *Am J Vet Res*, 62: 1467-1477.
20. Al-Hizab F., Clegg P.D., Thompson C.C., Carter S.D. (2002). Microscopic localization of active gelatinases in equine osteochondritis dissecans (OCD) cartilage. *Osteoarthritis Cartilage*, 10: 653-661.
21. McIlwraith C.W. (2002). Diseases of Joints, Tendons, Ligaments and Related Structure. In *Adam's lameness in horse*, Stashak T.S., 5th ed, Lippincott Williams & Wilkins, USA.
22. Steel C.M. (2008). Equine synovial fluid analysis. *Vet Clin Equine*, 24: 437-454.
23. Moreno M.J., Clayburne G., Schumacher H.R. Jr (2000). Processing of noninflammatory synovial fluids with hyaluronidase for cytopspin preparations improves the accuracy of differential counts. *Diagn Cytopathol*, 22: 256-258.