



## Helix Thigh Lift. A Novel Approach to Severe Deformities in Massive Weight Loss Patients

Luigi Losco, Ana Claudia Roxo, Carlos Weck Roxo, Alessandro de Sire, Alberto Bolletta, Roberto Cuomo, Luca Grimaldi, Emanuele Cigna & Carlos del Pino Roxo

To cite this article: Luigi Losco, Ana Claudia Roxo, Carlos Weck Roxo, Alessandro de Sire, Alberto Bolletta, Roberto Cuomo, Luca Grimaldi, Emanuele Cigna & Carlos del Pino Roxo (2021): Helix Thigh Lift. A Novel Approach to Severe Deformities in Massive Weight Loss Patients, Journal of Investigative Surgery, DOI: [10.1080/08941939.2021.1912220](https://doi.org/10.1080/08941939.2021.1912220)

To link to this article: <https://doi.org/10.1080/08941939.2021.1912220>



© 2021 The Author(s). Published with license by Taylor & Francis Group, LLC.



Published online: 24 May 2021.



Submit your article to this journal [↗](#)



Article views: 58

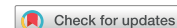

View related articles [↗](#)





View Crossmark data [↗](#)

ORIGINAL RESEARCH



## Helix Thigh Lift. A Novel Approach to Severe Deformities in Massive Weight Loss Patients

Luigi Losco, MD<sup>a,b</sup> , Ana Claudia Roxo, MD, PhD<sup>c</sup>, Carlos Weck Roxo, MD<sup>b</sup>, Alessandro de Sire, MD<sup>d,e</sup> , Alberto Bolletta, MD<sup>a</sup>, Roberto Cuomo, MD<sup>f</sup>, Luca Grimaldi, MD<sup>f</sup>, Emanuele Cigna, MD, PhD<sup>a</sup> and Carlos del Pino Roxo, MD<sup>b</sup>

<sup>a</sup>Plastic Surgery Unit, Department of Translational Research and New Technologies in Medicine and Surgery, University of Pisa, Pisa, Italy; <sup>b</sup>Plastic Surgery Unit, Andaraí Federal Hospital, Rio de Janeiro, Brazil; <sup>c</sup>Plastic Surgery Unit, Pedro Ernesto University Hospital, Rio de Janeiro, Brazil; <sup>d</sup>Physical and Rehabilitative Medicine, Department of Health Sciences, University of Eastern Piedmont, Novara, Italy; <sup>e</sup>Rehabilitation Unit, Mons. L. Novarese Hospital, Moncrivello, Italy; <sup>f</sup>Unit of Plastic and Reconstructive Surgery, Department of Medicine, Surgery and Neuroscience, University of Siena, Siena, Italy

### ABSTRACT

**Background:** After massive weight loss, the severe gynoid body contour deformities are not always faceable with optimal results. The thigh is one of the most demanding area to address; therefore, the approach should be virtually individualized. The authors describe the helix thigh lift: A novel technique that combines vertical with horizontal axis of pull. The goal of this ultimate customization is to dramatically impact physical functioning and esthetics of this patient population. **Methods:** Thigh lift patients from 2016 to 2019 were assessed retrospectively; fourteen patients were selected for helix thigh lift procedure. Preoperative markings, surgical technique and outcomes were described. The mean follow-up time was 14.8±3.2 months. A questionnaire was administered to evaluate the results.

**Results:** Fourteen female patients (mean age, 42±4.8 years) underwent helix thigh lift after massive weight loss. The overall complication rate was 36 percent. They were all minor complications and were treated in an outpatient setting. Seroma formation was the most frequent, at 29 percent. No skin necrosis was reported. Complication development was straight related to the age of the patient ( $p=0.0455$ ). The patients were very satisfied with the overall outcome.

**Conclusions:** Helix thigh lift effectively addresses the severe gynoid body contour deformities. The high satisfaction and the reasonable complication rate suggest that this is a safe and effective technique. The age of the patient was significantly associated to complication development. A dramatic improvement of ease in performing activities of daily living along with reduction of the skin problems leads to significant improvement of the quality of life.

### ARTICLE HISTORY

Received 18 January 2021  
Revised 03 March 2021  
Accepted 27 March 2021

### KEYWORDS



Thigh lift; massive weight loss; plastic surgery; body contouring; medial thighplasty

## Introduction


Bariatric surgery is still the most powerful and reliable method for achieving long-term weight loss and resolution of comorbidities. However, a long-term nutritional supplementation could be necessary due to the post-operative malabsorption, especially in older people that are commonly at higher risk of sarcopenia and malnutrition [1–5].

Redundancy of skin and adipose tissue is both a functional and esthetic issue, especially in the lower extremities. Those deformities lead to skin maceration and interfere with dressing, walking and sexual activity; furthermore, the quality of life may be impaired, and some psychosocial illness could be triggered (i.e. depression) [6, 7]. The severity of contour deformities is unpredictable and depends on many factors such as age, gender, pre-surgery appearance, rate and speed of weight loss.

The classic medial thigh lift has some significant drawbacks in the treatment of massive weight loss (MWL) population [8–10]; moreover, according to our experience, a severe deformity is not always faceable with the traditional full-length vertical thighplasty with acceptable results. A gynoid or pear-shaped body contour deformity involving a severe slackness of the whole thigh circumference with multiple posterior-lateral skin folds and associated to massive lipodystrophy has been named *pancake stack deformity* (Figures 1 and 2). In those cases, we aim to achieve true benefits: prevention of maceration, increased ease in performing activities of daily living and an improvement of the quality of life. We present our technique, the helix thigh lift. It is another step in the series of tailored thigh contouring surgery [11]; the helix-shaped skin excision combined vertical with horizontal axis of pull. The vertical vector was moved distally than the one advocated by Lockwood [8], and a whole skin fold was removed;

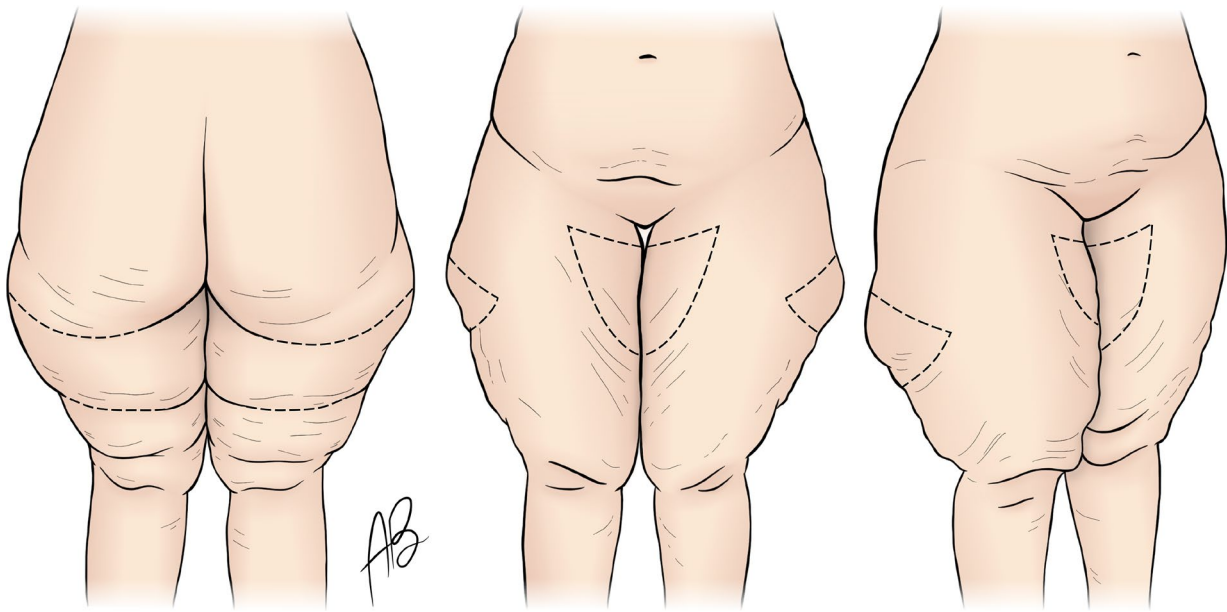
**CONTACT** Luigi Losco  [luigi.losco@gmail.com](mailto:luigi.losco@gmail.com)  Department of Translational Research and New Technologies in Medicine and Surgery, University of Pisa, Via Roma 67, 56125 Pisa, Italy.

\*Luigi Losco and Ana Claudia Roxo contributed equally to this work.

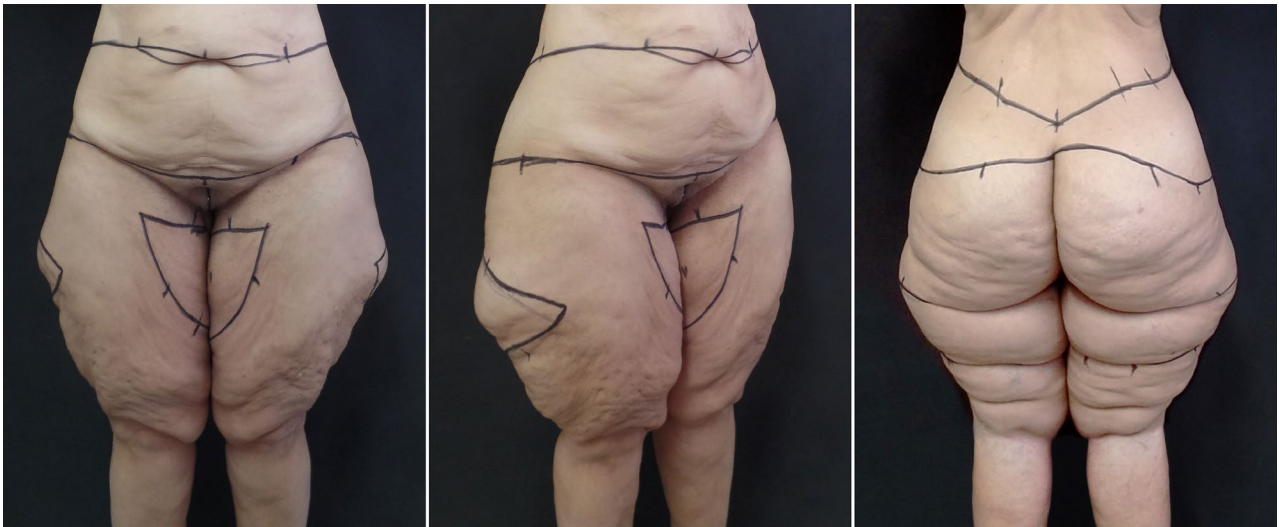
 Supplemental data for this article can be accessed online at <https://doi.org/10.1080/08941939.2021.1912220>.

© 2021 The Author(s). Published with license by Taylor & Francis Group, LLC.

This is an Open Access article distributed under the terms of the Creative Commons Attribution-NonCommercial-NoDerivatives License (<http://creativecommons.org/licenses/by-nc-nd/4.0/>), which permits non-commercial re-use, distribution, and reproduction in any medium, provided the original work is properly cited, and is not altered, transformed, or built upon in any way.



**Figure 1.** Preoperative markings of the helix thigh lift. The incision lines lie in the gluteal crease and the middle transverse thigh fold (left picture). The marked fold has to be pinched to simulate skin closure with no undermining. The surgical markings are tapered upwards over the anterolateral region of the thigh. On the medial aspect, a pinch test is used to assess the amount of skin excess. The anterior medial markings are tapered toward, but do not reach the inguinal crease (they stop about 2–3 cm distally) (middle and right pictures). See Supplemental Digital Content 1 - Video.



**Figure 2.** A 39-year-old woman is seen preoperatively. The helical shape of the incision allows skin flaps to maintain perfusion (left and middle pictures); judicious liposuction is performed just on the areas to be excised. The *pancake stack deformity* is evident on the posterior view: The markings are barely visible due to the severity of skin folds (right picture). The surgery was combined with a lower body lift.

moreover, a judicious liposuction avoided any potential injury to venous and lymphatic structures. We described a comprehensive procedure to address the complex *gynoid thigh* that is both safe and effective.

### Patients and methods

A retrospective study investigated MWL patients treated for body contouring from June 2016 to January 2019. The study was approved by the Brazilian National Research Ethics

Committee (CONEP) - authorization code: CEP-HFB 22/1. The inclusion criteria for the helix thigh lift were massive lipodystrophy and skin excess affecting the thigh in its entirety; furthermore, all the patients presented with an associated deformity of the hips and buttocks. Fourteen patients underwent a helix thigh lift consisting of resection of the posterior, medial and lateral thigh skin combined with liposuction. A lower body lift procedure was offered to all patients in order to address also the laxity of the lower trunk in a single stage; surgical procedures were performed by the Senior Author. All patients had experienced MWL by

**Table 1.** Patients and procedures.

Variable	Value (rate)
Patients	14
Age, years	
Mean $\pm$ SD	42 $\pm$ 4.8
Range	36–51
Gender	
Female	14
History of bariatric surgery	14
Surgical Technique	
Combined LB - HT	14
Tobacco use	6 (43%)
Pre-surgery BMI, kg/m <sup>2</sup>	
Mean $\pm$ SD	27.9 $\pm$ 0.8
Range	26.7–29.1
Overall operative time, min	
Mean $\pm$ SD	243 $\pm$ 16
Range	210–260
Drain removal, days	
Mean $\pm$ SD	6.7 $\pm$ 1.1
Range	5–8
Length of Hospitalization, days	
Mean $\pm$ SD	2.1 $\pm$ 0.4
Range	2–3
Follow up, months	
Mean $\pm$ SD	14.8 $\pm$ 3.2
Range	12–22

BMI, body mass index; LB, lower body lift; HT, Helix thigh lift.

bariatric surgery at least 12 months before the contouring procedure, and their weight loss had plateaued over a 3-month period; they were nonsmokers or were asked to stop smoking 30 days before surgery. One week before the surgery, patients were provided with a detailed description of the operation to make sure that they clearly understood the magnitude of the procedure and the location of the scars; a written consent was obtained from all the patients.

The following data were collected: age, sex, body mass index before plastic surgery, history of smoking, concomitant procedures, operative time, duration of hospital stay and complications (Table 1). All the potential complications related to helix thigh lift including seroma, hematoma, surgical site infection, wound dehiscence and skin necrosis were assessed. Furthermore, edema and surgical revision for any reason were rated.

A questionnaire was administered to evaluate the results at 12 months post-operatively. Our grading scale consists of numbers running from 1 to 10 (1–2: very unsatisfied; 3–4: unsatisfied; 5–6: fair; 7–8: satisfied; 9–10: very satisfied) about 5 domains: satisfaction with thighs, satisfaction with hips and buttocks, scar visibility, scar quality, overall satisfaction. The assessment was done by the patients, by the surgical team and by an independent plastic surgeon.

### Preoperative markings

The gluteal crease was marked; that was the uppermost extent of the excised tissue. The caudal extent of tissue resection was the middle transverse thigh fold. The marked saddlebag was pinched to simulate skin closure with no undermining. The surgical markings were tapered upwards over the anterolateral region of the thigh in order to obtain a tension-free wound closure while achieving a pleasing contour with a fold-targeted excision. On the medial aspect,

a pinch test was used to assess the amount of skin excess. The pinching maneuver outlined the direction to connect the anterior to posterior markings. The anterior medial excision was tapered toward, but did not reach the inguinal crease (it stopped about 2–3 cm distally) (Figures 1 and 2 and see Video, Supplemental Digital Content 1, in which the senior author outlines the surgical markings of a helix thigh lift, and the intraoperative key steps are shown.).

If the helix thigh lift is combined with lower body lift or abdominoplasty this should be taken into account while performing the surgical markings. In our series, the lower body lift drawings were performed first; then, while the assistant pinched the skin simulating the skin resection of the trunk, the leading surgeon completed the markings. Careful preoperative markings are paramount to provide an effective guide for the surgeon during the excisional stage of the procedure.

### Surgical technique

The surgical procedure was combined with a lower body lift using a prone-to-supine approach. Tumescant solution was infiltrated in the area to be resected, and judicious liposuction was undertaken with a 3- or 4-mm blunt-tip cannula. We did not perform any liposuction outside the area of resection. The skin along the posterior markings was incised. The epidermis and upper part of dermis was incised with scalpel while the rest of operation was carried out by cautery minimizing the blood loss and shortening the operative time [12]. At the posterior aspect of the thigh, the dissection was performed at the level of the muscle fascia; then, in the region of the gluteal fold, it stopped at the level of the superficial fascial system (SFS). The anterior markings were incised after the patient was turned to the supine position. In the medial thigh, the dissection was carried out more superficial to avoid any risk of lacerating the lymphatic collectors of the ventromedial bundle. Contrarily, on the posterior aspect of the thigh the excision could be more liberal, but still a moderate quantity of areolar adipose tissue was left above the deep fascia to improve the thigh shape.

The design resulted in tension-free closure. No direct undermining of any skin margins was performed. In the posterolateral aspect of the thigh the wounds were closed in three layers: SFS with interrupted 0 vicryl, dermis with 3-0 monocryl suture, and 3-0 nylon for the subcuticular stitch. In the anteromedial aspect, the SFS was sutured with interrupted 2-0 vicryl, dermis with 4-0 monocryl and the skin was closed with interrupted nylon suture (3-0). One closed suction drain was inserted in all thighs. Surgical wounds were covered with mesh tape and cyanoacrylate glue to prevent contamination.

### Perioperative care

Antibiotic prophylaxis was administered. A second-generation cephalosporin was given intraoperatively and for seven days. There was no need for dressing change, as the wounds had been covered with skin adhesive and mesh tape. The drains were removed when output was less than 30cc in 24-hour

period; the mean of drain duration was  $6.7 \pm 1.1$  days. All patients ambulated on the first post-operative day and were discharged home on the second one, except for two patient who were discharged home on the third post-operative day. Most patients could return to work after 4 weeks; from this time upper body activities were allowed. Compression garments were worn for 8 weeks postoperatively day and night, and from that moment on, an adequate rehabilitation program was permitted.

### Statistical analysis

Statistical analysis was performed using SPSS Statistics software package version 25 (IBM Corp. SPSS Statistics for Windows, NY, USA) with the aim to investigate any potential risk factors for development of complication. Data were provided as mean  $\pm$  standard deviation (SD). The values for categorical variables were analyzed by the Fisher's exact test; the values for quantitative variables were analyzed by the two-tail Mann-Whitney test.  $P$ -value  $< 0.05$  was considered statistically significant.

### Results

Fourteen helix thigh lift procedures were performed in 14 post bariatric female patients. The average age was  $42 \pm 4.8$  years and the average body mass index of  $27.9 \pm 0.8$  kg/m<sup>2</sup>. The helix thigh lift was combined with a lower body lift in all cases. The mean operative time was  $243 \pm 16$  minutes. The data are summarized in Table 1.

The incidence of deep venous thromboembolism, pulmonary embolism and revisional surgery due to a complication was zero. In our series, five patients (36%) experienced at least one complication related to the thigh lift. They were minor complications including four seromas (29%) treated with multiple percutaneous aspirations, one dehiscence (7%) and one hematoma (7%) treated in an outpatient setting, and one case of cellulitis (7%) that responded to oral antibiotics. No skin necrosis was reported. Four patients (29%) required surgical revision for scar irregularity; they were all minor revisions performed under local anesthesia, and advocated for esthetic purpose. We reported one case of transient edema (7%) that resolved within three months (Table 2). The mean follow-up time was  $14.8 \pm 3.2$  months.

The development of complications was significantly associated with patient's age ( $p = 0.0455$ ), but not with tobacco use, body mass index and operative time. See Table 3.

**Table 2.** Thigh lift complications.

Complications	Value (rate)
No. of patients with complications	5 (36%)
Thromboembolism	0
Revisional Surgery	0
Minor complications	
Seroma	4 (29%)
Dehiscence	1 (7%)
Hematoma	1 (7%)
Cellulitis	1 (7%)
Skin necrosis	0
Transient edema (< 3 months)	1 (7%)
Scar Revision	4 (29%)

**Table 3.** Statistical analysis - factors affecting complication development.

	Complication	No complication	$p$ -value
No. Patients	5	9	
Age	$45.4 \pm 4.4$	$40.1 \pm 4$	0.0455
Tobacco use	4	2	0.2774
Body mass index	$28.3 \pm 0.7$	$27.7 \pm 0.8$	0.6455
Operative time	$248 \pm 14.4$	$240.6 \pm 16.7$	0.3523

The values for quantitative variables are mean  $\pm$  SD.

**Table 4.** Outcomes evaluation.

	Patients	Equipe	Independent surgeon	Mean
Satisfaction with thighs	$8.3 \pm 0.8$	$8.5 \pm 0.7$	$8.3 \pm 0.5$	$8.4 \pm 0.7$
Satisfaction with hips and buttocks	$8.6 \pm 0.9$	$8.9 \pm 1$	$8.6 \pm 0.6$	$8.7 \pm 0.9$
Scar visibility	$8 \pm 0.8$	$7.7 \pm 0.5$	$7.2 \pm 0.6$	$7.6 \pm 0.7$
Scar quality	$7.3 \pm 0.7$	$7.6 \pm 0.5$	$7.2 \pm 0.9$	$7.4 \pm 0.7$
Overall satisfaction	$9.1 \pm 0.8$	$8.6 \pm 0.6$	$8.1 \pm 0.6$	$8.6 \pm 0.8$

Results from the questionnaire are listed in Table 4. Scar visibility and scar quality domains showed the lowest average score, as expected; anyway, the overall satisfaction was not dramatically affected because the reconstructive purpose of this technique was crystal clear for both patients and surgeons. The global result was satisfying or very satisfying for both the patients and the professionals.

### Discussion

Massive weight loss (MWL) patients can show a broad range of lower extremity deformities that negatively affect the quality of life [13, 14]. The thigh is one of the most demanding areas to address because of the heterogenous severity, quality and location of skin and adipose tissue excess, as well as functional concerns and surgical risk factors. Many classification methods had been described; they aimed to simplify the evaluation and allow the surgeon to compare patient's results based on a standardized classification [8, 10, 15, 16].

If laxity and lipodystrophy is affecting the whole thigh, a full-length vertical thighplasty may be necessary, and among these techniques the T-scar has the strongest contouring potential. However, the greater contouring power must be weighed against the extent and visibility of the scars, the augmented risk of lymphatic rupture and the well-known issues of a T-point [17]. Capella and Matarasso [10] stated that 95 percent of dehiscences occurred at the intersection of the closure at the thigh perineal crease, and Gusenoff et al. [18] reported 68 patients undergoing full length T-scar vertical thigh lift with 74% overall complication rate. However, if the scar is placed far from thigh perineal crease and digestive and genito-urinary apparatus, as we depicted, it is less exposed to maceration and contamination. On the other hand, we believe that a conventional L- or T-shaped medial thighplasty could not address the *pancake stack deformity* and our patients' needs properly.

Anyway, the algorithm should be tailored to the patient's peculiar demands: Patient's discomfort and affliction of a

specific disease or deformity should be taken into account, and thereby improve upon surgical outcomes for a specific cohort [11, 19, 20]. Some authors did not narrowly focus on the medial thigh alone, but they advocated a different approach to thigh contouring with the aim to address the entire thigh as an esthetic unit. Sozer et al. [21] proposed a single spiral incision to reshape flanks, proximal thighs and buttocks in a population with pear-shaped body contour deformity. This technique comprised cutaneous resection of the posterior, medial, and anterior thigh along with resection and lift of the flanks and buttocks. However, their cohort did not undergo a massive weight loss. Kolker and Xipoleas [22] treated nine MWL patients combining a spiral lift with a full-length conventional thigh lift with the aim to address the entire thigh as an esthetic unit (circumferential thigh lift).

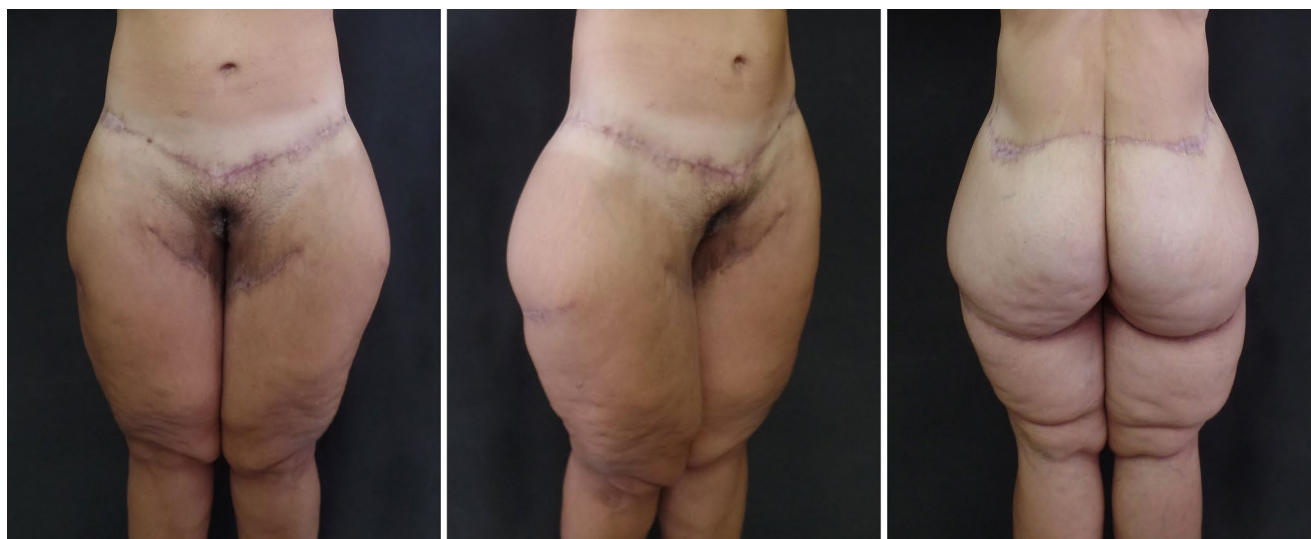
The *pancake stack deformity* (Figures 1 and 2) with its peculiar skin folds pattern, suggested us to make up something different. We abandoned the medial vertical excision (aimed to address the horizontal vector), and advocated a fold-targeted excision in respect of the Langer lines. The need to add a transverse component to a vertical medial thigh lift simultaneously or in a later stage is another example of tailored-surgery. A suprapatellar excision has already been described with the aim to treat a significant skin excess just above the knee [9, 23]. In our series, the transverse scar was not placed in an extension area, so any chance of functional impairment was unlikely. The helix thigh lift addressed a whole lipodystrophic saddlebag from medial to lateral side. The procedure resulted in two short visible scars on the medial and lateral aspect of the proximal thigh, but both were easily concealable wearing shorts. On the other hand, the patient recovered self-confidence, ease in clothing and ability to walk: The goal is to obtain a significant improvement in overall functioning and psychosocial health [24] (Figures 3).

A secondary advantage of this technique is an improvement of gluteal esthetics. When skin is removed from the

inner thigh and infragluteal area, it results in a sharper esthetic contour of the inferior buttock (Figures 2 and 3). However, in our series, the overall gluteal improvement due to the lower body lift procedure was non-negligible [25].

The surgical markings and consequent incision lines lay in the gluteal crease and middle transverse thigh fold. After the whole upper thigh saddlebag was excised, the wound edges were sutured under minimal tension, and no undermining was performed. A relevant force of gravity was acting on the sutures; anyway, we reported no wound breakdown, but just one minor dehiscence. We showed a significant rate of complications (36%), but they were all minor; furthermore, this data is consistent with previous literature describing an overall complication rate that can reach 74% for the well-established full-length vertical thigh lift [26, 27]. We found a significant relationship between the patient's age and the development of complications. This is consistent with the findings of Gusenoff et al. [18]; anyway, the literature is variable about the above-mentioned connection [26]. In our series the liposuction was performed just inside the resected area. It is likely that concomitant liposuction outside the area of resection has an increased rate of wound infection and breakdown. This finding may be attributable to tissue trauma with the liposuction cannulas, or residual edema that persists after surgery [18, 28].

Edema of the lower extremities should be documented preoperatively [29]. Recurrent lymphedema is an untoward issue, and its management is challenging [30–32]. In order to avoid any damage to the lymphatic system, we recommend a judicious liposuction of the marked resection area. The removal of fat from the soft tissues deep to the SFS eases the identification and preservation of nerves and vessels: The impairment of lymphatic flow is avoided, as evidenced in ex vivo studies [33, 34]. Furthermore, in our practice, the medial dissection is truly limited to a tapered tail in the upper third of the thigh; a conspicuous number of lymphatic collectors of the ventromedial bundle are saved from disruption [35].



**Figure 3.** Fifteen-month postoperative views show a significant body contour improvement of the posterior, medial and lateral thigh, along with the inferior buttocks. The combined lower body lift accounts for the improved ptosis of the mons and gluteal region along with an improvement of the flanks contour and the trochanteric area.

We recognize that this study is limited by the small sample size, and no control group is available with which to compare our patients. The helix thigh lift was designed for functional purposes such as relief of symptoms of severe intertriginous rash or impaired mobility and severe difficulty in proper dressing; it is definitely a reconstructive procedure. In these cases, the resulting contour should not be held up to stringent esthetic standards [16], and the patient is carefully advised about the best esthetic outcome we can offer.

The main limitation of this technique is the strict indication for severe gynoid contour deformity treatment. The wide fold-targeted skin resection is both strength and limitation: the strongest contouring potential has to be rated along with the scar visibility on the front and lateral side. Most massive weight loss patients will accept scar visibility for the functional and contour improvements resulting from greater resection. From posterior view, the scar lies in the gluteal fold, and it is visible on the front and lateral side, but easy concealable with a short dress. All patients were satisfied with the dramatic improvement of the contour. In our opinion the patient's overall satisfaction is higher than surgeons' (Table 4) because it takes into account also a functional improvement: The improved walking ability, ease in wearing clothes, and the relief against skin problems are not visible, but, also non negligible features of an increased self-confidence.

## Conclusion

The helix thigh lift was designed to obtain a tailored thigh contouring of severe gynoid deformities. The high satisfaction and the reasonable complication rate suggest that this is a safe and effective technique. The age of the patient was significantly associated to complication development. A dramatic improvement of ease in performing activities of daily living along with reduction of the skin problems leads to significant improvement of the quality of life. The thigh lift should be combined with a lower body lift to obtain the best contouring effect.

## Disclosure statement

No potential conflict of interest was reported by the author(s).

## Ethical approval

All procedures performed were in accordance with the 1964 Helsinki declaration and its later amendments or comparable ethical standards.

## List of supplemental digital content

### Supplementary Digital Content 1-Video

The preoperative markings and the intraoperative key steps are outlined by the Senior author.

## ORCID

Luigi Losco  <http://orcid.org/0000-0001-9105-1839>

Alessandro de Sire  <http://orcid.org/0000-0002-5541-8346>

## References

- Molero J, Moizé V, Flores L, De Hollanda A, Jiménez A, Vidal J. The impact of age on the prevalence of sarcopenic obesity in bariatric surgery candidates. *Obes Surg.* 2020;30(6):2158–2164. doi:10.1007/s11695-019-04198-4.
- de Sire A, Baricich A, Renò F, Cisari C, Fusco N, Invernizzi M. Myostatin as a potential biomarker to monitor sarcopenia in hip fracture patients undergoing a multidisciplinary rehabilitation and nutritional treatment: a preliminary study. *Aging Clin Exp Res.* 2020;32(5):959–962. doi:10.1007/s40520-019-01436-8.
- Invernizzi M, de Sire A, D'Andrea F, et al. Effects of essential amino acid supplementation and rehabilitation on functioning in hip fracture patients: a pilot randomized controlled trial. *Aging Clin Exp Res.* 2019;31(10):1517–1524. doi:10.1007/s40520-018-1090-y.
- Cuomo R, Russo F, Sisti A, et al. Abdominoplasty in mildly obese patients (BMI 30–35 kg/m<sup>2</sup>): metabolic, biochemical and complication analysis at one year. *In Vivo.* 2015;29:757–761.
- Cuomo R, Giardino FR, Nisi G, et al. Aspiration pneumonia: a shadow in post-bariatric patient: correlation between aspiration and minigastric bypass. *Obes Surg.* 2019;29(12):3937–3940. doi:10.1007/s11695-019-04081-2.
- Chandawarkar RY. Body contouring following massive weight loss resulting from bariatric surgery. *Adv Psychosom Med.* 2006;27:61–72. doi:10.1159/000090964.
- Sisti A, Cuomo R, Milonia L, et al. Complications associated with brachioplasty: a literature review. *Acta Biomed.* 2018;88(4):393–402. doi:10.23750/abm.v88i4.5609.
- Lockwood TE. Fascial anchoring technique in medial thigh lifts. *Plast Reconstr Surg.* 1988;82(2):299–304. doi:10.1097/00006534-198808000-00015.
- Mathes DW, Kenkel JM. Current concepts in medial thighplasty. *Clin Plast Surg.* 2008;35(1):151–163. doi:10.1016/j.cps.2007.09.003.
- Capella JF, Matarasso A. Management of the postbariatric medial thigh deformity. *Plast Reconstr Surg.* 2016;137(5):1434–1446. doi:10.1097/PRS.0000000000002134.
- Garcia JA, Driscoll DN, Donelan MB. Pursestring thigh lift: direct approach for a problematic deformity. *Ann Plast Surg.* 2006;57(3):330–332. doi:10.1097/01.sap.0000216261.41085.29.
- Losco L, Roxo AC, Roxo CW, et al. Lower body lift after bariatric surgery: 323 consecutive cases over 10-year experience. *Aesthetic Plast Surg.* 2020;44(2):421–432. doi:10.1007/s00266-019-01543-x.
- Sarwer DB, Polonsky HM. Body image and body contouring procedures. *Aesthet Surg J.* 2016;36(9):1039–1047. doi:10.1093/asj/sjw127.
- Roxo AC, Del Pino Roxo C, Marques RG, et al. Endocrine-metabolic response in patients undergoing multiple body contouring surgeries after massive weight loss. *Aesthet Surg J.* 2019;39(7):756–764. doi:10.1093/asj/sjy195.
- Armijo BS, Campbell CF, Rohrich RJ. Four-step medial thighplasty: refined and reproducible. *Plast Reconstr Surg.* 2014;134(5):717e–725e. doi:10.1097/PRS.0000000000000116.
- Song AY, Jean RD, Hurwitz DJ, Fernstrom MH, Scott JA, Rubin JP. A classification of contour deformities after bariatric weight loss: the Pittsburgh Rating Scale. *Plast Reconstr Surg.* 2005;116(5):1535–1544. doi:10.1097/01.prs.0000182606.92069.13.
- Bracaglia R, Tambasco D, Gentileschi S, D'Etto M. L-shaped lipohighplasty. *Ann Plast Surg.* 2015;75(3):261–265. doi:10.1097/SAP.0000000000000075.
- Gusenoff JA, Coon D, Nayar H, Kling RE, Rubin JP. Medial thigh lift in the massive weight loss population: outcomes and complications. *Plast Reconstr Surg.* 2015;135(1):98–106. doi:10.1097/PRS.0000000000000772.
- Losco L, Cigna E. Aesthetic refinements in C-V flap: raising a perfect cylinder. *Aesthet Surg J.* 2018;38(2):NP26–NP28. doi:10.1093/asj/sjx195.
- Losco L, Kaciulyte J, Delia G, et al. Back to basics with distal thumb reconstruction. Easy management of the incomplete am-

- putation. *J Invest Surg.* 2019;1–7. doi:10.1080/08941939.2019.1672840.
21. Sozer SO, Agullo FJ, Palladino H. Spiral lift: medial and lateral thigh lift with buttock lift and augmentation. *Aesthetic Plast Surg.* 2008;32(1):120–125. doi:10.1007/s00266-007-9036-3.
  22. Kolker AR, Xipoleas GD. The circumferential thigh lift and vertical extension circumferential thigh lift: maximizing aesthetics and safety in lower extremity contouring. *Ann Plast Surg.* 2011;66(5):452–456. doi:10.1097/SAP.0b013e3182145682.
  23. Capella JF. The vertical medial thigh lift. *Clin Plast Surg.* 2014;41(4):727–743. doi:10.1016/j.cps.2014.06.005.
  24. Modarressi A, Balagué N, Huber O, Chilcott M, Pittet- Cuénod B. Plastic surgery after gastric bypass improves longterm quality of life. *Obes Surg.* 2013;23(1):24–30. doi:10.1007/s11695-012-0735-8.
  25. Isakson MH, Vasilakis V, Kortesis BG, Hunstad JP, Bharti G. Avulsion fat graft gluteoplasty: technique overview. *Ann Plast Surg.* 2020;84(6S Suppl 5):S375–S381. doi:10.1097/SAP.0000000000002274.
  26. Bertheuil N, Thienot S, Huguier V, Menard C, Watier E. Medial thighplasty after massive weight loss: are there any risk factors for postoperative complications? *Aesthetic Plast Surg.* 2014;38(1):63–68. doi:10.1007/s00266-013-0245-7.
  27. Sisti A, Cuomo R, Zerini I, et al. Complications associated with medial thigh lift: a comprehensive literature review. *J Cutan Aesthet Surg.* 2015;8(4):191–197. doi:10.4103/0974-2077.172189.
  28. Bolletta A, Dessy LA, Fiorot L, et al. Sub-muscular breast augmentation using tumescent local anesthesia. *Aesthetic Plast Surg.* 2019;43(1):7–13. doi:10.1007/s00266-018-1181-3.
  29. Katzel EB, Nayar HS, Davenport MP, Bossert RP, Rubin JP, Gusenoff JA. The influence of preexisting lower extremity edema and venous stasis disease on body contouring outcomes. *Ann Plast Surg.* 2014;73(4):365–370. doi:10.1097/SAP.0b013e31827fb44c.
  30. Stadelmann WK. Intraoperative lymphatic mapping to treat groin lymphorrhea complicating an elective medial thigh lift. *Ann Plast Surg.* 2002;48(2):205–208. doi:10.1097/0000637-200202000-00017.
  31. Di Taranto G, Bolletta A, Chen SH, et al. A prospective study on combined lymphedema surgery: Gastroepiploic vascularized lymph nodes transfer and lymphaticovenous anastomosis followed by suction lipectomy. *Microsurgery.* 2021;41(1):34–43. doi:10.1002/micr.30641.
  32. de Sire A, Losco L, Cisari C, et al. Axillary web syndrome in women after breast cancer surgery referred to an Oncological Rehabilitation Unit: which are the main risk factors? A retrospective case-control study. *Eur Rev Med Pharmacol Sci.* 2020;24:8028–8035. doi:10.26355/eurrev\_202008\_22486.
  33. Frick A, Hoffmann JN, Baumeister RG, Putz R. Liposuction technique and lymphatic lesions in lower legs: anatomic study to reduce risks. *Plast Reconstr Surg.* 1999;103:1868–1873.
  34. Bulla A, Bolletta A, Fiorot L, et al. Posterior tibial perforators relationship with superficial nerves and veins: a cadaver study. *Microsurgery.* 2019;39(3):241–246. doi:10.1002/micr.30327.
  35. Tourani SS, Taylor GI, Ashton MW. Understanding the three-dimensional anatomy of the superficial lymphatics of the limbs. *Plast Reconstr Surg.* 2014;134(5):1065–1074. doi:10.1097/PRS.0000000000000640.