

HELMINTHOLOGIA, 55, 1: 77 - 83, 2018

Case Report

Filaroidosis infection in an immunocompetent adult dog from France

M. CERVONE^{1*}, A. GIANNELLI², D. ROSENBERG³, S. PERRUCCI⁴, D. OTRANTO²¹Small Animal Veterinary Clinic Paris III, Bl des Filles du Calvaire 75003 Paris, France, E-mail: mariocervone@live.it;²Department of Veterinary Medicine, University of Bari, Str. prov. per Casamassima km 3, 70010 Valenzano (Bari) Italy, E-mail: giannelli.alessio@gmail.com, domenico.otranto@uniba.it; ³Micen Vet Centre, 58 Rue Auguste Perret, Parc Technologique, Europarc, 9400 Créteil, France, E-mail: d.rosenberg@micen-vet.fr; ⁴Department of Veterinary Science, University of Pisa, Viale delle Piagge 2, 56124 Pisa, Italy, E-mail: stefania.perrucci@unipi.it

Article info

Received January 5, 2017
Accepted October 26, 2017

Summary

A dog from Paris (France) was referred with a 2-week history of dry cough, intermittent acute onset of dyspnoea, and acute abdominal pain. A generalised bronchoalveolar infiltrate with a patchy distribution was observed at chest x-rays and computed tomography (CT) scans. Negative results were obtained through several faecal examinations for cardiorespiratory nematodes by using the Baermann technique and at two blood analysis with a commercially available test for the detection of *A. vasorum* antigen (the first one at the first visit and second one at the control visit, one month later). PCR methods for the identification of *A. vasorum* and *C. vulpis* were also accomplished. At the control visit, nematode L1s were found during direct microscopic examination of bronchoalveolar lavage fluid (BALF). Thus, a different antigen-based assay for the detection of *A. vasorum* was performed with a positive result. Moreover, based on morphology, isolated larvae were identified as *Filaroides hirthei*. The dog was treated with fenbendazole (50 mg/kg per os once daily) for two consecutive weeks. After five months, the dog was referred again for the intermittent acute onset of dyspnoea and was found to be still positive for *F. hirthei* larvae at BALF examination. A 15-day treatment regimen with fenbendazole in combination with three subcutaneous injections of ivermectin (0.4 mg/kg, once every two weeks), was then performed. No larvae were detected at two BALF microscopical examinations performed one month apart. Results from this case report underline the importance of including *F. hirthei* infections in the differential diagnosis of dog bronchopneumonia.

Keywords: *Filaroides hirthei*; canine verminous bronchopneumonia; France

Introduction

Reports of nematodes parasitizing the respiratory tract of carnivores are increasingly common in Europe (Traversa *et al.*, 2010; Giannelli *et al.*, 2017) and these parasites can cause severe and occasionally fatal impairment (Traversa *et al.*, 2010). Of the nematode species affecting dogs, *Angiostrongylus vasorum* is the most common (Morgan & Shaw, 2010; Helm *et al.*, 2010), whereas *Crenosoma vulpis*, *Oslerus osleri* and *Filaroides hirthei* show more limited geographic distribution (Traversa *et al.*, 2010; Latrofa *et al.*,

2015). In particular, *Filaroides hirthei* has been sporadically documented in dogs from Germany (Bahnmann & Bauer, 1994), Great Britain (Spencer *et al.*, 1985), Australia (Beveridge *et al.*, 1983), Japan (Kagei *et al.*, 1976), United States (Rubash, 1986; Pinckney *et al.*, 1988), Ireland (Torgerson *et al.*, 1997), France (Bordeau & Ehm, 1992) and Spain (Caro-Vadillo *et al.*, 2005). Unlike other dog metastrongylid nematodes, *F. hirthei* has a direct life cycle. Puppies are infected through ingestion of first-stage larvae (L1s) passed by the faeces of chronically infected bitches (Georgi *et al.*, 1979). L1s rapidly make their way to the lungs via the he-

* – corresponding author

atic-portal or mesenteric lymphatic system and can survive within the mesenteric lymph nodes for extended periods, thus exposing the animal to auto-reinfection (Georgi *et al.*, 1979). Once in the respiratory apparatus, larvae moult into adults and within around five weeks, females shed larvae that can be detected in the faeces of the infected host (Bowman, 2000). Adults, causing severe bronchopneumonia, can remain hidden in lung parenchyma for long periods. Clinical disease outcome has most often been diagnosed in stressed young dogs, especially of toy breeds. However, severe clinical presentations can also be observed in immunocompetent and immunocompromised adults (Caro-Vadillo *et al.*, 2005; Conboy, 2009). Canine *F. hirshi* infection is usually marked by dry cough (Bowman, 2000) along with rapid breathing, dyspnoea, and exercise intolerance (Rubash, 1986; Andreasen & Carmichael, 1992; Bourdeau & Ehm, 1992). The diagnosis of the infection is based on direct detection of L1s in bronchoalveolar lavage or in the faeces (Pinckney *et al.*, 1988; McGarry & Morgan, 2009). However, due to intermittent faecal larval shedding and the occurrence of auto-reinfections, the diagnosis and treatment of canine *F. hirshi* infection remain challenging (Bauer & Bahnemann, 1996).

Case presentation

A seven-year old unsprayed female West Highland white terrier living in Paris (France) was admitted to the Small Animal Veterinary Clinic Paris III (Paris, France) for decreased appetite, acute abdominal pain, dry cough, and intermittent acute onset of dyspnoea. Previous history included cranium-mandibular osteopathy at

the age of 10 months, successfully treated with corticosteroids. The dog had been purchased at the age of three months in Ireland and since then had never travelled out of France. Physical examination revealed severe abdominal pain at the cranial abdominal region, tachypnoea (50 breaths/min) and bradycardia (60 bpm), associated with respiratory sinus arrhythmia. Thoracic auscultation disclosed pronounced bilateral wheezing and crackles, along with increased breathing sounds in trachea. A complete blood count showed moderate anaemia (Hgb 12.83 g/dl; reference interval 13.2 – 19.2), moderate leucocytosis ($13.7 \times 10^9/L$; reference interval 6 – 13) associated with eosinophilia ($2.4 \times 10^9/L$, reference interval 0.0 – 1.2) and thrombocytopenia ($20 \times 10^9/L$; reference interval 150 – 500). Blood smear examination highlighted the presence of giant platelets, while the coagulation profile was within the normal reference range. No biochemical abnormality was found at blood and urine analysis, and no abdominal malformations or abnormalities were recorded by either ultrasonography or abdominal computed tomography (CT). Chest x-rays revealed an extensive bronchoalveolar infiltrate with a patchy distribution (Fig. 1), what was also confirmed by CT (Fig. 2A). Echocardiography revealed no defects, while bronchoscopy showed tracheal and bronchial hemorrhagic areas associated with mucosal hyperaemia. Cytology of the broncho-alveolar lavage fluid (BALF) showed moderate cell density, characterised by high levels of eosinophils (56 %) and neutrophils (22 %) and few macrophages (22 %). On the basis of these findings, the main differential diagnoses included nematode, mycotic, allergic and inflammatory bronchopneumonia, as well as idiopathic pulmonary fibrosis, primary or

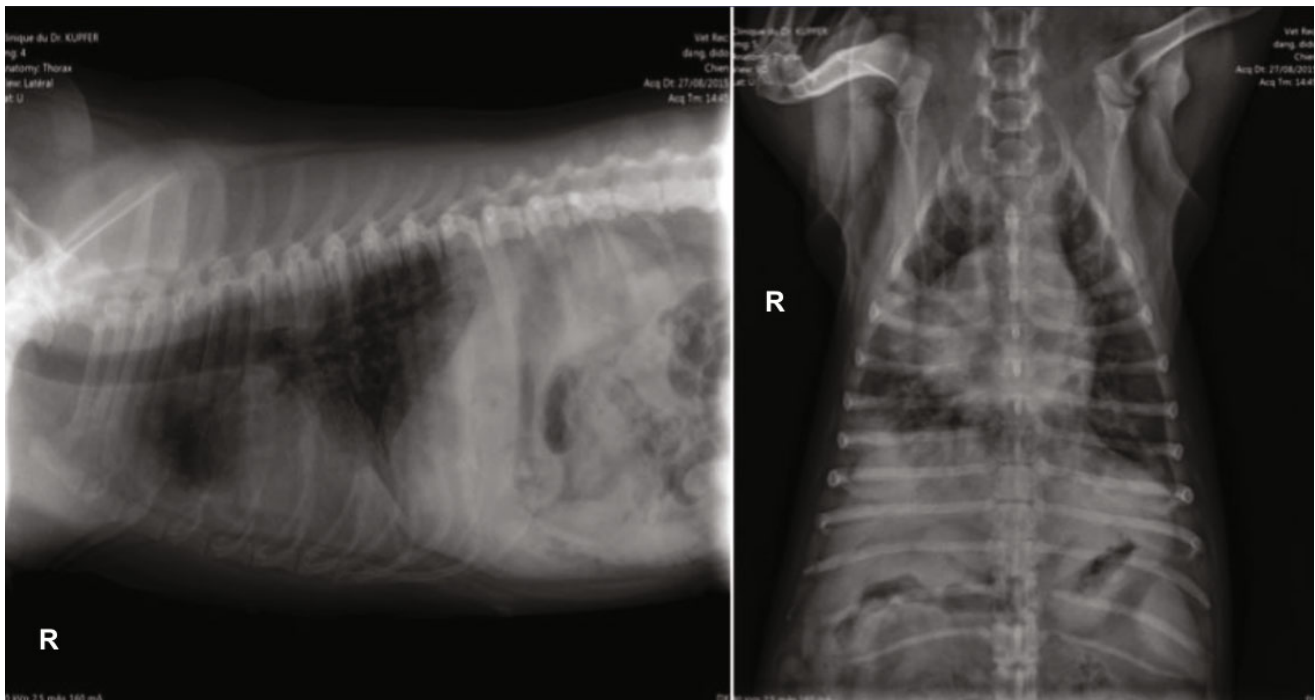


Fig. 1. Right lateral (on the left) and ventrodorsal (on the right) thoracic radiographs of the examined dog showing an extensive broncho-alveolar infiltrate and consolidated areas with a patchy distribution. Lesions are more severe in the right hemithorax.

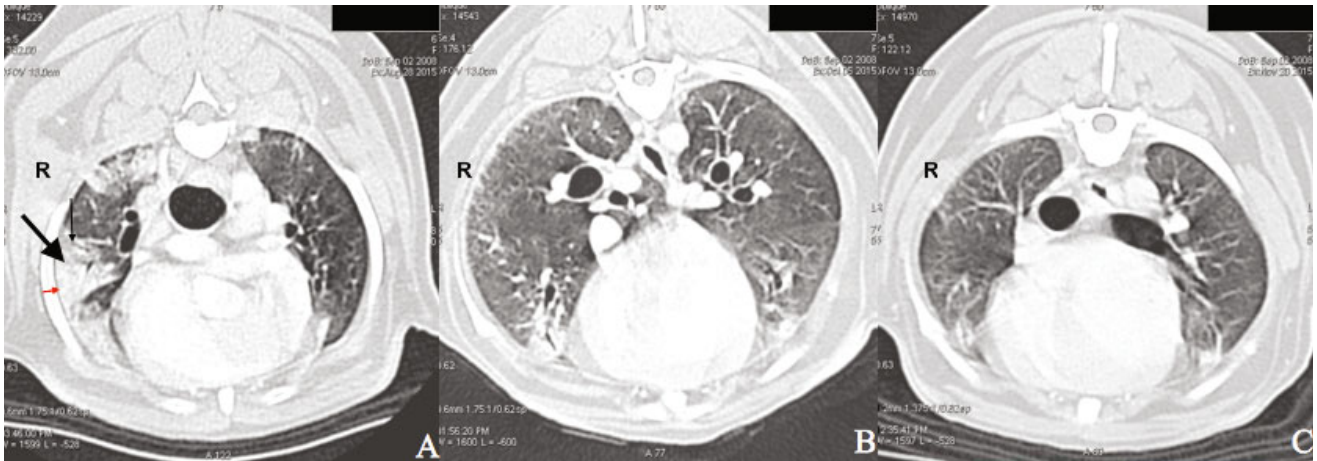


Fig. 2. Transverse computed tomographic images of the lungs of the dog. (A) Pulmonary lesions at clinical presentation, showing a large consolidated area (black thick arrow) with formation of air bronchograms (black thin arrow), surrounded by diffuse zones of ground-glass opacification (red thin arrow). Lesions are more severe in the right hemithorax (B) Moderate improvement in pulmonary lesions after few days of treatment. (C) Improvement in pulmonary lesions 15 days after starting treatment with oral fenbendazole. Consolidated areas have almost disappeared.

metastatic pulmonary neoplasia, granulomatous pneumonia and pulmonary granulomatosis. Parasitological analysis on faecal samples collected over three consecutive days and examined as fresh smears, by the Baermann technique and by flotation test using a low-density flotation solution (specific gravity 1.2), proved negative for parasites. Negative results were also obtained after blood analysis with a commercially available blood test (Angio Detect™, IDEXX, Westbrook, USA) for the detection of *A. vasorum* antigen and also after faecal samples analysis with PCR for the identification of *A. vasorum* and *C. vulpis* (performed by IDEXX Laboratories, France). Bacteriological examination of BALF revealed the presence of extra-cellular *Pseudomonas* species. Real-time PCR on BALF was negative for *Toxoplasma gondii* and *Pneumocystis carinii* (Biomnis laboratories, France). Idiopathic eosinophilic bronchopneumonia was suspected and the dog was treated with marbofloxacin (4 mg/kg/day, Marbocyl®; Vetoquinol S.A.) during 15 days and prednisolone (10 mg/kg/day, Dermipred®; Sogeval) during 30 days. Treatment resulted in moderate improvement in clinical condition and thoracic pulmonary lesions by CT examination (Fig. 2B) at control visit, performed one month later. In contrast, the BALF control cytological analysis, performed 30 days after the beginning of the treatment, revealed absolute neutrophilia (43 %) with normal eosinophilia (3 %) associated with a large number of nematode L1s found at direct microscopic examination of BALF. The suspicion that at the first visit the dog had an *A. vasorum* infection in the prepatent period, led us to repeat the antigen blood test (Angio Detect™, IDEXX, Westbrook, USA) and the Baermann test at the control visit. Both these tests were negative for a second time. Therefore, a different antigen-based assay (Schnyder *et al.*, 2011) with a positive result for the detection of *A. vasorum* was performed. Additionally, based on morphology and dimensions according to previously reported data (McGarry & Morgan, 2009) the L1s found in BALF were mi-

croscopically identified at the species level. The collected L1s measured $265 \pm 13 \mu\text{m}$ and were characterised by a straight tail with a single slight dorsal indentation, ending in a lance-like shape (Fig. 3). Larvae isolated from faecal samples and BALF were also subjected to molecular identification using primers targeting partial 12S and 18S rRNA genes (Fila_12SF: 5'-CGGGAGTAAAGT-TTTGTTTAAACCG-3' and Fila_12SR: 5'-CATTGACGGATGGT-TTGTACCAC-3'; NC18SF1: 5'-AAAGATTAAGCCATGCA-3' and NC5BR: 5'-GCAGGTTACCTACAGAT-3', respectively) and run PCR protocol described elsewhere (Latrofa *et al.*, 2015). Although both genes offer useful insights into the identification of various nematode species (Hu *et al.*, 2004; Petterson-Kane *et al.*, 2009; Brianti *et al.*, 2012), the amplification turned out unsuccessful likely due to the contamination by bacterial and fungal DNA (Jefferies *et al.*, 2010). However, based on the morphological features of the larvae and clinical signs a diagnosis of *F. hirthei* infection was confirmed and the dog was treated with oral fenbendazole once daily (50 mg/kg; Panacur™, MSD Animal Health Srl, France) for two consecutive weeks (Rubash, 1986). Fifteen days after the start of the treatment, the owner reported improvement in respiratory signs, and repeated BALF cytological analysis showed blood cell characteristics (neutrophils 22 %, eosinophils 0 %, macrophages 73 % associated with haemosiderophages) and confirmed the absence of L1s at direct microscopic examination. Thoracic CT showed excellent improvement of the pulmonary lesions (Fig. 2C). Based on its efficacy against the immature stages and the reduction of infection levels of other cardio-respiratory nematodes, milbemycin oxime (at 0.75 mg/kg, Trifexis®, Elanco Animal Health) was then administered once monthly *per os* to prevent reinfections and auto-reinfections (Conboy *et al.*, 2013a; Böhm *et al.*, 2014; Lebon *et al.*, 2016).

Five months later, the dog was referred again for the intermittent acute onset of dyspnoea. Chest CT showed a relapse of alveolar

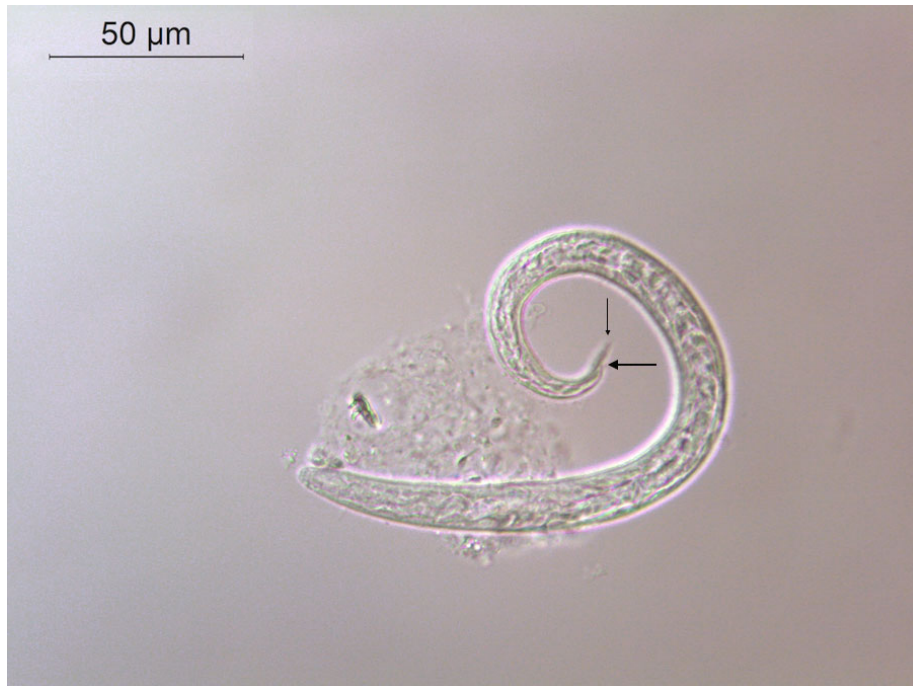

Fig. 3. *Filaroides hirthi* first stage larva detected at the microscopic examination of the BALF (40x magnification). Note the straight tail with a single slight dorsal indentation (thick arrow), ending into a lance-like shape (thin arrow), consistent with *F. hirthi*.

opacities with patchy distribution, and direct microscopic examination of BALF revealed once more the presence of live *F. hirthi* L1s. Thus, fenbendazole treatment (50 mg/kg per os for two weeks) combined with three subcutaneous off-label administrations of ivermectin (0.4 mg/kg, once every two weeks; Ivomec®; Merial), were performed. One month later, the thoracic CT showed normal lung patterns, and no larvae were detected at two BALF microscopic examinations performed one month apart.

Discussion

The genus *Filaroides* includes ovoviviparous nematodes that localise in the respiratory system of dogs and wild canids. Dog infections with *Filaroides* species are considered relatively uncommon, possibly because many infected dogs are clinically asymptomatic (Caro-Vadillo et al., 2005; Caswell and Williams, 2007). Indeed, clinical diseases caused by *F. hirthi* have been generally associated with immunocompromised, stressed or young dogs (Caro-Vadillo et al., 2005). Since the literature contains only case reports, the prevalence of *F. hirthi* infection in Europe and in other geographical areas is unknown (Bauer & Bahnmann, 1996; Caro-Vadillo et al., 2005). Besides other than the frequent chronic and sub-clinical infections, this could be due to diagnostic difficulties resulting from the intermittent shedding of *F. hirthi* larvae in the faeces of infected animals. This is probably also caused by wrong identification of *F. hirthi* larvae that can be confused with the most common *A. vasorum* species. Since the larvae of *Filaroides* spp.

larvae are lethargic and therefore do not migrate out of the faeces easily (Traversa et al., 2010) their detection in faecal samples examined by the Baermann method may be unlikely. However, the geographical distribution of *F. hirthi* could be truly limited, resulting in sporadic infections throughout the world. In the dog examined herein, *F. hirthi* L1s were identified at BALF microscopic examination. Based on their significantly smaller size and on their tails showing a notch followed by a constriction and a terminal lance-like end, without any kink, undulation or spine, isolated larvae were distinguished from those of *A. vasorum* showing a prominent dorsal spine and a double cuticle indentation at the caudal end (McGarry & Morgan, 2009; Traversa et al., 2010; Taylor et al., 2007). The different morphology of the caudal end also allowed their differentiation from L1s of *C. vulpis*, showing a straight and uniformly pointed tail (McGarry & Morgan, 2009; Traversa et al., 2010). The L1s of *F. hirthi*, *Filaroides milksi* and *Oslerus (Filaroides) osleri* are morphological identical and cannot be differentiated from each other (Traversa et al., 2010; Conboy, 2009). However, in the dog examined, characteristic *O. osleri* tracheobronchial nodules were not evidenced by bronchoscopy. On the other hand, dog *F. milksi* infection has been rarely reported in Europe (Cremers et al., 1978). Moreover, the validity of *F. milksi* and *F. hirthi* as two separate species has been questioned (Conboy, 2009).

Canine *F. hirthi* infection is often subclinical in healthy and immunocompetent dogs. Nevertheless fatal respiratory disease outcome has been reported after corticosteroid treatments or because of other immunosuppressive conditions, including chronic stress,

generalized demodicosis or adrenal cortical carcinoma (Bauer & Bahnemann, 1996). In aged dogs, the infection can begin as non-productive cough, sometimes associated with poor general condition and acute or progressive dyspnoea or tachypnoea (Bowman, 2000; Torgerson *et al.*, 1997).

Similarly to *A. vasorum* infection (Martin *et al.*, 1993), the abdominal pain observed in the dog herein examined could be related to L1s migration through the mesenteric lymph nodes, liver or kidney or as a result of pleural or diaphragmatic inflammation. Moreover, a mixed pulmonary pattern affecting all the lung lobes, mainly characterized by bronchiolitis, peribronchitis and perivasculitis, focal or interstitial pneumonia, granulomatous lesions and pleural fibrosis with a predominance of interstitial and alveolar infiltration, is the most common radiographic finding for *F. hirthei* infections (Bowman, 2000). As described in the case here reported, free larvae in the alveolar lumen may induce an inflammatory reaction characterized by numerous neutrophilic granulocytes, while eosinophilia can be observed in peripheral blood (Bahnemann & Bauer, 1994). Negative faecal examinations results do not exclude infection by *Filaroides* species (Caro-Vadillo *et al.*, 2005), where bronchial or tracheal washing are more reliable than coprology in the detection of L1s (Brownlie, 1990). Thus, *F. hirthei* larvae are detected most accurately by the examination of bronchial mucus (Conboy, 2009). In the present case, the Baermann method was used in association with BALF direct microscopic examination, as well as serological and molecular detection methods in order to rule out *A. vasorum* and *C. vulpis* infection.

The prevalence of *A. vasorum* is high in France and this cardio-respiratory nematode should be always considered in the differential diagnosis of dog bronchopneumonia. Although for the positive commercial *A. vasorum* sandwich-ELISA used herein a specificity of 94 % has been reported (Verzberger-Epshtein *et al.*, 2008; Schnyder *et al.*, 2011), a possible cross-reactivity with *F. hirthei* has not previously been assessed. Based on the results obtained, the cross-reactivity of this immunological *A. vasorum* diagnostic test with *F. hirthei* should not be ruled out. Since this test can reveal the presence of *A. vasorum* antigens until 34 days after the treatment and it is always positive in dogs harbouring only one worm (Schnyder *et al.*, 2011) the occurrence of a previous *A. vasorum* infection in dog examined in this study cannot be excluded. Considering the high prevalence of *A. vasorum* infection in France and in other European countries (Lebon *et al.*, 2016; Lempereur *et al.*, 2016; Traversa & Guglielmini, 2008), great attention is thus required for interpretation of results and diagnostic procedures.

For the treatment of dog *Filaroides* infections, the effective use of fenbendazole (50 mg/kg oral once a day for 10 to 14 days), albendazole (25 to 50 mg/kg twice a day for five consecutive days repeated two weeks later), and single administration of injectable ivermectin at 0.4 – 1 mg/kg, has been reported in previous studies (Bauer & Bahnemann, 1996; Bowman, 2000; Caro-Vadillo *et al.*, 2005). The treatment of *F. hirthei* is particularly challenging because this parasite does not require an intermediate host for

its development, and reinfections and auto-reinfections frequently occur (Georgi *et al.*, 1979; Torgerson *et al.*, 1997). This was the main reason why milbemycin oxime and ivermectin treatments were performed in this case report. However, the treatment with oral milbemycin oxime was unsuccessful from preventing the *F. hirthei* infection. The efficacy of milbemycin oxime for the prevention of *A. vasorum* and the reduction of *A. vasorum* and *C. vulpis* infection levels, have been evidenced (Conboy *et al.*, 2013; Böhm *et al.*, 2014; Lebon *et al.*, 2016). However, dosing intervals for the treatment of infections and the prevention in clinical disease have not yet been established (Conboy *et al.*, 2013a). Moreover, for the effective treatment of other respiratory nematodes, as *E. boehmi* infection, milbemycin oxime should be used at the increased dose of 2 mg/kg (Conboy *et al.*, 2013b; Cervone *et al.*, 2017). All these factors might represent possible reasons for the failure of milbemycin oxime in the case study reported here. Though moxidectin larvicidal and adulticidal activity against *A. vasorum* in dogs has been demonstrated (Willesen *et al.*, 2007; Schnyder *et al.*, 2009), in France moxidectin is available only as a topic spot-on formulation for its use in companion animals. Since the patient examined here had previously showed a cutaneous reaction to spot-on formulations, the prophylactic use of oral milbemycin oxime was preferred to moxidectin in this case report. Although the use of ivermectin should be discouraged in canine medicine, unless mandatory due to the lack of other efficacious drugs, injectable ivermectin was preferred in this study because of previous reports on its effectiveness for the treatment of *F. hirthei* in dogs (Erb & Georgi, 1982; Pinckney *et al.*, 1988; Bauer & Bahnemann, 1996).

Based on the resolution of respiratory signs and the absence of L1s at two BALF microscopical examinations performed one month apart following the combined fenbendazole and ivermectin treatment, it can be assumed that the dog from the case here presented was healed from *F. hirthei* infection. However, due to lack of follow-up of the dog examined in this case report, further reinfections after this combined treatment cannot be ruled out.

In conclusion, results from this study underline the importance of including *F. hirthei* infections in the differential diagnosis of dog bronchopneumonia.

References

- ANDREASEN, C.B., CARMICHAEL, P. (1992): What is your diagnosis? *Filaroides hirthei* infection in a dog. *Vet. Clin. Pathol.*, 21: 77 – 78. DOI: 10.1111/j.1939-165X.1992.tb00587.x
- BAHNEMANN, R., BAUER, C. (1994): Lungworm infection in a beagle colony: *Filaroides hirthei*, a common but not well-known companion. *Exp. Toxicol. Pathol.*, 46: 55 – 62. DOI: 10.1016/S0940-2993(11)80017-5
- BAUER, C., BAHNEMANN, R. (1996): Control of *Filaroides hirthei* infections in beagle dogs by ivermectin. *Vet. Parasitol.*, 65: 269 – 273. DOI: 10.1016/S0304-4017(96)00976-4

- BEVERIDGE, I., DUNSMORE, J.D., HARRIGAN, K.E., RICHARD, M.D. (1983): *Filaroides hirthei* in dogs. *Aust. Vet. J.*, 60: 59. DOI: 10.1111/j.1751-0813.1983.tb05865.x
- BOHM, C., SCHNYDER, M., THAMSBORG, S.M., THOMPSON, C.M., TROUT, C., WOLKEN, S., SCHNITZLER, B. (2014): Assessment of the combination of spinosad and milbemycin oxime in preventing the development of canine *Angiostrongylus vasorum* infections. *Vet. Parasitol.*, 199: 272 – 277. DOI: 10.1016/j.vetpar.2013.10.024
- BOURDEAU, P., EHM, J.P. (1992): Cas original de filaridose due a *Filaroides* sp. chez le chien. Données actuelles sur la filaridose a *Filaroides hirthei* Georgi et Anderson 1975 [Original case of filaroidosis due to *Filaroides* sp. in dogs. Update on *Filaroides hirthei* Georgi and Anderson 1975 filaroidosis]. *Rec. Med. Vet.*, 168: 315 – 321 (In French)
- BOWMAN, D.D. (2000): Respiratory System Parasites of the Dog and Cat (Part I): Nasal Mucosa and Sinuses, and Respiratory Parenchyma. In: BOWMAN, D.D. (Ed) *Companion and exotic animal parasitology*. Ithaca, NY: IVIS (www.ivis.org)
- BRIANTI, E., GAGLIO, G., GIANNETTO, S., ANNOSCIA, G., LATROFA, M.S., DANTAS-TORRES, F., TRAVERSA, D., OTRANTO, D. (2012): *Troglostrongylus brevior* and *Troglostrongylus subcrenatus* (Strongylida: Crenosomatidae) as agents of broncho-pulmonary infestation in domestic cats. *Parasit. Vectors.*, 5: 178. DOI: 10.1186/1756-3305-5-178
- BROWNLIE, S.E. (1990): A retrospective study of diagnosis in 109 cases of canine lower respiratory disease. *J. Small Anim. Pract.*, 31: 371 – 376. DOI: 10.1111/j.1748-5827.1990.tb00482.x
- CERVONE, M., MESSINA, N., PERRUCCI, S. (2017). Nasal capillariosis due to *Eucoleus boehmi* in two naturally infected dogs. *Rev. Vet. Clin.*, 52: 41 – 45. DOI: 10.1016/j.anicom.2017.04.001
- CARO-VADILLO, A., MARTINEZ-MERLO, E., GARCIA-REAL, I., FERMIN-RODRIGUEZ, M.L., MATEO, P. (2005): Verminous pneumonia due to *Filaroides hirthei* in a Scottish terrier in Spain. *Vet. Rec.*, 157: 586 – 589. DOI: 10.1136/vr.157.19.586
- CONBOY, G. (2009): Helminth Parasites of the Canine and Feline Respiratory Tract. *Vet. Clin. Small Anim.*, 39: 1109 – 1126. DOI: 10.1016/j.cvsm.2009.06.006
- CONBOY, G., BOURQUE, A., MILLER, L., SEEWALD, W., SCHENKER, R. (2013a): Efficacy of Milbemax (milbemycin oxime + praziquantel) in the treatment of dogs experimentally infected with *Crenosoma vulpis*. *Vet. Parasitol.*, 198: 319 – 324. DOI: 10.1016/j.vetpar.2013.09.016
- CONBOY, G., STEWART, T., O'BRIEN, S. (2013b): Treatment of *E. boehmi* infection in a mixed breed dog using milbemycin oxime. *J. Am. Anim. Hosp. Assoc.*, 49: 204 – 209. DOI: 10.5326/JAAHA-MS-5832
- CREMERS, H.J., GRUYS, E., STOKHOF, A.A. (1978): An infection with the lungworm *Filaroides milksi* Whitlock, 1956 (Nematoda: Metastrongyloidea) in a dog from Belgium. *Tijdschr. Diergeneesk.*, 103: 85 – 90
- ERB, H.N., GEORGI, J.R. (1982): Control of *Filaroides hirthei* in commercially reared beagle dogs. *Lab. Anim. Sci.*, 32: 394 – 396
- GEORGI, J.R., GAHNSTOCK, G.R., BOHM, M.F.K., ADSIT, J.C. (1979): The migration and development of *Filaroides hirthei* larvae in dogs. *Parasitology*, 79: 39 – 47. DOI: 10.1017/S0031182000051969
- GIANNELLI, A., CAPELLI, G., JOACHIM, A., HINNEY, B., LOSSON, B., KIRKOVA, Z., RENÉ-MARTELLET, M., PAPADOPOULOS, E., FARKAS, R., NAPOLI, E., BRIANTI, E., TAMPONI, C., VARCASIA, A., MARGARIDA ALHO, A., MADEIRA DE CARVALHO, L., CARDOSO, L., MAIA, C., MIRCEAN, V., MIHALCA, A.D., MIRÓ, G., SCHNYDER, M., CANTACESSI, C., COLELLA, V., CAVALERA, M.A., LATROFA, M.S., ANNOSCIA, G., KNAUS, M., HALOS, L., BEUGNET, F., OTRANTO, D. (2017): Lungworms and gastrointestinal parasites of domestic cats: a European perspective. *Int. J. Parasitol.*, 47(9): 517 – 528. DOI: 10.1016/j.ijpara.2017.02.003
- HELM, J.R., MORGAN, E.R., JACKSON, M.W., WOTTON P., BELL R. (2010): Canine angiostrongylosis: an emerging disease in Europe. *J. Vet. Emerg. Crit. Care*, 20: 98 – 109. DOI: 10.1111/j.1476-4431.2009.00494.x
- HU, M., CHILTON, N.B., GASSER, R.B. (2003): The mitochondrial genomics of parasitic nematodes of socio-economic importance: recent progress, and implications for population genetics and systematics. *Adv. Parasitol.*, 56: 133 – 212. DOI: 10.1016/S0065-308X(03)56003-1
- JEFFERIES, R., SHAW, S.E., WILLESSEN, J., VINEY, M.E., MORGAN, E.R. (2010): Elucidating the spread of the emerging canid nematode *Angiostrongylus vasorum* between Palaearctic and Nearctic ecozones. *Infect. Genet. Evol.*, 10(4): 561 – 568. DOI: 10.1016/j.meegid.2010.01.013
- KAGEI, M., KHIATA, M., HORIUCHI, T., SUZUCHI, M. (1976): Problems on the parasitic infections of the imported beagle dogs. *Bull. Inst. Public Health*, 25: 140 – 144
- LATROFA, M.S., LIA, R.P., GIANNELLI, A., COLELLA, V., SANTORO, M., D'ALESSIO, N., CAMPBELL, B.E., PARISI, A., DANTAS-TORRES, F., MUTAFCHIEV, Y., VENEZIANO, V., OTRANTO, D. (2015): *Crenosoma vulpis* in wild and domestic carnivores from Italy: a morphological and molecular study. *Parasitol. Res.*, 114: 3611 – 3617. DOI: 10.1007/s00436-015-4583-z
- LEBON, W., TIELEMANS, E., REHBEIN, S., DUMONT, P., YOON, S., BEUGNET, F., JEANNIN, P., LARSEN, D., HALOS, L. (2016): Monthly administrations of milbemycin oxime plus afoxolaner chewable tablets to prevent *Angiostrongylus vasorum* infection in dogs. *Parasit. Vectors*, 9(1): 485. DOI: 10.1186/s13071-016-1773-1
- LEMPEREUR, L., MARTINELLE, L., MARECHAL, F., BAYROU, C., DALEMANS, A.C., SCHNYDER, M., LOSSON, B. (2016): Prevalence of *Angiostrongylus vasorum* in southern Belgium, a coprological and serological survey. *Parasit. Vectors*, 9(1): 533. DOI: 10.1186/s13071-016-1820-y
- MARTIN, M.W.S., ASHTON, G., SIMPSON, V.R., NEAL, C. (1993): Angiostrongylosis in Cornwall: Clinical presentations of eight cases. *J. Small Anim. Pract.*, 34: 20 – 25. DOI: 10.1111/j.1748-5827.1993.tb02570.x
- MCGARRY, J.W., MORGAN, E.R. (2009): Identification of first-stage larvae of metastrongyles from dogs. *Vet. Rec.*, 165: 258 – 261. DOI: 10.1136/vr.165.9.258

- MORGAN, E., SHAW, S. (2010): *Angiostrongylus vasorum* infection in dogs: continuing spread and developments in diagnosis and treatment. *J. Small Anim. Pract.* 51(12): 616 – 621. DOI: 10.1111/j.1748-5827.2010.01000.x
- PATTERSON-KANE, J.C., GIBBONS, L.M., JEFFERIES, R., MORGAN, E.R., WENZLOW, N., REDROBE, S.P. (2009): Pneumonia from *Angiostrongylus vasorum* infection in a red panda (*Ailurus fulgens fulgens*). *J. Vet. Diagn. Invest.*, 21: 270 – 273. DOI: 10.1177/104063870902100219
- PINCKNEY, R.D., STUDER, A.D., GENTA, R.M. (1988): *Filaroides hirthi* infection in two related dogs. *J. Am. Vet. Med. Assoc.*, 193: 1287 – 1288
- RUBASH, J.M. (1986): *Filaroides hirthi* infection in a dog. *J. Am. Vet. Med. Assoc.*, 189: 213
- SCHNYDER, M., FAHRION, A., OSSENT, P., KOHLER, L., WEBSTER, P., HEINE, J., DEPLAZES, P., (2009): Larvicidal effect of imidacloprid/moxidectin spot-on solution in dogs experimentally inoculated with *Angiostrongylus vasorum*. *Vet. Parasitol.*, 166: 326 – 332. DOI: 10.1016/j.vetpar.2009.09.004
- SCHNYDER, M., TANNER, I., WEBSTER, P., BARUTZKI, D., DEPLAZES, P. (2011): An ELISA for sensitive and specific detection of circulating antigen of *Angiostrongylus vasorum* in serum samples of naturally and experimentally infected dogs. *Vet. Parasitol.*, 179(1 – 3): 152 – 158. DOI: 10.1016/j.vetpar.2011.01.054
- SPENCER, A., RUSHTON, B., MUNRO, H. (1985): *Filaroides hirthi* in a British-bred beagle dog. *Vet. Rec.*, 117: 8 – 10. DOI: 10.1136/vr.117.1.8
- TORGERSON, P. R., MCCARTHY, G., DONNELLY, W. J. (1997): *Filaroides hirthi* verminous pneumonia in a West Highland White Terrier bred in Ireland. *J. Small Anim. Pract.*, 38: 217 – 219. DOI: 10.1111/j.1748-5827.1997.tb03347.x
- TRAVERSA, D., DI CESARE, A., CONBOY, G. (2010): Canine and feline cardiopulmonary parasitic nematodes in Europe: emerging and underestimated. *Parasit. Vectors*, 3: 62. DOI: 10.1186/1756-3305-3-62
- TRAVERSA, D., GUGLIELMINI, C. (2008): Feline aelurostrongylosis and canine angiostrongylosis: A challenging diagnosis for two emerging verminous pneumonia infections. *Vet. Parasitol.*, 157: 163 – 174. DOI: 10.1016/j.vetpar.2008.07.020
- VERZBERGER-EPSTEIN, I., MARKHAM, R.J.F., SHEPPARD, J.A., STRYHN, H., WHITNEY, H., CONBOY, G.A. (2008): Serologic detection of *Angiostrongylus vasorum* infection in dogs. *Vet. Parasitol.*, 151: 53 – 60. DOI: 10.1016/j.vetpar.2007.09.028
- WILLESEN, J.L., KRISTENSEN, A.T., JENSEN, A.L., HEINE, J., KOCH, J. (2007): Efficacy and safety of imidacloprid/moxidectin spot-on solution and fenbendazole in the treatment of dogs naturally infected with *Angiostrongylus vasorum* (Baillet, 1866). *Vet. Parasitol.*, 147(3 – 4): 258 – 264. DOI: 10.1016/j.vetpar.2007.05.001